OSLER LIBRARY
McINTYRE MEDICAL SCIENCES BUILDING
McGILL UNIVERSITY, MONTREAL 109, CANADA

4 may 1976

On april 30/76 – in conversation with Dr. Abu Bacarri who had asked me, "Who was Osler" I answered the question incompletely in the next half hour. Before leaving I suggested that Dr. B. who had not yet seen a copy of Osler's "The Practice of Medicine" – 4 Editions read an early edition. Indeed I undertook to lend him my copy of the 1893 printing of the first edition.

On may 2nd I took this volume off the bookshelf in my Study and for the first time in more than 30 years (I bought it in about 1931 at a second hand book store on Bleury St.) I turned its pages and lo and behold I found this page with Osler's characteristic hand writing.

To day Marilyn established that it belongs between #CCCI and #CCCII of the autopsy reports in Volume III.

Harold McDougall

14/4/79.

CCCII Primary Cancer of Liver

– Harrigan aet. 54. temperate man, of spare habit – patient of Dr Oakes. Had suffered for a couple of years from dyspeptic symptoms. Not laid up until 8 weeks ago – Symptoms chiefly pain – enlargement of liver gastric disturbance & wasting. Slight ascites within the past week and within 3–4 days of death, jaundice. Skin & itchy

Body considerably emaciated. skin moderately jaundiced. Liver could be felt as a firm hard structure for nearly a hand-breadth below the costal margin. On opening abdomen nothing observable of note beyond the enlargement of the liver. about two pints of clear – bile tinged fluid in peritoneum.

In thorax, some effusion in right pleura – about a quart – a few adhesions on left side. Heart small, flabby, contains small quantity of blood, valves normal. Apex of right lung contains one small cavity size of marble filled with purulent matter another about same size filled with cheesy substance. The tissue about, somewhat indurated, pleura thickened. In the contiguous tissue are scattered 20–30 grey granulations firm, hard & translucent. Rest of lung crepitant & natural. Left apex also a little indurated, and contains a small cheesy mass & a few tubercles. rest of lung normal.

Spleen small, capsule opaque substance normal.

Kidneys of normal size, right somewhat displaced & flattened against the liver. Pancreas healthy. Nothing abnormal in large or small bowels. Bladder healthy.

Stomach duodenum & liver secured together. The latter has several firm old bands between capsule and diaphragm, & some fresh ones

towards the sides. Stomach large, contains a quantity of dark sup.-like material. M. M. much mammillated, esp. at the pylorus, but more or less over the entire organ except at the cardia. The mammillæ are very prominent, & the fissures between them distinct. To the naid the membrane has a little extra resistance. The capillaries in & at the an injected often in the tops of the mammillæ. Pylorus normal. Duodenum. readily on pressing gall bladder bile flows from pap. bileum. Tissues in vicinity duodenal ligament thickened, lymph glands enlarged & appear cancerous. No dissection

225

301 pp + numerous inserts

Osler's M. G. H. autopsies, nos. 291-428
14 Mar, 1879 to 12 Sept. 1880 (at p. 57).

10117

...re range 99 – 102 °F.

...gned) Allen Bell

...lymph,
...gelatinous looking
...from surface
...in a state of
...ver lobe is in a
...=

Case	291	Cancer of Stomach
"	292	Fibro-Sarcoma of Testicle
"	293	Caries Cervical Vertebræ
"	294	Cancer of Kidney
"	295	Diphtheria
"	296	Morphia Poisoning
"	297	Asphyxia ?
"	298	Phthisis
"	299	Phthisis. (+)
"	300	Empyæma. Lobar Pneumonia
"	301	Diphtheria
"	302	Primary Cancer of Liver
"	303	Phthisis. Emphysema. Ulceration into Pulm. Art.
"	304	Fibroid Kidney. Prog. alb. Coma
"	305	Miners Lung
"	306	Pneumonia.
"	307	General Tuberculosis. Cerros. Sub. Poisoning
"	308	Pleuro-Pneumonia.
"	309	Contracted Kidney. Anæmia
"	310	Pneumonia
"	311	Syphilis of Rectum, Albuminuria.
"	312	Sclerosis of Cord
"	313	Phthisis
"	314	Martin Phthisis
"	315	Cirrhosis of Liver in child æt 9.
"	316	Impaction of Fæces. Peritonitis
"	317	Pneumonia (+)

re range 99 – 102° F.

gned) Allen Bell

lymph,
gelatinous looking
from surface
in a state of
ver lobe is in a
=

Case	318	Phthisis
"	319	Diphtheritic Endometritis
"	320	Duodenal Ulcer
"	321	Diphtheria
"	322	Hernia
"	323	Abscess about appendix Perforation of Bowel.
"	324 ✓	Meningeal Hæmorrhage
"	325	Chr. Brights Disease
"	326	Pneumonia
"	327	Phthisis
"	328	Cirrhosis of Kidneys. Pul. artery thrombosis
"	329	Pyæmia
"	330	Phthisis
"	331 ✓	Caries of Vertebræ Abscess of heart wall
"	332	— Doubtful
"	333 ✓	Aneurism of Basilar artery
	333 A	Cancer of uterus Pyonephrosis
"	334	
"	335	Mitral valve disease. ~~Soft~~ Soft of Corp Striati cm 55 p
"	336	Leukæmia. Hæmatemesis. Remarkable V. porta
"	337	Purulent Pericarditis
✓ "	338	~~Purulent~~ Tuberculous Meningitis
"	339	Cancer of Stomach — (p. 58)
"	340	Corrosive Sublimate Poisoning
"	341	Cirrhosis of Liver
"	342	Cerebral Hæmorrhage. Hæmorrh. Infarc. of liver
"	343 ✓	Cancer of Brain
"	344	Myo-Sarcoma of Kidney

Case	345	Phthisis
"	346	Typhoid Fever Perforation, 78 (18)
"	346A	
"	347	Morbus Cord. 81
"	348	Elephantiasis 83
"	349	Typhoid Fever 86 19
"	350	Phthisis (Fibroid) 88
"	351	Chronic Pneumonitis 92
"	352	Typhoid Fever 95 20
"	353	Typhoid Fever 97 21
"	354	Comp. 100
"	355	Emphysema 101
"	356	Typhoid Fever 104 22
"	357	Typhoid Fever 106 23
"	358	Typhoid Fever 109 24
"	359	Aneurism of Ant. Com. Artery
"	360	Morbus Brightii 110
"	361	Pneumonia 122
"	362	Chr. Pleurisy (?) Hyper. Rt. Heart 124
"	363	Cirrhosis of Liver 127
"	364	Typhoid Fever 129 25
"	365	Meningitis 133
"	366	Morbus Cord. 130
"	367	Phthisis 139
"	368	Phthisis Aneur. in Pul. art. of Card. 308
"	369	Phthisis Lobar Pneumonia
"	370	Phthisis. Tuberculous Peritonitis 148
"	371	Phthisis 151

re range 99 – 102° F.

gned) Albert Bell

– lymph,
gelatinous looking
from surface
in a state of
ver lobe is in a
=

Case	372	Phthisis 155
"	373	Fract. ribs. Incarc. & Gang. of Lungs 157
"	374	Mitral Disease. Embolic Cerebral Apl. 159
"	375	Pneumonia (no expt.) 163
"	376	Ovarian Enfeblatis 164
"	377	Mitral Stenosis 166
"	378	Ulcerative Endocarditis 168
"	379	Arteritis Pulmonis. Gang of Lobe 170
"	380	Phthisis 172
"	381	Cirrhosis 174
"	382	Suppurative Synovitis (knee) 176
"	383	Multiple Echinococci 178
"	384	Febrid Phthisis 193
"	385	Aortic valve Disease 197
"	386	Pneumonia Uraemic Coma 201
"	387	Cirrhosis of Liver 206
"	388	Volvulus 208
"	389	Phthisis 210
"	390	Mediastinal Cancer 212
"	391	Leucocythemia 215
"	392	Caries of Ankle. Tub. Meningitis 216
"	393	Insuff. of Mitral. Pneumonia 217
"	394	Aortic Valve Disease
"	395	Phthisis 222
"	396	Umbilical Hernia (enc) 224
"	397	Mitral Stenosis 225 (not reported)
"	398	Pyaemia 227

Case 399	Senile Gangrene	229
" 400	Phthisis	230
" 401	Insular Sclerosis	
" 402	Emphysema	230
" 403	Fract. leg. Ulcerative Endocarditis	240
" 404	Apoplexy of Pons & Cerebellum	242
" 405	Pneumonia	246
" 406	Tuberculosis Lung. & kidneys. Calc. Rem	247
" 407	Ulcerative Endocarditis & Endarteritis	257
" 408	Phthisis	254
" 409	Cystitis. & Lithotomy.	261
" 410	Mediastinal Abscess Localized Empyema	265
" 411	Phthisis	266
" 412	Phthisis	268
" 413	Broken Back	271
" 414	Mastoid Disease abscess of Brain	274 (no report)
" 415	Phthisis	276
" 416	? ?	
" 417	Endometritis Diph. Colitis	
" 418	Cancer. Oesophagus	283
" 419	Dysentery (no report)	
" 420	Abscess between Liver & Stomach. Cerebral Syph.	287
" 421	Tuberculosis	291
" 422	Phthisis	293
" 423	Phthisis	294
" 423(A)	Typhoid Fever	296
" 424	Pharyngeal Hemorrhage	298

...re range 99 – 102° F.

...gned) [signature]

...lymph,
...gelatinous looking
...from surface
...in a state of
...ver lobe is in a
...=

Ca

Case 425 General Tuberculosis p 50
" 426 Fibroid Pleurisy p 52
" 427 Pneumonia p 55
" 428 Tetanus 57

Cancer of Stomach

CXCI Margaret McIntosh aet 60. entered Hosp. March 14th
died. " 25

Body that of an elderly, fairly well nourished woman. Very
ttle emaciation. Pan. ad. 1/4" thick over abdomen, Skin jaundiced
tegularly in upper regions of body
bdomen slightly protuberant, and a tumor can be felt at the junct-
of the epig. and umbil. regions. On opening cavity, omentum covers
mall intestines. & is not adherent. Stom. projects in epig. region
elow left lobe of liver & left costal border. Transverse colon crosses
level of umbilicus and is very full of hard faecal mass, - a good deal
the tumor evident externally being due to this cause. Coils of small
testine are shrivelled and matted together with lymph. At the
loric end of stom. there is a nodular mass, corresponding situated superficially & ~~[illegible]~~
ally with pressure on ant. border of liver and the right margin of left
e, wh. is in contact with it. After removal of intestines the mes-
tery forms a large projecting mass containing numerous cancerous
nods. & is especially thick at root. and in region of pancreas.
ft lobe of liver extends as a thin narrow projection far into the left
ypochondriac region where it is firmly attached to the ant. portion
the spleen. On opening thorax lungs look natural - no
hesions of pleura. ʒii of ble stained serum in pericardium
ungs., a little emphysematous in front, congested in dependent
rts. otherwise normal. Heart normal size - a good deal of
bpericardial fat. Valves a little thickened - otherwise normal.
Stomach liver & duodenum. removed together
Stomach contains a quantity of partially digested food

ture range 99 - 102° F.

gned) James Bell

ra closely covered
lymph,
gelatinous looking
from surface
in a state of
ver lobe is in a
d=

Inward pylorus N. M. mammillated and covered with
a glairy exudation. The pyloric zone for a distance of 2" from
the ring is firm and thickened and the seat of cancerous de
The pyloric orifice is moderately contracted admitting the ex
fingers with difficulty. The Cancer occupies the lesser cur
and the ant & post. walls leaving only a narrow portion
3/4" in breadth unaffected. From the region of the lesser curve it
projects into the duodenum for 10 ½ in the form of irregular
fungi's. The cancer is flat, with smooth surface, nodulated
here & there a little pitted. On section it involves the entire
membrane, but the mus. can be seen beneath perfectly
The cancerous area forms a sort of flattened groove passing
towards the pylorus, while the unaffected area forms a deep
a narrower channel, sharply bounded by the edges of the cancerous form
On slitting up duodenum, there is an elevated ridge corresponding
to the papilla bilis, and below this there are several soft papillo
gelatinous. Pressure on common bile duct presents into duodenum
no discharge of pepsin. duod. tegument, portal vein contains small
clot. At the region close to head of pancreas there is a good deal narrowing
of pressure of can. glands in this region. The upper part appears dilated,
the ch branch admitting index finger partly, but left to the left
finger. Artery normal. All the tissues in this situation are matted
together & several enlarged cancerous glands exist at portion part
which appear to compress somewhat the hepatic ducts. The neck of
the gall bladder is also involved in a secondary mass
The pancreas is enlarged, very firm and dense and is the seat of secondary
disease

liver presents one small secondary mass in the posterior border
kidneys normal in size, nothing special noticeable
nothing abnormal in small or large intestine. The mesentery
slightly enlarged owing to the presence of numerous cancerous
nodes, some of which are as large as a small apple. A section
of any one cancerous, and from only a few ~~present~~ both cancerous, the other
hard & dense.

XCII Fibro-Sarcoma of Testicle

ture range 99 – 102° F.

igned) Allen Bell

lymph,
gelatinous looking
from surface
in a state of
ver lobe is in a

4

Ca 2

ture range 99 – 102° F.

igned) Alice Hall

– lymph,
gelatinous looking
from surface
in a state of
ver lobe is in a

4

Ca 2

ture range 99 – 102° F.

igned) Allen Bell

lymph,
gelatinous looking
from surface
in a state of
ver lobe is in a

4

Ca 2

CXCIII Caries of Cervical (1st & 2nd) Vertebra.

Edward Gleason at 30

Body average sized - considerably emaciated. Bed sores on ~~back~~ all
prominent points posteriorly and beneath skin from 7th cer. to 5th dor.
On the right side
vert. there is a large superficial abscess - walls rough, irregular, in-
filtrated with blood and about 8 ozs of bloody pus escaped from the
incision. A smaller one exists on left side close to 3rd & 4th dorsal vertebrae
~~under~~. On the right side the deep muscles of the upper cervical region -
recti postici, the obliqui & the complexus are infiltrated with
creamy pus, with which cheesy lumps are mixed. Anteriorly
the Recti muscles of the right side, together with the upper part of
Longus colli are infiltrated with pus and contain caseous nodules.
Deep
Head all the tissues in the upper part of the neck on rt side are in this
condition. From 2-3 ozs of pus escaped from the incisions. The abscess-
united ~~externally~~ in the pharynx as a slight oval projection in the level
of the epiglottis. It was separated from the lube of pharynx by the thickened
the wall, but immediately beneath epithelial layer there was a
small superficial layer of pus - apparently unconnected with
the main abscess. Careful dissection of the cervical vertebrae
revealed the following condition -: Both anterior and posterior
occipito-atloid ligaments are thickened and infiltrated with
pus, particularly on right side. The rt. condyle of occip. bone is
imperfectly devoid of cartilage, very rough on surface & edges. The left
slightly diseased. The atlas is abnormally affected. Both anterior
arch has ~~not~~ & not arch on right side in same state. Articular

ture range 99 - 102 °F.

igned) Allen Bell

- lymph,
gelatinous looking
from surface
in a state of
ver lobe is in a
=

surface on right side denuded. on left side partially so
Atlo-axoid ligament in front and behind on this side gone
destroyed and the ~~purulent matter~~ and caseous matter is
directly continuous with the spinal canal. On looking at
cer. vert. from above. it is seen that the odontoid process of the axi
is out of place, encroaching on the posterior arch of the atlas, comp
the cord on the side, and has great mobility, the transverse
and check ligament being gone, so that the process can be fre
moved backwards and forwards. The occipito-axoid ligament
is also destroyed. The tip of the odontoid process retains its ca
tilage but in the rest of its extent it is rough and bare. The en
body of the axis is denuded of periosteum on both its inner and
outer surfaces, with the exception of the left half of the arch behind,
and is covered with pus and small masses of cheesy matter
sup. art. surface, right side, has lost its cartilage on left side the partly
remains. The

The patient was under the care of Dr Ross (? Kinch). The case attracted much attention from the remarkable intermittent paralysis. When at absolute rest he was comfortable and had no paralysis (?) but when he attempted to move, particularly if the head moved, he became paralysed in all 4 limbs. A 'jury mast' was rigged with which he was for a time comfortable.

W.O.

ture range 99 – 102° F.

igned) Allen Kell

lymph,
gelatinous looking
from surface
in a state of
ver lobe is in a

31/3/79.

CCXCIN Cancer of Kidney 9 hrs Pm.

J.J. at. 47. Had suffered for over two years with symptoms of renal disease, the chief of which was haemorrhage. In May '77. passed a remarkable blood cast of the ureter. For over a year a tumour has been evident on the left side & has been gradually growing, while the patients strength & flesh have progressively decreased. He suffered little or no pain during the entire illness and up to two weeks of his death the appetite remained good, within this period a few irregular brain symptoms had developed.

Body that of an average-sized, greatly emaciated man. An enlargement of the right side of abdomen, firm and regular to the limit, is evident on inspection and palpation. It is also not movable, dull on percussion. On opening abdomen, peritoneum is smooth - no exudation. Viscera are pushed aside by a large tumour mass is visible occupying the hypochon. & lumbar of left side and extending over on the epig. & umbilical area beyond the middle line. It passes from up- to level of 4th rib on left side and below nearly to spine of ileum. It is covered with smooth peritoneum; the transverse colon passes across it about the upper third and near the middle the pancreas is closely across it to the duodenum. The spleen is closely adherent to the upper end. The tumour readily ~~frees~~ lungs out, not having any very firm attachments except near vertebrae when it has evidently surrounded the aorta, which, with V. cava, was removed with it.

Tumour is oval in shape, measuring 71 cm long in circumference, 26 cm in broad. Lower end is pointed, upper end more obtuse. In the

posterior part, from 5 to 10 ~~in.~~ cm. (Both layers)
at the upper part, not quite so thick, at the
lower part and in front, there is an incap-
sulated pleurisy about half the size of
the hand, fluid clear. Towards the root of
the lung behind, the thickening of the pleura
is not so great. On section, there is a cavity
at the posterior part of the apex, the size
of an orange, it has thick walls, contains
a quantity of purulent fluid and towards
the root are the projecting and eroded
ends of Bronchial tubes, there is a long
projection from this cavity downwards
inwards and forwards towards the middle
lobe. The extreme apex and the entire anterior
margin is composed of dense firm, excessively
pigmented fibroid tissue. The middle lobe
is crepitant, emphysematous and contains
many small fibroid and pigmented areas.
Lower lobe is crepitant, but at the same time
firm and not very yielding. Small dark
fibroid areas are numerous.

ture range 99 – 102°F.

igned) Allen Bell

lymph,
gelatinous looking
from surface
in a state of
er lobe is in a

Spleen, weight 180 grammes. Capsule
firm, fibroid in places. Pulp in good Cons
-ce. Malpighian bodies distinct.
Kidneys - weight 183 grammes - each.
Form hard, surfaces smooth, Capsule
not thickened, tissue healthy.
Liver - little fibroid in Ant
-rior region, otherwise perfectly healthy
Stomach and Intestines present
nothing abnormal.

CCCVI Pneumonia 20/4/79

Child. at P. I. since at 6. months ill for a few days - chief symptom
diarrhea + slight cough.
Body well nourished - Cyanosis confined to head.
Nothing abnormal in abdomen, along the dorsum the ends of a few rays
+ Peyers patches. Heart - Normal size - right chambers full of blood and
+ loosely firm clot fills the tricuspid orifice - valves healthy
Lungs - right - a good deal of collapse posteriorly + at one spot - about size
a walnut - the lung will not dilate, but remains firm + red - and in section
a finely granular appearance. There is a long streak in the post surface of the left lung
also firm + dense, + not perfectly dilated. In both lungs chiefly in front are several
spots of interstitial emphysema, some extending thro' the pleural margins of the lungs, in
long lines, others the size of marbles project beneath the pleura.
Spleen pale, purple in colour. Kidneys normal. Stomach
presents nothing unusual. Intestines pale. No ulceration. Solitary
mucous, Peyers patches are distinct + several of them injected. - one at upper end
of ileum presenting luminous slender ridges of a deep red colour. No ulceration. Mesenteric
glands normal. Brain normal.

allthy. Bladder normal.
er, small & natural colour; one secondary nodule
size of a ~~large~~ walnut at posterior border.
mach, and intestine empty, but natural looking
ain not examined

XCV Diphtheria 1/4/79

McLaughlin at 21 admitted March 30th. Tracheot. 31st. 1.30
P.m. died 330

ody that of a well-built muscular young man. Rigor
rtis strongly marked. Dependent parts very livid - face &
k also. In abdomen position of viscera normal.
thorax. a few adhesions in right pleura. Pericardial
luid normal in amount. In pulm. [illegible] in heart. 7 oz
blood and clots escaped. Heart of average size. Valves normal.
uspid orifice 5 1/6 in in cir. Mitral 3"10"'. Beneath endocardium
ll vent. part of septum there are numerous ecchymoses. Several
the col. carnea are haemorrhagic throughout. Rt vent. length apex to
ring. 10.5 ctm. Left. apex to aortic ring 9 ctm.
leen a little enlarged, soft and flabby.

ture range 99 - 102°7.

igned) James Bell

closely covered
lymph,
gelatinous looking
from surface
in a state of
er lobe is in a
d=

Kidneys of average size; capsules detach readily. On secti
substance coarse looking, contains much blood particular
about bases of pyramids. Med. rays distinct, vessels between them
congested. On examination epith of tubules granular, cloudy.
Micrococci are seen in ~~the~~ many of the cells

Pharynx
Trachea Bronchi and Lungs removed together.

On looking into phar. from the front the enormously swollen ton
and uvula meet and entirely block the communication with
the mouth.. posteriorly. they fill up the upper part of pharynx
they are covered with a dirty greyish white exudation, in places
stained with iron and on section are seen to be infiltrated with blood
and serum. The swelling and membrane are continuous w
the front part of post. nares. Epiglottis is swollen & injected b
is not covered with membrane. In the larynx mucosa is redde
& vocal folds are a little infiltrated, but the only bit of membrane w
on the left aryteno-epiglottidean fold. The m.m. of trachea, ~~[illegible]~~ ma
bronchi and ramifications of the 3 & 4th degree is covered
with a thin yellowish wh. membrane, loosely adherent, & bene
of the mucosa is deeply injected. Lungs are full in volume but
not as crepitant as normal. The posterior part contains much
blood and serum.

XCVI Morphia poisoning 3/4/79

mt. an american found dead on his bed in American
use. with bottle of morphia by his side
dy that of a ~~stout~~ well built muscular man. Face suffused.
ts moderate size. Rigor mortis present.
thing abnormal in abdomen. In thorax no adhesions in
ura. Pericard. contains an ounce of serum.
heart. of full size, right chambers distended with blood, chiefly
ed only a few small clots. Left aur. contains about 1 ʒ of
d & clots, Lt. vent. small amount of blood. From the pulm.
sions and in removal of heart. about. 14 ʒ of blood escaped
ything abnormal in valves or orifices of heart. Tricuspid is
e admitting 4 fingers freely. Rt chamber large. Muscle
stance of heart. healthy
gs; no pleural adhesions. Both are a good deal congested
ently, ~~much~~ blood and serum ooze from cut surface. Along
surface of right upper lobe there is a superficial spot of apoplexy
gular in shape, covering more than one half of the ant portion
lobe. & extend fr. 4 - 12 mm into the substance. There
also a few ecchymoses scattered over the visceral pleura.
een of moderate size, soft. & contains much blood.
neys are healthy. capsules detach easily. On section a good
l of blood bathes the surface. veins are full.
er. natural looking - vessels full particularly of hepatic
stem - but organ not "nutmeg" in appearance.
ladder distended reaching half way to navel. On

---

ture range 99 - 102° F.

igned) J. Mitchell

---

a cloudy covered
lymph,
gelatinous looking
from surface
in a state of
er lobe is in a
l=

squeezing it from the urine passed for one hour & a
filled a ordinary beer bottle. - pale in colour.
. Stomach removed after being tied.
Intestines as far as inspected appeared natural.
Brain. Dura mater normal. sinuses moderately full
of blood. Veins of pia mater full. but not distended.
Cerebrum at base normal. Moderate amount of fluid.
ventricles. On section, white and grey substance factorially
vascular

4/4/79

CCXCVII Asphyxia.?

Carr. at. found dead in "Ivy Bush" canteen. a man 43 yrs.
Short. stout, well nourished man, Negro-Provence. Face
suffused and purple in colour. Rigor mortis strongly marked
. Rolling mucus in abdomen. In thorax. right. pleura. pres
a few adhesions. In pericardium 3i of serum. A large pal
of pulmonum on right heart, and the whole of the under surface
of rt. auricle is opaque & milky. Rt. chambers of heart dist
with fluid blood and a few small coagula. Full. 10-12 o
of blood escaped from chambers and veins. Left chambers
also contain dark blood - not so much, and the aorta is also
full. Heart is of normal size, valves quite natural. Muscle
supra is large. adultly 4 inches. Muscle substance

leural.

ngs: moderately engorged at bases; in post. section somewhat dry., No ecchymoses; no spots of consolidation. a good deal serous, in posterior parts. Pul. arty & veins cont. blood, and. but an

leen. of average size, soft. pulp. dark purplish in colour.

dneys large, coarse looking, capsules detach readily

eins at bases of pyramids full. vessels of cortex distinct

adder distended with clear urine - reaching 3" above of pubes

ver healthy looking - dark reddish brown in colour

eins full. - Gall bladder full of bile.

mach tied at both ends and removed.

testines healthy.

rain. Sinuses of Dura mater contain fluid blood.

eins of pia. moderately full. Nothing of note discovered in careful dissection of the organ.

(Contents of stomach not analysed. Verdict. of Asphyxia m. alcohol. returned - no evidence whatever of it!)

---

ture range 99 - 102° F.

Signed)

---

rd cloudy covered

lymph,

gelatinous looking

from surface

in a state of

er lobe is in a

l=

7/4/78.

CCXCVIII Phthisis

-- at. man. Not much emaciated, Rigor mortis present.

In abdomen coils of intestine look natural. Liv projects for four inches below the Ensiform Ca and the lower margin of right ~~lobe~~ is on level w the crest of Ilium - Between this lower part and th abdominal wall an three or four coils of smal intestine which completely conceal the lower margin of liver. Diaphragm corresponds on right side to upper margin of sixth rib. On left side to the lower border of fifth -

Thorax Left lung covers ~~over~~ over upper border of L heart and looks natural - On rgt side only a smal portion of lung is seen; while at upper part post med. are 5-6 enlarged gland In removal of sternum a large purulent sack has been exposed exte beneath the costal cartilages from second to fourth. It can be traced from this point to a second sac. above diaphragm, with which it communicating an opening admits index finger. ~~pleural cavity below~~ - The upper part of pleura on right side is closely adherent - & very much thickened. Opening rgt auricle antemortem clot in append the sinus filled with dark clots - Rgt ventricle conta antemortem clots and also other dark Coagula - In left auricle dark clot - In left ventricle firm ant mortem clot - 14 ʒ of blood on removal of heart - Right auricle nothing special beyond slight hypertrophy mus. pect. - Right ventricle large, chamber appears slightly dilated - Tricuspid valve are a little thickened at apices - Pulmonary sem

t is large - particularly right vent.-

eight of heart 450 grs.

ar valves normal- Tricuspid orifice greatly
arged- Heart cone passes freely thro' - meas. 6 inches
t auricle presents nothing abnormal left ventricle is
ge- Mitral valves normal Aortic semilunar
ves competent - Mitral orifice measures 5 1/3 in in
cumference - Length of left ventricle from aortic
g to apex 4 1/4 in - Length of rgt ventricle 5 in -
d of rgt ventricle 1/4 in - Left ventricle 1/2 in -

ft **Lung** greater part of both lobes covered with
untic membrane - The upper lobe of the lung is
pitant but here and there throughout it are
dular masses - The lower lobe is dense heavy
y slightly crepitant - On section lower lobe is bathed
h serum - The central portions of the lobe are firm
dish brown in color, surface slightly granular
but with [illegible] some distance
hed with serum, portions excised float
nt of the lung was in state of commencing hepatization from board -
upper lobe contains numerous tubercles
apex and at posterior part there is a cavity
with purulent contents
size of a small apple - Its cavity has definite
els & contains a reddish pus - The tubercles are
and are confined to upper lobe
form, hard and aggregated together in groups
ght **Lung** - Almost the entire upper lobe except a
all part in front is occupied by a huge cavity
a good deal
~~what~~ larger than closed fist - The walls
thick
reddened - Very few trab across the cavity

ture range 99 - 102°7.

Signed)

ered cloudy covered
lymph,
gelatinous looking
from surface
in a state of
ver lobe is in a
=

4

Middle lobe contains several small cheesy mass
and one or two small cavities - The anterior part of
apex the pleura is very thick and between the
layers at this part there is a localized empyema
2½ by 2 in - The lower lobe contains many
tubercles and at the extreme base the tissue is
heavy very slightly crepitant & backed with a
good deal of bloody serum collapse. The Diaph pleura
is thick and between layers at the ant & inner
part there is another localized empyema
wh. is in communication with the one that above
described situated beneath the cartilages
on right side. The sack is flattened and contains
a couple of ounces of creamy healthy looking pus
The lungs collapse at ant part of both lungs due to empyema pulmonales.
Spleen, Capsule a little opaque, substance dark
brown color consistence fair Wgt. 185 grs -
Kidneys Capsules detach easily - Healthy - Wgt 2 lbs
Stomach contains undigested food Mucous mem
covered with thick mucous - It appears apparently
natural Duodenum normal - both films found
Intestines no ulceration in small or large -
Liver Rgt lobe quadrilateral in shape, anterior
portion projects considerably - Healthy, gall
bladder normal
Aorta presents numerous patches of atheroma
chiefly in form of flattened whitish yellow
ulcerations, it is confined entirely to thoracic portion

...vessel is not dilated
...pain. Lung tissue contains a clot discolorized
...with anterior portion, other tissues also
...stain dark cruguler, Base of brain
...sometimes normal, arteries contain blood
...careful inspection nothing abnormal found.

XCIX. Phthisis

...ture range 99 - 102°7.

(Signed) Allen Bell

...lymph,
...gelatinous looking
...from surface
...in a state of
...er lobe is in a
...=

4

Ca

11 apl 79

299

~~298~~. 299 Ward No 21

Phthisis - Caseia in Lungs
Tuberculous Ulcers large intestine -

Driscoll age 25 died apl.

Inspection Considerable emaciation - on opening abdomen position of viscera normal omentum very small - Lacteals in upper part of mesentery injected -

Thorax Both lungs adherent normal amount of fluid in pericardium - Right auricle filled with a large gelatinous clot which extends to the veins -

Heart Right auricle large, a cribriform eustachian valve of considerable size persists - Right ventricle normal size, Tricuspid valves healthy, orifice measures 6 ½ in circumference nothing special in left auricle, left ventricle nothing unusual - Mitral orifice measures 4½ in Circumference - valves normal Aortal valves Weight of heart 10 oz -

Right lung almost slightly crepitant and numerous small masses are felt through it. the Pleura crossing it is universally adherent. On section upper lobe is stuffed with tubercles about the size of small shot, in this lobe the anterior lateral region there is an irregular cavity containing a reddish pus which presents two or three branches some portions look like and probably

ture range 99 - 102° F.

(Signed) [illegible]

- lymph,
gelatinous looking
from surface
in a state of
er lobe is in a
=

Ca2 are ~~about~~ dilated Bronchi - There is a small
" cavity the size of a walnut in the cavity of the
" upper lobe
" Lower lobe contains much blood and numerous
" numerous tubercles scattered through the tissue -
" no cavities -
" Left Lung very slightly crepitant, the upper lobe
" contains a small cavity nearly full of dirty pus,
" it occupies the anterior upper and lateral region
" of this lobe the number of trabeculae cross the
" cavity, the lining membrane is greyish yellow in
" colour and in places surrounded with a greyish
" membrane - the extreme anterior portion of the
" lung is occupied by numerous cavities -
" Lower lobe large irregular cavity in upper part
" another at extreme base, the rest of the lobe is
" stuffed with tubercles - Bronchial mucous membrane
is injected Bronchial glands enlarged but caseous
Spleen 1/3 lbs. Pulp firm presents nothing abnormal
Kidneys normal size Capsules detached with
slight difficulty, Substance normal - one or two
small masses probably tubercles -
Liver 1680 grs - On section presents a number of
whitish areas surrounding the central veins
of the lobules, they do not project above the surface

Organ is firm and contains a moderate amount of blood.
Stomach mucous membrane pale except at cardia
Slight mammillation at pyloric portion
Intestines nothing of note in jejunum when lower part of Ileum is reached a few patches of tubercles are found.
Larger intestines. In Coecum extensive ulceration more than 4/5 of it. It has disappeared, the mesenteric vessels in places being bare. Through the ascending colon there is also extensive ulceration, the solitary glands are much enlarged. Scattered over the membrane are numerous small polypoid outgrowths about 2 or 3 lines in length almost black at their extremities, pedunculated the pedicles in many instances elongated the sigmoid flexure is the only part which does not present ulcerations
Brain nothing special in Dura mater
Slight matting of Pia mater in

[illegible] range 99 – 102° F.

(Signed) [illegible]

[illegible] lymph,
[illegible] gelatinous looking
[illegible] from surface
[illegible] in a state of
[illegible] ver lobe is in a
[illegible]

3 Campbell
24 Thompson
7 Henderson
18 Pulford
21 Vikes
11 Mc Tavish
5 Fyfe
2 Davies
25 Thornton
12 McGillis
13 Morris
~~McGill~~
14 McKittrick
1 Ayers
19 Page
9 Lamie
15 McDonald
16 McMichael
20 Paquenault
22 Schonert
6 Thaler
8 Hunt
17 Mignault
23 [illegible]
4 [illegible]

ture range 99 – 102°7.

Signed) Allen Bell

– lymph,
gelatinous looking
from surface
in a state of
ver lobe is in a
=

12/4/79

CCC. Empyema. - Lobar. Pneumonia

Hanna ætt 18 months, a delicately built, considerably wasted child.; Ill for 2 weeks with pleurs & empyema for which she was tapped & a drainage tube inserted

In abdomen nothing of special note.

In thorax, on removal of sternum with cartilages ribs the left pleura in entire extent seen covered with a dirty purulent material, which extends to the ant. mediastinum. Rt pleura free. Pericardium contains a small amount of fluid mixed with a little pus & a few shreds of lymph floating in the fluid. Heart healthy. Right lung, upper lobe crepitant full of blood & pretty airless, middle lobe crepitant in its anterior portion, dark red & solid at the root. Lower lobe partially solid & heavy, of full volume, on section surface reddish brown, dry, and presents a purely granular aspect. Rt. Hepatized. Pleura over it dimmed & covered with a thin flake of lymph. Left pleural sac contains a small amount of pus - lying at the lower & post. part about two tablespoonfuls of thick yellowish curd-like material - evidently incipiated pus. The entire parietal pleura is in a condition of suppuration, covered with a dirty-greenish yellow pus In many places the pleura is gone and the ribs are bare, particularly at the anterior parts. The orifices of the drainage tubes are in a slaughy condition. The lung is contracted, occupying a portion close to the vertebrae and is covered with the curdy matter above described. Over this the visceral layer is universally involved

C 1. Diphtheria 13/4/79

...ture range 99 - 102°7.

(Signed) Allen Bell

...lymph,
...gelatinous looking
...from surface
...in a state of
...ver lobe is in a
...=

in looking over the necessary papers found the Report on Physiology wanting –

Excuse a very hurried note & believe me

Yours truly

Mary M[illegible]

Hon. Sec. L.S. Assoc

Ap. 14th

15/4/79

C 111 . Pul. artery

Messenger ly of haemorrhage

April 15th

Body that mortis

ext. not pended note

abdomen chest at apex

and adhes lung full

volume, ant margin

left. ven he normal

amount of s full of blood.

normal escaped.

ent is hy Tricuspid orifice

in circumference. valves a little opaque. Pul. semilunar punctated

left ~~aur.~~ vent. normal size valves natural. Aort. semilunar punctated

pus trachea & Lungs removed together Small quantity of

bloody fluid mixed with air in larynx & trach & bronchi then is more

considerable quantity with some clots flows from the left

bronchus. M. M. of trachea thickened & rough & the whole tube looks

---

ture range 99 – 102° F.

(Signed)

---

cloudy covered

lymph,

gelatinous looking

from surface

in a state of

er lobe is in a

d =

[illegible] several [illegible] diaphragm
upper surface [illegible] but present
many flattened and [illegible] masses of a
yellowish white colour [illegible] mottled with red
they project very little and only 2-3 of these are
slightly cupped. The masses range in size from a
pea to a large walnut. The colour of the organ
is of a grey red for the most part, the peripheral part of the
new masses are injected, while their centres are
white or yellow white, the intervening substance
is of a yellowish fatty look with central veins full.
On under surface the masses are not so numerous
but several of them are large.
Glands in portal fissure, gland a little enlarged.
Vein, into portal branches compressed [illegible]
size of little finger [illegible] right [illegible] left.
On making section thro the greater part of the substance [illegible]

15/4/79

C 111   Phthisis. Emphysema. Ulcerat. thro. Pul. artery
essenger. aet. 47. admitted Nov. 15. died suddenly of haemorrhage
ril 15th. P.M. 3½ hours after death.
dy that of a fairly well nourished man. No rigor mortis
st. not markedly barrel shaped. Nothing special noted
bdomen. In thorax. Rt. pleura very adherent. Left chiefly at apex
d axillo-lateral regions. Anterior margins of rt. lung full
olume, do not collapse, reach the middle line. Ant margin
ft. over heart looks firm & feel solid. In pericard. normal
ount of fluid. **Heart** of average size, rt chambers full of blood.
moral. Opening 12 ozs of fluid blood & clots (small) escaped.
eart is hypertrophied ant wall 3/8" in thickness. Tricuspid orifice
in circumference. valves a little opaque. Pul. semilunar punctated
ft ~~auer~~ ventr. of normal size valves. natural. Aort. semilun. punctated
uces trachea & Lungs removed together. Small quantity of
ody fluid mixed with air in larynx & trach & bronchi then a more
nsiderable quantity with some clots flows from the left
nchus. M. M. of trachea thickened & rough & the whole tube looks

---

ture range 99 – 102° F.

(Signed) Alex Bell

---

re cloudy covered
lymph,
gelatinous looking
from surface
in a state of
er lobe is in a
l=

abnormally stiff and rigid. The orifice of the mucous plug
an very distinct parchment at the upper part. On slitting
up the main bronchi and washing off the blood the mucous
seem to be thickened 2-3 mm. rough from the projection of little masses
which give to it a like coarse granulations. It is thicker
the posterior than the anterior part of the main bronchi. On the
left side the 1st division of the bronchus & its three principal
sub-lobes the upper lobe is specially affected, the granulations being
very numerous & large at the points of bifurcation.
At the upper and outer wall of the post division of the bronchus
just before its bifurcation into the tubes for the lobe there is a
reddish spot in the mucosa, 7 mm. in diameter, projecting
slightly towards the lumen of the bronchus. The membrane at
this place is soft yielding and it appears to be ulcerated, at
the edges there is an evident depression and the cartilages
appear deficient. On careful inspection it is seen that only a
septum separates the bronchus from the pul. artery, and at
lower part of the rupture has taken place, & a slit like opening
2.5 mm in the length. There is no other depression
in the neighbourhood but the mucous is much roughened &
calibre of the tubes passing to the upper lobe considerably narrowed.
From the side of the artery there is seen a circular spot in the wall
.5 cm in diameter slightly depressed, with a slightly elevated
border. - membrane covering it reddish in colour & without
any adherent fibrin & at lower margin is the slit above described.
Left Lung. Lateral part of upper lobe covered by a thick opaque
white membrane 2-6 m in thickness, getting thinner towards

margins. Lower lobe lateral region below pleura covered by
cent lymph & membrane injected for space of 2 sq inches. Upper
is but slightly crepitant. ant margins quite airless. On section
x is occupied by numerous small tubercle a few caseous masses
the tissue is crossed by several white bands – thickened interlobular
la– The post part of upper lobe above is occupied by a cavity
size of a small orange, full of blood, & clots – walls crossed by
beculae, upper part soft & cheesy. Two bronchi penetrate it
walls of which are roughened & in the neighbourhood of the
ity the mucosa has almost disappeared. Near the root of
lobe, in the postero-lateral ~~region~~ is a small cavity full
lood; Another, the size of a large walnut is placed more anteriorly
in the same level. The portion of lung contiguous to the anterior
diastinum is firm airless – translucent looking and on section
pears in a condition of "gelatinous infiltration" being a greyish
ct. & scattered thro. the tissue are groups of tubercle
lower lobe, its upper parts contains groups of tubercles and
ew small caseous masses. At the lower & lateral surface is
ll marked infarct: the size of a walnut – somewhat triangular
ection, firm brownish red colour & the pleura over it inflamed
bronchiole passing to it has thickened walls. The pul artery was traced
ward it but the embolus was not formed. In the interior of the main bronchus
ving thro the lower lobe were several spots of thickened, pigmented
rregular films ~~or that~~ passing across the wall. Ant & lower parts
o lobe free from tubercles
lung full in volume. Pleura thickened and almost universally
herent. All borders quite rounded. particularly below. Entire lung

ature range 99 – 102°7.

Signed) James Bell

ra closely covered
lymph,
gelatinous looking
from surface
in a state of
ver lobe is in a
l=

Ca 2

Emphysematous, no slight crepitant & have a doughy feeling feel. A few tubercles are scattered in groups the upper lobe. In lower lobe the bronchi appear large. is somewhat dilated & the walls thickening. A good many groups of tubercles in lower lobe

Spleen large. 383 grams. Capsule a little opaque, pulp tolerably firm. Malpighian bodies distinct

Kidneys normal in size, a little coarse, contain a good deal of blood.

Stomach contains about 1/2 oz of clots and blood. mixed with the contents of the organ. The clots contain air and are dark in colour. Mucous membrane is much mammillated & considerably thickened. Intestines are natural

Liver. presents 3, 4 grooves at post. part superior surface, more deep. others superficial. Organ a little filmed

Brain. Triangular shaped bony plate on falx close adherent to right side. Nothing abnormal about the base, or in substance

17/4/79

C IV Found Kidneys. Pregnancy - Album - Coma -
9. - aged. 10th pregnancy

l. 12 am. of the 16th. Post mortem 3.30 PM. of 17th.
e greatly discoloured, black and swollen, a quantity of foul smelling
d orges from the mouth. Skin of chest and upper extremities
ent black - veins deeply marked. Entire trunk swollen
sub-cutaneous emphysema. Large bulla about nipples.
bdomen much distended. On making preliminary incision
ch gas escaped from skin - - muscles very flabby & soft. In abdomen
erperitic greatly distended - not discoloured - no fluid in peritoneum
embrane quite clear. In thorax a few adhesions on left side
small quantity of dark fluid in pericardium, gas beneath the
ceral layer. In Rt. chamber dark fluid blood and clots
ardium dilated. valves normal. Left ventricle empty
ft. appears dilated walls decidedly hypertrophied. valves
althy, endocardium not stained
~~Lungs~~ healthy. Splen large & soft. Kidneys gas beneath
capsules in part, in places capsule adherent & tears the
bstance on removal, surface granular, pitted & several
all cysts can be seen. On section it is difficult to distinguish
tting on account of the advanced state of decomposition
rtices look coarse, & the base of the pyramids are much
ined. They cut with resistance in spite of the emphysema

ature range 99 - 102°7.

(Signed) Allen Bell

- lymph,
gelatinous looking
from surface
in a state of
ver lobe is in a
l =

Liver excessively soft, emphysematous cracks as if it had been boiled. It appears of normal size. Nothing abnormal in Stomach and intestines

Uterus relaxed & fills the entire pelvis. On removal it is like a large hyperdistended bladder, walls about 3/4 of an inch thick. Inside numerous clots & shreds of decidua. The site of the placenta is well marked at the fundus and is covered with adherent clots & decidual membrane. The latter coating of membrane over the muscle can be removed with slight scraping. The Fallopian tube towards the outer end are dilated with air. It is very much flattened & soft. Left contains a corpus luteum

Brain of good consistence. Vessels moderately full. No special signs of decomposition. On careful section nothing abnormal discovered. Nothing noticeable in the cranial cavity of cervical region so far as it could be traced.

19/4/79

20

Montreal General Hospital.

MEMORANDA FOR THE PATHOLOGIST.

Case CCGV. Miner's Lung

Name John Nescott Age 60

Date of entry April 16th Date of death April 19th 79

Brief History. Miner most of his life in lead & copper mines. History of Pleurisy several months ago Rt side followed by Cough & failing health.

Chief Symptoms Cough dyspnoea & loss of flesh & strength – little Expectoration. Dulness & feeble breathing with a few moist sounds over Rt Lung.

Temperature range 98 – 99.5

(Signed) James Bell

---

l nourished.
re is an
ch a few
the pelvis
ewhat more
la.
ive inches

he middle line,
much adhe~~ren~~
uid.
d blood
ed. In
blood
d the veins
ventricle.

persist,
in circumfe-
hypertrophied,
ranging to
ex, 6 Inches, Circumference about the
entre 7 Inches, muscular substance, consi-
derably hypertrophied over posterior wall
about the middle measures 7 mm.

ra cloudy covered
lymph,
gelatinous looking
from surface
in a state of
ver lobe is in a
l=

---

ature range 99 – 102°7.

(Signed) James Bell

Liver excessively soft, emphysematous cracks as if it had been boiled. It appears of normal size. Rolling apart in stomach and intestines

Uterus relaxed & fills the entire pelvis. On removal it like a large hyperinflated bladder, walls about 3/4- in thickness. Inside numerous clots & shreds of decidua. The site of the placenta is well marked at the fundus and is covered with adherent clots & decidual membrane. The thin cooking membrane over the muscle can be removed with slight scraping. The Fallopian tube towards the outer end are dilated with air. Rt ovary much shrunken & soft. Left contains a corpus luteum

Brain of good consistence. Vessels moderately full. No signs of decomposition. On careful section nothing abnormal discovered. Nothing noticeable in the dural sinuses of cervical region so far as it could be traced.

CV Miners Lung 19/4/79

Tricott

eral appearance. Body that of a fairly well nourished.
gor Mortis present. In abdomen, there is an
creased amount of serum in which a few
agula of lymph, about 10 oz. in all. In the pelvis
re is about a table spoonful, somewhat more
l clear gelatinous looking coagula.
iver much depressed extending five inches
elow the ribs in the Mammary line.
thorax, left lung extends well over to the middle line,
adhesions, Right lung, pleura very much adhe
ent. In Pericardium, 2 or 3 oz. clear fluid.
Right auricle distended with clots and blood
perficial parts of the clots, decolorized. In
ight ventricle, ~~blood~~ over 20 oz. of blood
capes from the Right Chambers and the veins
ft auricle, contains clots. Left ventricle.
mall clots attached to the valves.
ight auricle, large. Eustachian valve persist,
icuspid orifice, very large, over 6 inch. in circumfe-
nce. Right ventricle dilated and hypertrophied,
hamber measures from pulmonary ring to
ex, 6 Inches, Circumference about the
ntre 7 Inches, Muscular substance, consi-
derably hypertrophied over posterior wall
bout the middle measures 7 mm.

ature range 99 – 102°7.

Signed) J Muskell

ra cloudy covered
lymph,
gelatinous looking
from surface
in a state of
er lobe is in a
l=

Heart. Weight 4 4 5 grammes.
Anterior wall, Coms 6 mm.
Left Ventricle appears of normal size,
length of Rt. 6½ centimetres. Valves Normal.
Mitral orifice not dilated, 5 inch. in circumf
Lungs. Left lung crepitant throughout
the anterior lower portions, Pleura
Covering the entire lung is dark & in some
uniformly so, at the posterior surface, the
a thickened opaque white mass. Upper l
In the greater part of its extent, emphysematous
In feeling it, there are a number of small
Shotty bodies, these, on section are seen t
small, fenced, fibroid areas excessively
pigmented, except in these regions and ab
the vessels and bronchi there is not a
great excess of Carbonaceous matter
The colour of the tissue somewhat sla
gray. Posterior part of the lung extendi
through both lobes and for a distance 18
in length and from 4 to 5 in depth, the lu
is converted into firm fibroid tissue o
Inky blackness. In parts of this it is begi
to break down, Irregular small spaces wi
very irregular Jagged walls being seen
throughout. Bronchial tubes contain a
quantity of dirty secretion, Mucous
membrane thickened.
Right Lung. Pleural surfaces universa
adherent and greatly thickened, over the

ter part of its extend the peritoneum covers and immediately
es commences it in all directions. Anteriorly it is smooth
and, mapped out by superficial irregular purple into angular masses
ayish white colour. Posteriorly and to the right there is a deep
ow corresponding to the attachment of the spine. At the lower
of the mass the tissue looks of a reddish brown colour and
a section there is a thin layer of renal substance, scarcely
than 1/8 in thickness, immediately below which there is soft
ullary matter. At the inner border close to the vertebral
the aorta and inf. V. cava. The former is closely connected
the growth but not very. The renal artery, of same size as right
crates the mass, and two smaller vessels - one above, the
below, pass to it. The inf. V. cava is of normal size up to the
al vein. about 1½" above the iliacs a vein the size of the latter
r. enters from the kidney & is distended with a greyish white
tus which projects into the lumen of the inf. cava 10 m. The
vein is of enormous size measuring 10.5. cm in circumference.
can be traced for. 12 cm along the inner border of the tumour
ing there branches in its course. All these veins with the
ion of the one from the supra-renal are distended with cancerous
ter. The mass in the renal vein is greyish white in colour
adherent to the wall, this, in close apposition but a probe can
easily passed beneath the wall as far as the branches in which
adherence is close. The thrombus projects from the vein into the
vena cava up which it passes for a distance of 8 cm nearly
the diaphragm. It also is very adherent, and a space exists
h the blood could readily pass, but the cava is here a good

ature range 99 - 102°7.

Signed) Allen Bell

- lymph,
gelatinous looking
from surface
in a state of
ver lobe is in a

deal distended measuring 8.5 ctm in circumference
The thrombus ends in a tapering rough bifid extremity, to one end th
is some shreddy fibrin adherent. Passing down by the
of the left iliac for some distance is a distended tube filled w
soft material. This probably represents the ureter, but unf
tunately its prolongation toward the bladder was not traced
The wall was thin & above it extend directly into the m
On the posterior surface there is large coiled vein, 14 ctm
in length which passed toward the hilus, increasing ~~greatly~~ in its
course to the ~~—~~ size of the little finger, It has a reddish white colour fr
being filled with cancerous masses. On the same surfa
are several smaller ~~mass~~ veins presenting a similar
appearance. At the upper and anterior angle the
suprarenal capsule is seen, greatly stretched & flatten
measuring 12 ~~ctm~~ by 8. ctm. It is readily separated, not be
involved; its vein is free & empties into the renal.
The pancreas is elongated and flattened, but otherwise
normal. One retroperitoneal gland in the neighborhood
of the aorta appeared affected, but none of the other abd
lymph glands were involved.
Heart normal. amount of blood much reduced.
Lungs not adherent. Posteriorly, numerous small can
nodules ranging in size from a pea to large marble, chie
in lower lobes, ~~but~~ very abundant. Only ~~one or two~~ a few in an
front. Spleen flattened & adherent to tumour, otherwise
natural looking, though soft.
Rt. Kidney, of full size, tissue a little coarse looking but

29/4/79

VII General Tuberculosis. Corrosive Sublimate Poison. Atrophy of the Kidney.

P.M. 26 hours after death.

C. patient of Dr Cameron's — girl at 11 — ill with Tub. Meningitis. By mistake of chemist a powder of corr. sub. 1gr. instead of calomel. The symptoms were vomiting convulsions. . . and the death was attributed to the action of the medicine. The following viscera were submitted to me for inspection. ~~Oe~~Oesophagus. M.M. uninflamed & looks natural, about middle of posterior wall is a small ulceration about size of small split pea; does not look as if caused by the poison. Stomach M.M. covered with a yellowish mucus. On scraping this away, membrane is pale, large vessels here & there full. No ulceration or inflammation. A curious appearance is given to the membrane by the presence of numerous sub-mucous air blebs — many of which were large & occupied a large extent of the membrane. No signs of decomposition about the organ. In duodenum there were also several of these emphysematous spots.

Kidneys Rt. is reduced to the condition of a small irregular mass weighing 12 grms & wholly unrecognizable as a kidney. The left is large weighing 113 grms. & looks as large as a kidney from an adult.

ature range 99 - 102°7.

Signed)

nd closely covered
lymph,
gelatinous looking
from surface
in a state of
er lobe is in a

28/4/79

CCCVIII Pleuro-Pneumonia

Body of well nourished man - average sized -
panniculus adiposus well nourished. In Abdom
Sigmoid & colon much distended - coils reaches ab
umbil. - Rectum descends right side. Liver pale a
lower border 3 fingers below ribs. On raising Sternum
Lymph covers ant marg in left lung. In Pericard
a normal amt of fluid. On parietal layer, next R
lung copious deposit yell lymph. In right Pleura
about ℥xx sero-purul ~~fluid~~ fluid. Right Auricle
clots & fld blood. In right Vent columnae
adherent to valve. Left Auricle conts grumous
On removing Heart ℥viii blood escapes. Right
Vent not dilated. Tricusp orif 5 inches circumf -
healthy - Pulm & semi-lunar v. fenestrated. Left
Vent normal - Mitral orif 4 1/3 inches circumf -
muscle substance healthy looking - few patches
of atheroma in Aorta. Heart weighs 330 grs.
Right Pleura - visceral & parietal layers cover
with thick layer of lymph - most abundant
lower lobe & posterior part of upper lobe

Right Lung 690 grammes - croupt upper & middle lobes & upper
of lower lobe. On section upper & mid Lobe quite
dry - no oedema - lower Lobe is collapsed at post
& upper regions & in these parts & also ant border
it can be dilated - in central & external portions
does not dilate. On section in condition of red hepatiz
airless, section dry, granular. vessels & tubes free.

weight
Left Lung -
extent - extensive
section -
lobe in same
On section
in condit. of
almost entire
Spleen -
Kidneys
smooth -
hadin pale -
Abscess of pyr
marked,
Stomach
mucous memb
Common Bile
Liver, 2485 grammes
covered with
Intestines -
Brain -

---

(1)

Montreal General Hospital.

MEMORANDA FOR THE PATHOLOGIST.

Case Pneumonia CCCVIII

Name E. R. Trowbridge Age 37

Date of entry Apl 26th Date of death Apl 27th 79 11 a.m.

Brief History - Hard drinker. Illness began in a drinking bout - on 21st Inst.

Chief Symptoms. Fever. Pain in rt. side cough rusty sputa. Mild excited delirium - Dulness bronchial breathing increased v. resonance & fremitus over rt back. - Evident pain & tenderness & tympanitic distension of abdomen

Temperature range 100 - 102° 7.

(Signed) James Bell

---

ature range 99 - 102° 7.

Signed) James Bell

---

d closely covered
lymph,
gelatinous looking
from surface
in a state of
er lobe is in a

28/4/79

CCCVIII Pleuro-Pneumonia

Body of well nourished man - average size - panniculus adiposus well nourished. In Abdomen Inguinal & lumbar nodes disturbed - cut reveals a umbil - Rectum discards right side. Liver pale - lower border 3 fingers below ribs. On serous Membranes Lymph coverings ant many in left lung. In Pericardium a normal ant of fluid. On Parietal layer, ant Pleura lung capsule deposit yellow lymph. In right Pleura about 3xx ozs - purulent fluid. Right Auricle clots & old blood. In right Vent columnar adherent to valve. Left Auricle ant gruman On opening Heart 3viii blood escapes. Right Vent not dilated. Trunk circ 5 inches circumf - healthy - Pulm & semi-lunar V- pentroded. Left Vent normal - Mitr circ 4 1/2 inches circumf - muscle substance healthy looking - few patches of atheroma in Aorta. Heart weighs 330 grs. Right Pleura - Visceral & parietal layers covered with thick layer of lymph - most abundant lower lobes - & Posterior part of upper lobes

Right Lung 690 grammes - Apical upper & middle lobes & upper of lower lobes. On Section upper & mid Lobes quite dry - No redness - lower Lobes is collapsed at post & upper regions & in central part & also ant border it can be dilated - in central & External Portions does not dilate. On Section, no condition of red hepatization airless, section dry, granular, vessels & tubes plt.

weight 600 grammes

ft Lung – Upper & lower lobes divided to unusual
xtent – fissure extending to Bronchi – Upper lobe crepit in Ant
Sections – Posterior heavy & slightly crepit. Entire lower
lobe in same state. Pleura very moist & dripping.
n Section tissue presents sodden oedematous appearance
in condit of acute oedema – quantities of frothy & clear fluid flowing from section – Ant borders are dry –
almost entire lower lobe in same condition.

pleen – very soft – pulp dark purplish brown

idneys Right – 210 grammes Capsule detach readily – Surface Left 200 grammes.
smooth – pale – on Section cortex anaemic – Malpigh
radii pale – small groups of vessels seen passing from
bases of pyramid – but pale and indistinct – Pyramid
unmarked, vessels full – Organs are evidently fatty, especially at cortex

tomach conts a quart of dark brownish matter –
ucous memb pale & very thin & soft ~~from~~ p. m solution –
patic common Bile-duct pervious.

30 gr Liver, 2485 grammes. very large – very pale, soft, friable – On Section
cuts with consid firmness & does not tear easily – organ very fatty

ntestines – normal. –

Brain – normal. Convolutions distinct – sulci deep

ature range 99 – 102°7.

Signed)

and closely covered
lymph,
gelatinous looking
from surface
in a state of
er lobe is in a
l=

27/4/99

CCC IX. Contracted Kidneys - extreme anaemia

Body of an average-sized moderately well nourished ~~emaci~~ man. Pann adip well develop. Skin exceedingly anaemic. Over front chest very superf, faintly marked area of pigmentation. On [illegible] [illegible] diseased right side - otherwise norm Small amt serous effus in each pleural sac. no adhesions.

Heart - Right Aur full with large clot - c gelat-looking above. Right Vent conts small w clot - Right Aur large - dilated - tri-cusp ori 6 inches circumf - Valves normal - Pulm semil fenestrated in every segment. Right Vent - dilated length 4 inches Left Aur natural - Left Ve hypertr - ant wall near septum 7/8 in thick post wall central portion 5/8 inch. Length Ch 4 1/2 inches. Mitral Valve normal - Mitral Orif 4 1/ Aort semi-lun valve a little thickened espec corp Arantii - 2 segments fenestrated. Muscle very pale.

Right Lung - only slightly congest particularly behind. Poster p of lung is oedematous. Ant part normal. Left Lung same state - quantities of fluid ooze from section

Spleen - Normal size - pulp soft - [illegible]

Left Kidney 90 grammes - small - capsule adherent - Sur is granular & irreg - projections small, no cysts - On sec larger vessels in cortex are injected - arteri bases of pyramids moderately prominent - pyramids pale

Right Kidney 113 grammes. same condition as left

Stomach conts quant of dark acid fluid - muc coat very

(2)

Montreal General Hospital.

MEMORANDA FOR THE PATHOLOGIST.

CCCIX

Case Anaemia. ~~Hypert.~~ Cordis & Cirrh. Hepatis,

Name Alexander Morris Age 32

Date of entry Mch 18th 79 Date of death April 27th 79 10 P.m.

Brief History Illness of 2 years standing began c what he called dysentery - bloody stools &c. Very hard drinker

Chief Symptoms repeated Haemorrhages from lower bowel. Double aortic murmur - lately murmurs heard in neck & mitral murmur as well (Systolic) Death from grad. asthenia. 32% red corp. albuminuria

Temperature range - normal until last few weeks - since then - 98 - 103°.7.

(Signed) James Bell

---

d is
mon
stained
tests norm

l normal
, vessels

les and

sign of
t. It is
ous.

---

ature range 99 - 102°.7.

Signed) James Bell

---

ra cloudy covered
r lymph,
gelatinous looking
from surface
in a state of
er lobe is in a
l =

28/4/9

CCCIX. Contracted Kidneys - extreme anaemia

Body of an average-sized - moderately ~~emaci~~ well nourished man. Panni adip well develop. Skin exceedingly anaemic. Over front chest very superf, faintly marked area of pigmentation. On [illegible] [illegible] [illegible] descends right side - otherwise norm

Small amt serous effusion in each pleural sac no adhesions.

Heart - Right Aur full with large clot - c gelat-looking above. Right Vent conts small w clot - Right Aur large - dilated - tri-cusp an 6 inches circumf - Valves normal - Pulm semilun fenestrated in every segment. Right Vent - dilated length 4 inches Left Aur natural - Left V hypertroph - ant wall near septum 7/8 in thick post wall central portion 5/8 inch. Length ch 4 1/2 inches. Mitral valve normal - Mitral circf 4 1/ Aort semi-lun valve a little thickened expe corp Arantii - 2 segments fenestrated. Muscle very pale.

Right Lung - only slightly congest particularly behind. Poster of lung is oedematous. Ant part normal. Left Lung same state - quantities of fluid ooze from section

Spleen - normal size - pulp soft - [illegible]

Left Kidney 90 grammes - small - capsule adherent - Su is granular, irreg - projections small, no cysts - On se larger vessels in cortex are injected - arteri bases of pyramids moderately prominent - pyramids pal

Right Kidney 113 grammes. same condition as left

Stomach conts quant of dark acid fluid - muc coat

thin – almost dissolved off – Pyloric end is mammillated – Muc. very prominent & large. Duodenum normal. Common bile-duct pervious. Jejunum conts bile stained mucus – extending thro' ileum – small intestine normal. Peyers glands not enlarged.

Large Intestine cont. scybala – mucous memb. normal not injected until close to anus where vessels are full. Close to anus, large dilated vein ~~filled~~ ~~with~~ ~~thrombus~~

Liver 1620 grammes – central veins of lobules are injected – rest of lobules pale

evidently filled with a thrombus. It forms a mass the size of a cherry of a dark red colour, & has two veins leading to it. It is situated just within the int sphincter & forms a firm mass.

…ature range 99 – 102°7.

(Signed)

…sely covered

… lymph,

… jelatinous looking

… from surface

… in a state of

…er lobe is in a

…l=

rature range 99 – 102°7.

(Signed) Albert Ball

ra cloudy covered
– lymph,
gelatinous looking
from surface
in a state of
ver lobe is in a
/=

rature range 99 – 102°F.

(Signed) Allen Bell

ra Cloudy covered
lymph,
gelatinous looking
from surface
in a state of
ver lobe is in a

Montreal General Hospital.

MEMORANDA FOR THE PATHOLOGIST.

Case

Name Emily Dubue Age 48

Date of entry Sept 3rd 74 Date of death Dec. 18th 74 4 am.

Brief History

Stony Family tendency to tubercular disease

Chief Symptoms

Weakness. Loss of flesh - Nausea
tenesmus & diarrhoea all. Epileptiform convulsions
final loss of intellect with suicidal tendency.
Coma & death

Temperature range

98 — 103.7.
Temp only rose daily

(Signed) J Munro Bell

Probably undetermined

Montreal General Hospital.

MEMORANDA FOR THE PATHOLOGIST.

Case Phthisis

Name Ellen Mannyford Age 26

Date of entry Oct 1st 79 Date of death Decembr 24th 79
7.15 Am

Brief History

Chief Symptoms
Cough Expectoration Wasting
Night sweats &c

Temperature range
98 - 104° F.

(Signed) J Allan Bell

rature range 99 - 102° F.

(Signed) J Allan Bell

ra Cloudy covered
lymph,
gelatinous looking
from surface
in a state of
ver lobe is in a

Montreal General Hospital

PATHOLOGISTS NOTICE.

Harriet Hornet æt 36 died

on August 30th 1880

~~Brief~~ History: of Phthisis lasting over

about two years —

Chief Symtoms: night sweats - emaciation

Cough - aphonia - Diarrhoea —

Diagnosis: Phthisis Pulmonalis

30/10/80 - A. B. Turcot

House Surgeon.

The friends are anxious to remove

the body at three today P.M.

Montreal General Hospital.

MEMORANDA FOR THE PATHOLOGIST.

Case Chr Nephritis —

Name John Sweeney Age 60

Date of entry 26th Date of death 28th

Brief History. Good family history. Hard drinker up to 10 years since Bronchitis 15 & 3 years ago — General dropsy three months ago — disappeared almost entirely returning two months ago —

Chief Symptoms — Anasarca — General cyanosis

---

ters alteren

rature range 99 - 102°F.

(Signed)

---

ra Cloudy covered

lymph,

gelatinous looking

from surface

in a state of

er lobe is in a

l =

Tumour of Ovary –
17th Appendix with pin in.
Head of Tapeworm.

Plain cell. Sarc of leg.
Cancer of B. – 2 –
Embryo.

24th Heart disease –
Phthisis – Amyloid deg.
Pur. Meningitis

31st.
(1) Phthisis – haem. pr an.
2 Phth. Pneumonia
3 Phth. – x. Tub peritonitis
4 Lipoma.

7th
Medico legal case.
8 Pneumonia. Gallstones

14th. Child – [illegible]
" D.T.'s
. Phthisis – – Empyema –
Fract. Ribs – Haemothorax – Gang of lu
Cancer of liver
21st – Heart disease. soft of brain 53
52 (2) Typhoid Fever
3 Heart. [illegible] – lung. 54

---

tters determ

rature range 99 – 102° F.

(Signed)

James Bell

---

ra Cloudy covered
lymph,
gelatinous looking
from surface
in a state of
er lobe is in a
l –

28th Phthisis - 55

Adherent Pericardium - 56

Placenta - & fee

Placenta & Fatus

Orbicular. Colpitis 57

March 6th

Pneumonia 58

13th

Tumour of Thyroid

Ovarian Tumour

Hart. disease

20th.

Opthth. endocard.

Murmurs Mitral

Typhoid Fever.

127	"	"	nil
128	"	"	very slight ulceration
138	"	"	nil
139	"	"	nil. very slight ulceration
143	"	"	nil.
174	"	"	nil
228	"	"	nil.
230	"	"	nil.
234	"	"	nil
288	,..		– ulcerating

tters determ

ature range 99 – 102°7.

(Signed) James Bell

fall

ra Cloudy covered

lymph,

gelatinous looking

from surface

in a state of

er lobe is in a

=

Diseases of Stomach & Intestines

126. Colitis ulcerativa (swelling -
146 Cancer of Stomach - perforation
149. Stab of bowel.
162 Ulcerative Colitis — 2. mo ant.
169 Duodenal ulcer.
172 Can of Oesoph.
183 Haemorrhoids. Leplicemia
188 Duodenal ulcer
190 Ch. Intes. Catarrh
236. Forg. body in Oesoph.
247. Ulcer of Stomach
248 Ulcer of Stomach
249 Colitis ulcerativa — mg. d.
264 Can of Stomach
274 Round ulcer. Pil of Stomach
281 Can of Stomach.
291 Can of Stomach

Diseases of Kidney.

132. Tub. Nephritis
144 Morb. Brigh. Chr. – œdema of Lungs
170 Ch. Morb. Brighti – no rept.
183. Ch. " " " no good.
184 Inter. Neph. not special.
196 Morb. Brighti – Fatty Kidney.
246. Morb. Brighti – & Hyp. card. of [illegible] Ross.
265 – Sup. Nephritis
275 – Sup. Neph. Perineph. abscess. – ? wt.
283. Cirrhosis of Kidney. –
287. Cirrho of Kidney. –
294 Cancer of Kidney.

Bladder & Prost

133 Calculus
140 Calculus
265 – Cystitis
275 – Enl. Prostate

Generative Organs

134 Recto Vag. fist. Absc. of Lig. lat.
152 Cancer of Uterus
164 Poly. Ut. . absc. in Lig. lat. – good case.
198 Ut. phleb. Phleg. alb. dol.
207. Ut. myoma
231 Can. of Uterus – wider case
243. Ext. Ut. foetation
249. Dermoid of Ovary
260 Extra Ut. pregnancy.

---

tters deleterious

ature range 99 – 102°7.

Signed) James Bell

---

of very solid, full
ra Cloudy covered
lymph,
gelatinous looking
from surface
in a state of
ver lobe is in a
d=

Diphtheria

~~104~~	"	"	nil
110	at 10 m"	"	No ment in trachea. Lung & pharynx
131	at 8. "	"	" " "
136	at 6 Trach.	"	Ext. in Trachea, bronchi
137	"	"	Ext in Trachea & bronchi
191	"	"	Ext in trachea & bronchi
192	"	"	" In bronchi.
211	"	"	To bronchi if 3rd or 4th dimension
~~214~~	"	"	nil
~~215~~	"	"	
235	"	"	Tuberculosis
237			No affection
257			Not in trachea
269			Fatty lent.
295	"	"	Ment in trachea
290			Ment in Tr & L

...ders determine

...erature range 99 – 102° F.

(Signed) Allen Kell

...ra Cloudy covered
... lymph,
... gelatinous looking
... from surface
... in a state of
...er lobe is in a
...=

CX

Pneumonia

Body. that of an elderly, so moderately well nourished woman

In abdomen Gall bladder prominent & extends long way below margin of ribs

In Thorax few adhesions posteriorly, 4 or 5 oz turbid fluid in right pleura

Nothing abnormal about Pericardium

Right auricle distended with a large gelatinous clot which has prolongations into the veins,

In left auricle also a large gelatinous clot- 6 oz of blood &

tricle

es 5 1/2 inches in circumfe

gment of semi-

9 C.C.M.

normal bases of

Calcareous, two

base of anterior

C.C.M. Ord. Circum-

circumference

ment of aortic

ed

uniformly solid, pull

ra Cloudy covered

lymph,

gelatinous looking

from surface

in a state of

er lobe is in a

=

CCCX

Montreal General Hospital.

MEMORANDA FOR THE PATHOLOGIST.

Case Pneumonia

Name Elizabeth Collum Age 64

Date of entry May 5th 74 Date of death May 18th 74

Brief History unknown

Chief Symptoms Rigor. Stitch in R. side Cough with Expectoration. Dyspnoea Restless delirium

Temperature range 99 - 102°7.

(Signed) Allen Kell

CX

Pneumonia

Body that of an elderly, ~~so~~ moderately well nourished woman

~~In~~ In abdomen Gall bladder prominent x extends long way below margin of ribs

In thorax few adhesions posteriorly, 4 or 5 3 turbid fluid in right pleura

Nothing abnormal about pericardium

Right auricle distended with a large gelatinous clot which has prolongations into the veins,

In left auricle also a large gelatinous clot

On removal of Heart about 6 oz of blood & ~~A~~ clots escaped.

Nothing special about ventricle

Tricuspid orifice measures 5 1/8 inches in circumference

Valves normal one segment of semi-lunar penetrated

Length of Right Vent. 9 C.C.M.

Left Ventricle, Valves normal bases of semilunar firm one calcareous, two spots of atheroma at base of anterior segment of Mitral

Length of left Vent. 7 1/2 C.C.M. Mitral Circumference 11 C.C.M.

Mitral orifice 4 1/2 inches in circumference

Valves normal one segment of aortic semilunar penetrated

Right Lung lower lobe uniformly solid, full in volume firm, Pleura Cloudy covered with a slight layer of lymph,

on section upper lobe gelatinous looking quantity of serum oozes from surface lower part is solid & in a state of hepatization, entire lower lobe is in a condition of Grey Hepatization

the surface section anemic bathed with a
purulent fluid, granular,
The whole of the lobe is in this condition, esp
anterior border of the upper & middle lobe
dry
Bronchial tubes filled with a frothy seru
not filled with coagulum, mucous mem
much injected
Left Lung crepitant throughout; emphy
zematous, lower lobe has a gelatinous ap
-ance in parts, the oedema is very in
in the whole of this lower lobe with ex
the extreme upper margin
Upper lobe, oedematous, in dependent pa
dry in the other regions
Right lungs weighs 1223 grams
Left Lung 410 grams
Spleen firm, natural looking weighs 12½
Kidneys, Left Capsules detach readily Cortex
pale coarse looking malphegian bodies
faint looking
Right Kidney a little more injected weighs
Stomach Presents nothing Special
Large intestines nothing Special
Liver Small natural looking
Uteris nothing Special
Ovaries in condition of senile atrophy
Brain nothing Special on superficial examin

CCCXI

Syphilis of Rectum Albuminuria

Body that of a well formed young old woman fairly
well nourished. In abdomen Position of viscera
normal. A few ℥ of serum in peritoneum
In thorax fluid in right pleura, small amount
A few adhesions posteriorly. Adhesions more
numerous on left side. In right auricle clots
right vent. a leathery
valves and extending
left auricle also
almost empty
on removal
2 20 grammes
right chamber of the
ment of semilunar
i.e. a little from the
mitral valve normal.
wall. Two seg-
ifice measures nearly
Ant. wall 15 MM
Length of left
chamber of the
post. & lateral part
mph
at extreme
of its extent
s. Ant. border of
solid part
arance in places
spots becoming
of a reddish
partially purulent serum. The Bronchial
tubes are not occluded nor are the vessels
filled with thrombi — The remainder of lung in
Moderate state of Edema. Ant. border
& lower pt. collapsed.

CCXI

Montreal General Hospital.

MEMORANDA FOR THE PATHOLOGIST.

Case Albuminuria

Name Marie Benoit Age 25

Date of entry April 12th. Date of death May 7th. 7.55 P.M.

Brief History Disordered Menstruation for last 3 or 4 years — Irregular & often absent for months

Chief Symptoms. Slight oedema of feet & legs about 1st of April. No other Symptoms complained of — Anaemia albuminuria Ulceration of throat within last 3 weeks

Temperature range 98° — 103° — irregular

(Signed) James Bell

the surface section anemic bathed with a
purulent fluid, granular,
The whole of the lobe is in this condition, esp
anterior border of the upper & middle lobe
dry
Bronchial tubes filled with a frothy serum
not fille
much
Left Lung
genations,
ance in
in the
the ep tre
Upper lo
dry in
Right
Left Lung
Spleen fi
Kidneys, Le
Pale co
Faint loo
Right Kid
Stomach
Large intest
Liver Small
Uteris nothin
Ovaries in
Brain nothi

CCCXI

Syphilis of Renin Albuminuria

Body that of a well formed young woman fairly well nourished. In abdomen Position of viscera normal. A few ℥ss of serum in peritoneum In Thorax fluid in right pleura, small amount. A few adhesions posteriorly. Adhesions more numerous on left side. In right auricle clot which is appendix In right vent. a leathery decolorized clot adherent to the valves and extending into the pulmonary artery. Left auricle also full of clot. Left ventricle almost empty Amount of blood which escaped on removal of heart is ℥6 Wt. of heart 2 2/3 pounds

Nothing special about the right chambers of the heart. Valves healthy. One segment of semilunar fenestrated. Tricuspid orifice a little over 4½ inches in circumference. Mitral valve normal. Aortic semilunar valves look small. Two segments fenestrated. Mitral orifice measures nearly 4½ inches in circumference. Ant. wall 15 MM in thickness Post wall same. Length of left chamber 7 cm. Right chamber 9 cm

R. Lung Pleura covering the post. & lateral part of upper lobe covered with lymph

Upper lobe only slightly crepitant at extreme apex and ant. border. In the rest of its extent it is firm solid and airless. Ant. border of middle lobe collapsed

On section of upper lobe the solid part presents a mottled appearance in places reddish in color in others spots becoming gray. A very moderate amt. of a reddish partially purulent serum. The Bronchial tubes are not occluded nor are the vessels filled with thrombi — The remainder of lung in Moderate state of edema. Ant. border & lower pt. collapsed.

Left lung crepitant throughout & denser
in posterior regions. — Spleen + moderately
firm, pulp natural looking, weight 130 grms.
Left Kidney, wt. 230 grammes. right same.
Organs large; capsules detached without
much difficulty; surfaces smooth & pale:
on sect., organs firm, solid, cuticle portion
very anemic, open Malpig. bodies are injected.
The great majority of " " can be seen
as clear translucent structures: here & there
throughout cuticle regions are open & opaque
white patches of fatty degeneration. The pyramids
are deeply injected, pearly appearance at
& the base of the cuticle portion.
On applic. of iodine, the Malpig bodies remain
stain pale deep brown almost black in color.
Stomach, contains a quantity of 1/2 digested
food. The mucous membrane at Cardiac end
nothing special about duodenum; the duodenal
pervious: portal vein admits the little
finger.
Liver wt. 1450 grammes
Bladder Rectum Uterus removed together
Blad. normal; Uterus natural; Ovaries
firm, no corpora lutea, in centre of
left one a cicatricial spot of bright
vermilion color. Anterior wall of Rectum
in Douglas's fossa, presents some pinkish
brown bands on account of peritoneum.

CCXII Descending sclerosis of cord. May 10. 79

dy that of old & somewhat emaciated man. Slight
ma feet & ankles. On opening the abd, liver projects
r fingers breadths below costal border. In thorax
pleura clear serum in right sack 40 ozs. In left
ng posteriorly.
t looks large
in clots - few
m in left aur.
t clot.
½ in circumf. Right
centimeters, valve
trabeculae prominent
tricle chamber
d, mitral valves norm
t competent - an
length of left
ft ventr. - at centre
13 millimetres -
- Arch of aorta
with opaque white
nt
roughout - emphysem
- slightly crepitant,
l fluid bathes surf
wer lobe fluid
sultant. Apices
rder is emphysemal
ckered, pulp firm
ft. small - firm
irregular - cortex
not much reduced. Right, capsule not so readily
detached - surf more irregular - small vess quite
distinct. Liver surf slightly puckered - cuts firmly
lobules distinctly marked - peripheral parts dar
colored from filling of b. vessels - central part pale
weight 1180 grammes.

CCXII

Montreal General Hospital.

MEMORANDA FOR THE PATHOLOGIST.

Case Senility

Name Robert Akin Age 78

Date of entry Dec 27th Date of death May 9th 79 9.30 a.m.

Brief History Injury to head 25 years ago struck by a locomotive. Rt Hemiplegia 18 months ago. Admitted for asthma

Chief Symptoms asthma (spasmodic) recovery in 4 months. Imbecility: no other Symps. — Pretty good recovery from hemiplegia no aphasia

Temperature range — 98½ —

(Signed) James Bell M.D.

Left lung crepitant throughout, Edematous
in posterior regions. — Spleen — moderately
firm, pulp natural looking, weight 130 grammes
Left Kidney, wt. 230 grammes, right same.
Organ large
much difficulty
on sect., organ
very anemic,
the great major
a clear trans
throughout cont
white patches
are deeply in
to the point of
On applic. of iod
stain of a deep bro
Stomach
food. The mucous
Nothing special
pervious.
finger
Bladder Rec
Blad. normal
firm, no c
left one i
vermillion co
in Douglas's
fibrous bands

CCXII Descending Sclerosis of Cord. May 10. 79

dy that of old & somewhat Emaciated man. Slight
edema feet & ankles. On opening the abd, liver projects
o fingers breadths below costal border. In thorax
pleura clear serum in right sack 40 ozs. In left
ack. 14 ozs. Few adhesions in left lung posteriorally.
Pericard. Small amt. fluid. Heart looks large
n right Aur ℥ii dark blood in clots – In
ight Vent few dark clots – same in left aur.
n left Vent. moderate-sized soft clot.
ight Aur large. tricusp Orif 5½ in circumf Righ
ent dilated – length of chamber, 12 centimeters, Valve
ormal. Walls of Vent thick – trabeculae promin
ft Auricle – normal. Left Ventricle chamber
ilated – walls moderately thickened, mitr valves norm
ort orifice & valves are ~~compet~~ competent – are
hickened espec at free borders – length of left
Vent 9 centimeters. Circumf of left Vent – at centre
5 centimeters. Thickness of walls 13 Millimeters –
pices of papill muscles fibroid – Arch of aorta
tunica intima rough covered with opaque white
yell patches. Weight of Heart
ungs – Right Lung crepit throughout – emphysem
iddle lobe collapsed. Left Lung – slightly crepitant,
irm & heavy – on section quant of fluid bathes surf
upper lobe is clear & frothy – lower lobe fluid
hich exudes is bloody & semi purulent. Apices
both lungs puckered – ant border is emphysemat
leen – adherent to Diaph – puckered, pulp firm
weight 110 grammes Kidneys – Left. small – firm
apsule easily detached, surface irregular – cortex
ot much reduced. Right, capsule not so readily
detached – surf more irregular – small vess quite
distinct – Liver surf slightly puckered – cuts firmly
lobules distinctly marked – peripheral parts da
colored from filling of b. vessels – central part pale
weight 1180 grammes.

Peter O'Reilly æt 20. died April 12th
P M Sixteen hours after death
Body that of a well built-healthy looking
young man. Rigor Mortis well marked. In
abd nothing of special note. Pericardium normal
cont of fluid. A few ecchymoses on visceral &
parietal layers. Right-Auricle full of clots
yellowish coloured at upper portion. In Right
Ventricle is a partially discoloured clot-
In Left-Auricle dark clots. Left Ventricle
firmly contracted & empty. Amount of blood
which escaped on removal of heart 3x
Valves of the heart healthy. Two segments
of aortic semilunar fenestrated. Circumference
aspic. 6 1/3 inches in circumf. Mitral 4 1/2 inch
Œsophagus. Pharynx trachea & lungs removed
together. In the Pharynx the right- tonsil
pillars & the fauces & lateral wall of the
pharynx covered with a dirty greyish yellow
exudation. In Left- tonsil there is an old
cyst- full of yellowish fluid & cholesterine
crystals. Epiglottis swollen & covered with mem
on both upper & under surface. Right-Aryteno
epiglottidean fold & Aryteno epiglottidean fold thickened &
covered with membr. Left fold is hemorrhagic
as the epiglottis. The rima is uninvolved.
Trachea & bronchi very much injected. Mu
membrane much dirty mucus. Lungs upper
lobe of the right contains numerous spots
of apoplexy. Remainder of lung crepitant
& pink dead engorged post & larger vessels
full
Spleen much enlarged weighs 350 grammes
on section pulp dark red colour & of moderate
consistence

CCC1.

Brain is small, at the base vessels thick & Atheromatous, Good deal of serous fluid escaped in the removal of the organ, on removing the vessels from the base the Pons is seen to be much grooved, one longitudinal furrow corresponding to the artery, this in the middle portion is quite deep, the edges of this Groove are prominent & from them one or two small shallow grooves pass out on either side towards the Cerebellum.

The Sylvian fissure is wide, the membrane closing it in is opaque the vessels atheromatous

The under surface of Cerebellum there are two depressions the one on right lobe 2½ centimetres in length, by 4 or 5 in depth

brain Substance at the bottom is soft & has a slightly yellowish tinge

Hemispheres, on stripping of pia mater from left Hemisphere no cortical lesion

Convolutions firm, Sulci deep & ~~wide~~ wide,

Section through frontal Convolutions 5 c.c. Rn, in front of fissure of Rolando, Nihil

Section through Bases of frontal Convolutions nothing special noticeable,

Section through ascending frontal convolution nothing special noticeable

Section through

Kidneys abt normal in size. Cortices a
ittle course looking. Medul rays pale
alphig bodies distinct. ~~Nothin~~
Nothing abnormal about liver or abdomina
rgans

CCCXIII

DIH

CCCXIII

Montreal General Hospital.

MEMORANDA FOR THE PATHOLOGIST.

Case Phthisis

Name Mary Roderick Age 21

Date of entry April 26th Date of death May 16th

Brief History Illness extending over a (11 Mos.
year. - No previous illness. Family
history unknown

Chief Symptoms Cough Expectoration Fever
Night sweats Night pain Dyspnoea &
Loss of voice

Temperature range 102 - 105° F.

(Signed) James Bell

ug 21
sides. In Pericardium
auricle filled with
upper part.
and extending
auricle small
long axe which

ung abnormal
compressed
Mitral Aortic Semilunar
inches in diameter
Aorta 1/2 inch
183 grammes
lobe with exception
large cavity,
side of chest
dispersed with flattened
softened
-
two small cavities

regular cavity
terally -
tion of pneumonia
ung firm, airless and on section a surface salted
a large quantity of bloody serum - The whole
the lobe also contained numerous cheesy masses and
ds of softening -
16) Left Lung - Large cavity or opening occupying fully
rd of the lobe. Four lobe crepitant, contains only
few tubercles of caseous masses -
Larynx - Vocal cords ulcerated, roughened, particularly at
ir parts. Immediately above behind Sacculus an other
, deep ulceration involving bases of an extending beneath
ieoid cartilage -

CCCXIII

Phthisis

Body that of a small negro girl - age 21

Abdomen - Viscera adherent on both sides. No perceptible normal amount of fluid - Right auricle filled with a large firm clot discolored in upper part - In R. Ventricle a firm clot discolored and extending into pulmonary artery - In L Ventricle small fibrinous clot continuous with a long one which can be drawn out from aorta -

Heart - Right chambers project nothing abnormal Pericardium reflected 5 inches in circumference Pulmonic Semilunar valves fenestrated, Mitral & aortic Semilunar normal Walls of L.V. 11 Millimeters in diameter Length L.V. 65 Millim - Width of aorta 1/2 inch Aortic valves 55 Millim - Heart 183 Grammes

Lungs (a) Right - Almost whole upper lobe with exception of inferior border converted into a large cavity, with thin walls closely adherent to side of chest lining membrane dark in color interspersed with flattened caseous masses many of which are softened very few trabeculae cross the cavity -

Middle lobe contains one or two small cavities and a few caseous masses

Lower Lobe contains a large irregular cavity located about in upper part and laterally -

Lower part of lower lobe in a condition of pneumonia lung firm, airless and on section a surface baked a large quantity of bloody serum - The whole of this lobe also contains numerous cheesy masses and foci of softening -

(b) Left Lung - Large cavity of apex occupying fully 1/3 of the lobe. Lower lobe crepitant, contains only few tubercles & caseous masses -

Larynx - Vocal cords ulcerated, roughened, particularly at their posterior parts - Immediately above behind saccules an either side, deep ulcerations involving bases of arytenoid cartilages -

Trachea normal to within 1½ inches of bifurcation
at which point immediately above right bronchus
there is a spot of superficial ulceration 23 m metres by 15 m.m
The tissue about it injected and on outside of trachea
numerous small tubercles. Bronchial glands enlarged
soft not caseous? One of them is however caseous

Spleen. Small, capsule shrivelled. Weighs 80 grammes

Kidneys. Average size, Malpighian bodies Marked by
distinct.

Stomach. Injects along rugae. Mucus membrane
normal. Intestines. No tubercular ulcers to
be seen At lower part of ileum 3 or four small
polypi

Liver. Small. Left lobe much flattened and has
a broad prolongation backwards and to the left

Brain. Shows nothing abnormal

CCCXIV Martin. Phthisis

Phthisis

CCCXIV

Montreal General Hospital.

MEMORANDA FOR THE PATHOLOGIST.

Case

Name Hugh Martin Age 60

Date of entry May 13th Date of death May 23rd '79
7.15 P.m.

Brief History

Chief Symptoms Emaciation Cough foetid Expectoration Albuminuria &c

Temperature range

(Signed) James Bell

What hour & who are your clerks?

J.B.

---

ed, several cysts in apparent
On section cortices pale
translucency about any of the
lication of iodine. They become
cular vasa recta distinct. Also

al part of apex occupied by a large
compartment; not many
it. Ant part of apex infilt
s.
nature. Ant border & superfic
l of up lobe firm with num
ral of lower lobe – the lobe
. & also one place careful lung tissue
cles
to the touch. Small cavity
s, below which the lung tissue is
l the dist of these firm lobules
& firm. not softening. No cancer
deal of congestion.

on the patches not so numerous
ordent. In ileum & colon many large [illegible] ulcers. size of 10c – 25c piece have
ulcerated.
Liver granular – a firm band contour mass at ~~ant~~ border, size of [illegible]
Others normal.

CCCXIV Martin. Phthisis

Martin

Rt Kidney. 173 grms
Lf Kid 160

Capsules detach easily, surfaces smooth, mottled, several cysts in apparent size on left organ, one size of walnut at upper end. On section cortices pale a few small areas of greater opacity - no very special translucency about any of the parts. Malpig. bodies not very distinct. On application of iodine they become faintly stained of a mahog. brown. Pyramids more vascular vasa recta distinct. also but faintly on iodine. after

Lungs Left. Heavy. upper lobe. slightly crepitant. Post part of apex occupied by a large cavity, the size of ~~a~~ large orange - divided into several membranous compartments. not many trabeculae. Two or three br. tubes communicate with it. Ant part of apex infilt with innumerable mil. tubercles arranged in groups & giving a firm solid feel to the organ. a caseous mass at ext. apex the size of a walnut. Ant border & superfic part of ant. region emphysematous. Post part of up lobe firm with numerous tubercles of mil. & similar state in upper part of lower lobe - the tubercles are closely set a good deal of pigm & fib. tissue between. & also in places crepit lung tissue. Lower part of lung crepit. and contains only a few tubercles

Rt lung. up lobe firm but crepitant, resistant to the touch. Small cavity at apex. rest of apex infilt with innumerable tubercles, between which the lung tissue is crepitant. It is remarkable how uniform & general the dist of these firm tubercles is & yet how slight were the physical signs. all on hand & firm. not extensive. No caseous masses. Lower lobe few tubercles scattered & a good deal of congestion.

Heart. arch. val a little thickened at cusp aortic

Intestine. Numerous ulcers in sol glands of jej & ileum not in the patches which are in no... In caecum & colon many large ragged-edged ulcers. size of 10c - 25c piece. base thickened.

Liver fatty - a firm round caseous mass at ~~sal~~ border, size of filbert.

Others normal.

CCCXV

Kidney 105 gm

Spleen 210 gm. adherent to diaphragm Cap thickened opaque & covered with shreds of lymph. On section looks distinct pulp soft. natural colour.

Liver 663 grms. Length 18 ctm width rt lobe. 14. Closely attached to diaphragm. cap surf. thickly covered with flakes of lymph, which patches are recent. and tear off without much difficulty. Surface of organ then smooth, & semi opaque greyish white colour from thickening of capsule. Under surface cap not so thick & there are numerous granulations apparent part in left lobe & further so on the lob. Spigelii & margin of gall bladder.

Organ has a natural shape. On section it is seen to be in an advanced state of cirrhosis, the lobules appear as circular masses of varying size from split pea to pins head, yellow brown in colour, imbedded in a somewhat translucent fibrous matrix. Many of the lobules project considerably beyond the level of the structure.

CCCXV

Autopsy of Liver

Patient of C P Howard

Agnes. - Black æt. 9. . Sick for three months in coma
Symptoms hæmaturia, purulent - upset death.
Enlarge of spleen. Red spleen at post. Ascites punctured when
was tapped thrice
P.M. 27 hours after death.
Belly distended. - 3/4 pint of clear serum drawn off.
Superficial abdom. veins full. Lower part of thorax
distended. On op. abdom peritoneum much thickened
and covered with fibrin flakes particularly the parietal
layer. Matter exits sometimes of pyæmic & pus mottled
Bowels must intense at upper part of canal in region of the
liver. Liver is pushed up; except post. part presents white
colour from the amount of lymph & thickening of capsule.
Small intestines removed - they are sodden & heavy -
ruby not infiltrated, glands not enlarged.
Kidneys. enlarged, right ureter & pelvis dilated at
upper part. Capsules easily removed. Surfaces mottled,
in places very much congested. On section cortices coarse
looking, swollen. medullary rays distinct, intervening
vascular areas deeply injected. Vas. rect. of pyramids
injected. Pelvis not dilated. Ureters normal except
slight dilatation. Bladder healthy.
Stomach. Liver spleen & duodenum removed together.
Food in stomach - mucus partially digested, at cardia
nothing in duodenum - bile - dirty yellow in character
flows from the pap. but. on pressing the duct.

...erior border crepitant
...nding nothing
...mal.
... Coarse in Structure - Oviducal bodies distinct -
enlarged - 5 inches in length = 3 1/4 broad - Ant. lips
- On opening Cavity an elongated mass occupies
adherent to fundus and to anterior wall, loosely
& to posterior wall.

CCCXVI

Impaction of Faeces. Peritonitis

A. B. Baggage man on P. R. R. of sedentary habits, a gross feeder. subject to piles & with very irregular bowels felt a sudden pain in bowels ~~on morning~~ of Wednesday the 14th when on the train & jumping along the steps from car to car. When seen at 8 P.m by Dr Rogers had vomiting, & pain in abdomen. No fever. Ordered enemata, which on the following day brought away large masses of scybala. Vomiting continued, no special tenderness of abdomen. On Friday he felt much better & ~~walked~~ went ~~down~~ from Point St to his brothers at College St. On Saturday much worse. violent pain, vomiting persistent. Through rectum a mass could be felt. like hard feces covered with m.m. Enemata still administered & 3 gtt of croton oil, with the result of bring away large.

Death at 5.50 of the 19th. P.M. 4 o'clock on 20th.

Body that of a well built average sized man. belly ~~slightly~~ distended a dark ill-smelling fluid oozes from the mouth.

On op. abd. coils of small intes. distended, & relaxed peritoneum mod. injected & covered with exudate dry mass of lymph. chiefly collected ~~at~~ in furrows between the coils & at the areas of contact. Small amount of fluid in cavity - not more than 8-10 oz. Nothing of note found on tracing small bowel from duod to ileum. No twist, or band or intussusception. No spec inf about appendix caput coeci or beg of colon. Large bowel carefully removed. nothing unusual about it externally. A good deal of lymph & infl about sigmoid flexure. No special distension of the gut.

Small bowel partially slit open. - contains a yellowish brown like feces. Mucosa from duode to valve looks of the natural greyish appearance. no trace of inflammation... Peyers patches large. but normal. No diverticuli

---

terior border crepitant

nting nothing

rmal.

- Coarse in Structure - Malpigian bodies distinct -

enlarged - 5 inches in length - 3 3/4 broad - Ant lip

- On opening cavity an elongated mass occupies

dherent to fundus and to anterior wall, loosely

to posterior wall!

Large bowel. Cæcum & appen. perfectly healthy. In colon. M. natural no ulceration – no perforation. punctated same appearance in whole extent nothing specific in sig flexure & rectum.

Stomach distended with gas. contains a semi-fluid substance M. at depen pt. deeply injected. Duodenum. dark coloured. M. injected each part below pylorus. Bile duct pervious. [illegible] in 3 of the val. con. present distinct elongations at apex of ridges. [illegible] [illegible] to distance of 3 – lines no other change.

Spleen large. soft. Nothing specific in liver or kidneys.

Arteries normal.

---

erior border crepitant

nting nothing

rmal.

– Coarse in Structure – Malpigian bodies distinct –

enlarged – 5 inches in length – 3 3/4 broad – Ant lip

– On opening cavity an elongated mass occupies

adherent to fundus and to anterior wall, loosely

d to posterior wall!

Case CCCXVIII Phthisis

Admitted May 31. in the afternoon, died while in the bath.

Body that of an ill-developed, dirty woman. pale waxy bath.
In abdomen - nothing Special - Stomach situated little low
In pericardium - contains
contains large gelatinous
which extends into
gulum - Left Auricle
a Small clot decolorized
of blood & clot escaped
ventricle large, measuring
- Tricuspid orifice
inches. Left ventricle
valves healthy

base & lower border-
in Small Spots.
with cavities full
of lower lobe contain
masses. Scattered
are numerous tubercles

iversally adherent-
les are seen beneath
thin walled cavity
nd to inner side
large number of
cavities & breaking
erior border crepitant
nding nothing

abnormal.
Kidney - Coarse in Structure - Malpigian bodies distinct-
Uterus - enlarged - 5 inches in length - 3 1/4 broad - Anti-lips
projecting - In opening cavity an elongated mass occupies
it - Is adherent to fundus and to anterior wall, loosely
attached to posterior wall.

Montreal General Hospital.

MEMORANDA FOR THE PATHOLOGIST.

Case

Name Sophie Simpson Age

Date of entry May 31st Date of death May 31st 74
5:30 P.M.

Brief History
Died in hemiplegic attack
Convulsion

Chief Symptoms Cough lasting one
several months

Temperature range —

(Signed) A. Muskett

Case CCCXVIII Phthisis

Admitted May 31. in the afternoon, died while in the bath.

Body that of an ill-developed, dirty woman. poorly nourished fat.
In abdomen - nothing Special - Stomach situated little low
Thorax - firm adhesions on both Sides - In pericardium - contains
Small amount of fluid. Right Auricle contains large gelatinous
clot. Right Ventricle large firm clot which extends into
pulmonary vein as a dark soft coagulum - Left Auricle
contains dark clot. Left ventricle a Small clot decolorized
at its upper part. About Seven oz of blood & clot escaped
in removal of heart. Cavity right ventricle large, measuring
4 inches from pulmonary ring to apex. Tricuspid orifice
dilated, admiting heart - cone to 5½ inches. Left ventricle
normal Size. Bicuspid orrifice dilated. valves healthy
Nothing Special in the Auricles -
Right Lung - Slightly crepitant at base & lower border -
rest of lung firm & only crepitant in Small Spots.
On Section, upper lobe riddled with cavities full
of a thick pus. Middle & upper part of lower lobe contain
numerous isolated cavities & Cheesy masses. Scattered
among these the tissues are crepitant) are numerous tubercles
in all Stages of Softening
Left Lung - Layers of Splera universally adherent -
diaphragmatic layer numerous tubercles are Seen beneath
the Splural. On Section a large thin walled cavity
occupies the entire apex. Above and to inner Side
it is crossed by an unusually large number of
trabeculae. Lower lobe is riddled with cavatie & breaking
down Casious masses - Extreme anterior border crepitant
Splen - Average Size - Soft - presenting nothing
abnormal.
Kidney - Coarse in Structure - ~~Malpigian~~ bodies distinct -
Uterus - enlarged - 5 inches in length - 3 1/4 broad - Anti Lips
projecting - On opining Cavity an elongated mass occupies
it - Is adherent to fundus and to anterior wall, loosely
attached to posterior wall.

Uterus

Lower end is dark in color and on Section as seen to be made up of Coagulum. Surface of the mass is rough & a little Shaggy. On Section no trace of an ovum is seen.

Intestines normal- Stomach mammalated - Liver to and fatty

CCCXIX Diphtheritic Endometritis. 1

Adaline Brown aged 20
Admitted to the University Lying in Hospital
on the 19th of May and confined on the morning of
the 20th Natural labour. Placenta came
away in a few minutes after the child.
Uterine days after confinement temp from
99° to 105°.7 About fifth day complained of
pain situate chiefly in left iliac region
for wh hot fomentations were applied & Pulv
Opii gr ss Sodae Bicarb gr x ordered every three
hours. Pain continued on on next day
temp was 103°.7 with bad headache
after this she rapidly grew worse pain
continued severe, had headache and very
high temp as high as 105°.7. On eighth day
became insensible & died that evening.

P. M. 19 hours after death. Emaciated
girl well nourished young woman
Abdomen Position of viscera normal
Uterus projects above the pubes to a point
half way to umbelicus
In thoracic adhesions in right pleura
In pericardium a small amt of fluid
Right chambers of heart full of blood
& clots of blood no clots escape from heart
Heart normal size. Valves normal.
Tricuspid orifice 4 inches in circumf
Muscle substance healthy
Left Lungs heavy. only slightly crepitant
on section considerable exudation of blood
and serum.
Right Lung in same condition

Heart weighs 234 grms.
Spleen enlarged. pulp soft. dark purple in colour. Malpighian bodies large and very faintly marked. 417 grms.
Left Kidney capsule detaches readily surface smooth mottled cortex a little swollen
Right Kidney presents same appearance as the left

Liver lobules very distinct tissue soft on the centres vein & inter lobular veins quite distinct.
Inferior Cava right kidney, right ovarian vein & uterus removed together. On slitting up the cava a small mural thrombus is attached to the wall immediately below the orifice of the renal. It measures a little over 3 centm. is firmly attached to the wall, reddish brown in colour and appears to have broken down in the center The thrombus is found to project from the orifice of the ovarian vein which it also completely occludes. On slitting up the ovarian vein it is found to be pervious but its entire lumen is surrounded by a closely adherent thrombi On dissecting it down wards is found to extend as far as the uterus the veins of which empty directly into the ovarian
Uterus enlarged. 17 centm in length 12½ in breadth the os transversely placed measures ½ centm across edges are ragged, a glary & bloody mucus oozes from the surface as at the angle are some greyish yellow bits of membrane looking like diphtheria

Uterus opened cavity 14 cntm in length
internal surface rough irregular smeared
with a bloody fluid. Ant wall upper part
contains a projecting slough mass. When
washed the muscle fibres are exposed on
a considerable extent of surface, the
unexposed parts covered with a greyish
diphtheritic like membrane wh can be
stripped off as a definite layer. Uterine
walls about 20 milimeters thick in
central parts.
Brain Nothing abnormal

D W D

Adalina Brown

May 29th

Case CCCXXX. Duodenal Ulcer

Autopsy. Body that of a well-nourished moderately stout woman. Pan. adiposus very thick over abdomen.
In abdomen. coils of intestine dark coloured from staining of mucosa. peritoneal layer smooth.
Liver dark coloured. ascending colon & hepatic flexure. together with stomach & duodenum closely adherent to it at the ~~ant~~ front part of under surface.
Nothing special in thorax — In removal of intestines, in order to clear the way for dissection of duodenum & liver, it was noticed that the upper pt of asc. colon was closely united to the under surface of the liver & the piece so connected was enclosed with ligatures and left with the liver &c.. Stomach. duodenum pancreas & liver removed together. On ope. stomach, wh is of large size, about 1½ pts of clot and the remainder of food removed. — clot dark in colour.. Mucosa dark & blood stained otherwise unatt
Pylorus normal. In [illegible] the wall

idneys — normal in size — malpighian bodies
ry distinct — look quite healthy

llum — normal —

ain — weight of cerebrum 1960 grammes minus weight of plate.
ebellum weighs 137 grammes —

ring, in the upper and back part of the duodenum, a large orifice, 35 mm. in length, 15 mm in breadth, partially blocked into clots, which when removed allow of the insertion of two fingers, as far as the 2nd joint, into an oblong cavity the size of a small orange ~~which~~ occupying the under surface of the liver in the position of the gall bladder. The edges of the orifice are smooth and rounded. The remainder of the duodenum is normal. On dissection of the hepatico duodenal ligament, the following appearances are noted:— Portal vein uninvolved, normal in size. Common duct- pervious and can be traced down to the upper margin of the ulcer where it appears to open - at least the probe pointed scissors cut freely down and expired at at this place, from whence it could not be further traced. It probably has been cut across by the ulcer. The sphincter action in the lobes are normal. The cystic duct- opens by a small orifice and the probe can be passed into it for 1/2 an inch and it appears to end in a blind extremity in the wall of the sac. The probe pointed scissors appeared to pass directly into the sac but seems probably owing to a cut having opened the cavity. On slitting up the hepatic artery it is natural looking; a probe inserted into the right main division of the branch, which passes backwards & outwards, enters the cavity, and on slitting it open the wall is seen to be ulcerated across and the vessel communicates freely with the sac. The loss substance in the vessel about 3 x 2 m.m.

Kidneys - normal in size - malpighian bodies very distinct. look quite healthy

Spleen - normal -

Pancreas - weight 1960 grammes. Remains weight of Plate. The gall bladder weighs 137 grammes -

The sac was there freely exposed, and is no doubt the gall-bladder in a condition of ulceration. Towards the upper part a small portion of the wall remains but in the rest of its extent it is rough, ulcerated & in places sloughy. There is a deep prolongation towards the hilus of the liver and the tissue of which is here exposed and in a necrotic state; it is here where the ulceration of the artery has taken place. The ascending colon is closely adherent and a circular orifice of communication, 2 mm in diameter, edges rounded, exists between the two. When the sac is attached to the left lobe there is also considerable destruction of peritoneum and the pore finger can be thrust nearly as far as the 2nd joint in to the necrotic tissues. There is no appearance about the ulcer or the gall bladder to indicate a cancerous source. There is a good deal of thickening about the margins of the duodenal ulcer, but mucosa is not puckered. Pancreas normal.

Liver of full size, perhaps a little enlarged: tissue very dark coloured. A very distinct triangular shaped notch exists at the site of the gall bladder & the tissue in the neighbourhood is cicatricial. Scattered throughout the organ are numerous small isolated masses presenting the characters of secondary cancer; one of these the size of a walnut. On looking for a vein of this, the portal vein may be found matted & fixed in mineral.

Kidneys - normal in size - malpighian bodies very distinct. look quite healthy

Bladder - normal -

Aorta - weight 1960 grammes Urinus weight of plate. Cerebellum weighs 137 grammes -

CCCXXI

~~Path~~ Diphtheria

Montreal June 7th

CCCXXI

Montreal General Hospital.

MEMORANDA FOR THE PATHOLOGIST.

Case Diphtheria

Name Annie Edmond Age 4½

Date of entry June 4th 79 Date of death June 7th 79

Brief History Illness of 5 days duration
3 days
Diphtheria in family

Chief Symptoms Great prostration Swelling of glands feloy breath & hoarse loud cough. Membrane over tonsils & pharynx Laryngeal symptoms but very slight for last 24 hours
albumen in urine
Temperature range

100 - 102° F

(Signed) Illness Bell

I have not seen the patient

admitted June 4

female child

collapse

appendix

tonsils & entire wall of pharynx

diphtheritic exudation

laryngeal respiratory part of

epiglottis the undersurface

main Bronchi (tube

anæmic

adherent & abundant

pale

presents a thickened

in intestines nothing of special note.

Small parasitic worms in Cæcum & descending Colon

Kidneys - normal in size - malpighian bodies very distinct. look quite healthy

Spleen - normal -

Cerebrum
Brain - weight 1960 grammes Gyrus weight of plate.
Cerebellum weighs 137 grammes -

CCCXXI

Diphtheria

Montreal June 7th

Anna Edwards aged 4½ yrs admitted June 4

Died June 7

Body that of a well nourished femal child
In Abdomen nothing special
In Thorax Lungs full in vol. do not collapse
Pericardium nothing special
In Right auricle fluid blood + clot in apendix
In Left auricle clot is found
In Left ventricle small colorless clot
Pharynx, Trachea & Lungs removed together
Tonsils pillars of Fauces post. part of Uvula & entire wall of Pharynx
Covered with thick Greyish yellow Diphtheritic exudation
The upper surface of Epiglottis & lower respiratory part of
glottis is unaffected the tip of epiglottis the undersurface
the Rima & down the trachea & main Bronchi there
is a well marked Diphtheritic membrane
The membrane in trachea is loosely adherent & about a
millimeter in thickness
Lungs are crepitant full in vol.
Spleen a little enlarged
Kidneys normal size Cortices a little pale
Heart Valves normal
Anterior segment of Aortic Valve presents a thickened
spot
In Intestines nothing of special note,
Small Parasitic worms in Caecum & decending Colon

Kidneys - normal in size, malpighian bodies
very distinct. look quite healthy

Spleen - normal -

Brain - weight of cerebrum 1960 Grammes Grains weight of Plate.
Cerebellum weighs 137 Grammes -

CCCXXXII. Henri.

P. M. June 9th 1879

Body that of a large powerfully built man.
In abdomen omentum a little injected below adherent towards right inguinal region lower coils of small intestine injected.
Immediately above the pelvis a coil of intestine looks very dark and at one point is constricted near the constriction a tiny orifice is seen in the bowel through which the contents are escaping

The nipping has occurred in the lower part of the ileum just this side of the valve.
For about a foot from the constriction towards the valve the intestine is dark colored, the tissues at the point of constriction are soft and look as in a state of commencing necrosis
About a quarter of an inch from the constriction there is a small perforation through which the contents of the bowel escaped.
Immediately beyond this, as the duodenal side the intestine looks normal. The walls are relaxed and here and there are patches of extravasation beneath the peritoneum.
There are a few ounces of dirty brownish fluid in the peritoneal cavity.

The inguinal canal is dilated admitting the two fingers freely. The lips of the omentum is adherent in the ring

Auricles and right ventricle full of clots and blood altogether, about twelve ounces of blood escaped from the heart. which weighs 24½ Grammes.

Both lungs adherent and expirant.
Right ventricle present nothing abnormal valves healthy: heart compasses freely through between

ffie Miller . 9 in august . . 9 ale in . . . . all nourished.

arm tip of olecron to pro of ulna . . . . 2 ctm.

" " inner condyle to styloid rad. 19. ctm . . . . . . " " 20.5 ctm

t. arm at biceps. 15.6 ctm. . . . . Rt ~~forearm~~ at biceps 18.5 in circum

f. in thickest part. 17 ctm . . . . Rt forearm thickest part 21.

wrist. 12 ctm . . . . wrist. 15.5

round hand 15.7. . . . . round hand 20.3

d metacarp bone 6 ctm . . . . mid metacar b 5 c

" " finger 8.5 ctm . . . . mid med finger 8. ctm

dex finger 7.5 . . . . index finger 7.7

ring metacar joints 7. . . . . across metacarp jo 9.5

ng thumb joint 6.5 . . . . around thumb 9.

d ring finger 4.5 . . . . round ring finger 4.8.

d chest 55.5

29 at mid right side

26

nd . Shoulder fr spine to proc of pn. 19 . — — 22 ctm

houlder of rt and much larger, pectoral prominent, deltoid trapez
ght diff noticed in scapular muscl
Rt triceps much larger when tested up. Fore arm muscles developed
ks like that of a man, wrist thick, whole hand much develope
uckle joints large, like that of man. middle one prominent. On palm
hand thick pad of fat. Phalanges not much if at all larger or look
well on comp with the large size of metacarp bones.

CCCXXIII

Peri-caecal abscess. 24 hrs p.m.

Body that of a large, well nourished man. No signs of p.m. decomposition. Abdo. protuberant. On preliminary incision intestine accidentally wounded & immense quantity of foetid gas escaped. In abdom. coils of sm. intest. enorm. distended, & dark in colour. This cond. exist in all parts except: first 1½ feet of jejunum & terminal portion of ileum. Many of the coils are as thick as one's forearm. No fluid in peritoneum. On tracing down coils of intestines they can be followed for about 4–5 feet & then the lower ones in the neighbourhood of the upper part of pelvis are matted together & it is impos. to separate them so that they with the lower end of ~~colon~~ colon & all the pelvic organs were removed en masse. Lying upon the promontory of sacrum and extending toward the right side is a flattened purulent sac the size of the palm of the hand and to this the coils of bowel are & pretty closely adherent. On dissection following is state of affairs:. Caecum & large bowel normal. Appendix passes horizontally out & its extrem. is firm adherent to the sac. On passing a probe along its tube it is found to be perforated at extrem. in two places, by which it communic. freely with the sac. On slitting up the tube, m. m. normal to inner third, here is a [illegible] & at the apex the two perfs are quite distinct, & this part is closely connected to the sac. On slitting up ileum from valves 1st 8" normal; then it becomes adherent to the sac

---

an & the left

On section

ts, Pyramids look

renal artery thick and firm

ght vessel about ½ inch from Hylus of

is an aneurismal dilatation about size of pa

left small amount of lymph over posterior part upper

ndition of extreme oedema, other lung in same state

full size tissues soft + tears easily

CCCXXIII

James Hawkes. ag. 45 years.

In Feb. 1878, had a severe "bilious attack"; which yielded to the usual means, and since which time, he has never complained of any illness until April 24th 1879. —
The attack in 1878 kept him in bed about three weeks, and in a week or two more, he was apparently well. —
The attack which came on him in April 1879 began much

as the former one did, with obstinate
Vomiting, flatulence, Con-
stipation and thickly furred,
moist, brown tongue.—
The symptoms yielded to
the ordinary remedies and
by May 4th the tongue
was clean, the appetite much
improved; the bowels acted
both although the stools were
still very clay coloured
and offensive.— The flatulence
Continued although not so
distressing, and the belly

remained considerably disturbed. — There was no pain or pressure on the distended bowels at any time or at any point. — From this time his symptoms became aggravated, that is, the flatulence was more distressing and the bowels became loose, with yeasty, clay coloured motions (which were preceded & accompanied by griping pains) the odour of which was very offensive. — He now began to lose flesh also very rapidly. ——

4.

The symptoms continued much the same up to the morning of June 9th, when, about 8 o'clock, he passed a large quantity of blood suddenly in bed. He also complained of pain in lower part of belly. The blood was fluid, mixed with dark clots and loose foecal matter. —

At 12.30 he lost again a still larger quantity & sank rapidly, dying at 4 P.M, the same day. —

Hon. Hawke

CCCXXIII

1 CCCXXIV Meningeal Haemorrhage H. Cr. 14 Hours after death

Franklin Heart 420 gms.

Kidneys – 180 gm. + 182 gm

Brain. On removing Skull Cap – to which D. Mater was adherent a large flat black venous Clot was found between D. M. + brain. Covering upper + outer Surface of ant. half of right Hemisphere. A large amount of serous fluid forced out also on removal of Brain. When removed the Brain where it had been Covered by the Clot was flattened. The actual point of origin of the Haemorrhage could not be found. Arachnoid rather opaque all over Brain. Vessels at base are firm + contain white soft patches but no Calcareous matter. Brain on Section perfectly healthy –

Heart – Size appears normal – L Ventric very little if at all Hypertrophied. Walls measure 14 m.m. in thickness – Tissue a little pale – Mit. Valves healthy – Orifice 4 1/5 inches in circumference – Aortic semilunars healthy – Segments cribriform – R Ventric of full size measures 9 c.m. from pulmon ring to apex – Tricuspid orifice nearly six inches in circumference – a thick layer of fat exists beneath pericard. – Muscle subs. is much infiltrated having in places quite a yellowish fatty appearance –

Kidneys – Large, dk red in color, Capsules detached with ease, surfaces coarse + granular, numerous cysts exist in various parts, Renal artery little firm, arteries at Bases of Pyramids not distinct

Spleen – size moderate, very soft, lungs emphysematous at anterior border, at apex

an the left
t On section
ts, Pyramids look
Renal artery thick and firm
ght vessel about 1/2 inch from Hylus of
is an aneurismal dilatation about size of pea
left small amount of lymph over posterior part upper
ndition of extreme oedema, other lung in same state
full size tissues soft + tears easily

several large spots of appoplexy, & similar ones exist in right base.

P.M.-
Case of strangulated
hernia
June 9th 1879

CCCXXV

Wells

Fld in Thorax Oiv f—

Bld in Ht- Oi

T. Wells — size average. General anasarca, on ~~opening~~ abdomen, Oi/i8 of fluid. In pleura cavity
~~He~~
Heart large, on opening pericardium a thin layer of lymph covers the whole heart
e contain old clot
, left auricle full
y
diate district.
ircumference
pulmonary ring
~~roughly~~ developed
circumference
walls measure
umber measures from
llary muscles large
n.
— attachment
at its attachment
ments fenestrated
patches of
~~rtion of the~~
atous buttons abdominae
ed, pulp very

very fat around
without difficulty
ous cysts upon
le

an the left
t On section
ts, Pyramids look
normal, renal artery thick and firm
On right vessel about ½ inch from Hylus of
organ is an aneurismal dilatation about size of pea

Lungs. Left small amount of lymph over posterior part upper lobe in condition of extreme oedema, other lung in same state

Liver — of full size tissues soft + tears easily

375

Montreal General Hospital.

MEMORANDA FOR THE PATHOLOGIST.

Case Chronic Bright disease

Name Thomas Wells Age 54

Date of entry Feby 11th Date of death June 14th 79
1.45. am

Brief History
An old Soldier. A hard drinker. Acute nephritis four years ago from which he never perfectly recovered

Chief Symptoms Extreme distension of abdomen with fluid. Effusion into Pleurae. Occasional delirium for two or three days at a time. Urine pale scanty. Highly albuminous. Containing Hyaline Casts

Temperature range
98 — 100

(Signed) James Bell

several large spots of apoplexy, & similar ones exist in right base.

P. M. –
Case of strangulated hernia

CCCXXV

walls
Fld in thorax Oiv f—
+ Fld in Ab— Oi

J. Wells — size average General anasarca, on
~~opening~~ abdomen, Oi/8 of fluid. In pleural cavity
~~He~~
Heart large, on opening pericardium
a thin layer of lymph covers the whole heart
very little fluid, in right oracle contains old clot
sm. amt. of old. in right ventricle, left oracle full
of gelatinous clots ventricle empty
Right oracle large, Musculi pectinati distinct.
Tricusped orifice 5 1/2 inches in circumference
Right ventricle large 10 Ctm from pulmonary ring
to apex
walls a little thickened, strongly developed
ant. wall measures 8 M.M. in circumference

Left Ventricle hypertrophied, walls measure
nearly 2 Ctm. in thickness. Chamber measures from
aortic ring to apex 8 1/2 Ct.m. Capillary muscles large
mitral orifice 4 1/2 inches in Circum.

Valves, a little thickened at attachment
~~of~~ Cordae tendinae.
Anterior segment, little atromatise at its attachment

Aortic Valves stiff, 2 segments fenestrated

~~S~~

Aorta — presents a few sm. patches of
~~atheroma~~ in the ascending portion of the arch.
Thoraic aorta presents a few atheromatous buttons abdominal
several flattened patches
~~Spleen~~ very irregular in shape, pulp very
soft.
Carotids not much atheroma
Heart — 550 grammes

Left Kidney weight — 153 grammes, very fat around
the capsule, capsule detatches without difficulty
face of organ smooth, numerous cysts upon
surface | On Section, little pale

Right Kidney — Little larger than the left
several cysts one size of wallnut. On section
cortex little mottled, pale spots, Pyramids look
normal, renal artery thick and firm
~~In~~ right vessel about 1/2 inch from Hylus of
organ is an aneurismal dilatation about size of pea.
Lungs. Left small amount of lymph over posterior part upper
lobe in condition of extreme oedema, other lung in same state
Liver — of full size tissues soft + tears easily

326

Friday June 20th/79.

Pneumon

Body that of a small moderately nourished
woman, Panniculus well developed
On opening abdomen colon much distended
umbellicus
than a lead pencil
but does not
ast. vein but is
immediately beneath
s in a tortuous
on tracing
of abdomen ~~and~~
before terminating
walls of abdomen

y are enormously
tissues in broad

large size
large but not forming
left the vein &
passing up

ize measuring
the renal

y tenacious mucus
ous memb. is thickened
are injected
Pylorus are two
mucus memb.
section small
dividual elements

r losses of substance
cular connected
ct bile flows from

rmal

admits index finger
e seen entering the
ameter of a lead pen
passing off towards the ant. border is a large bran
which joins the distended umbellical vein,
this umbellical vein is 2 centimeters in circumf

Inferior Cava enormously distended admitting the
three fingers where it passes through the liver
hepatic veins also large 2 of them admitting the
index finger to the first joint

326

Montreal General Hospital.

MEMORANDA FOR THE PATHOLOGIST.

Case Pneumonia

Name Bridget Short Age 56

Date of entry June 16th Date of death June 20th 79
8 a.m.

Brief History

unknown
Moribund on admission

Chief Symptoms Cough dyspnoea & rusty-expectoration with pain in Rt. side.
(Felt breathing on rt side for long time past)

Temperature range

99 – 101°7.

(Signed) James Bell

On Friday June 20th 1919.

Pneumon

Body that of a small moderately nourished woman. Panniculus well developed
On opening abdomen colon much distended
Passing in falciform Ligament & umbellicus
is a large tortuous vein, larger than a lead pencil
it passes to the umbellicus but does not
here join the superficial epigastic vein but is
continuous with deeper veins immediately beneath
the peritoneum & which pass in a tortuous
direction towards the pelvis on tracing
down the deep vein of abdomen
empties into the internal illiac before terminating
it receives several veins from walls of abdomen
& from the bladder,
The veins about the left ovary are enormously
distended filling up the tissues in broad
ligament
Left ovarian vein is of very large size
Right ovarian vein also very large but not forming
such a large plexus as the left the vein
itself is not quite so large & passing up
empties into the cava
The inferior cava is of large size measuring
5½ centimeters across just above the renal

Stomach A thick layer of very tenacious mucus
Covers over the stomach, mucus membr. is thickened
Capillaries in many spots are injected
and immediately outside the Pylorus are two
long grayish black patches, mucus membr.
appears to be absent but on section small
bodies are seen like the individual elements
of Brunners glands
Lower down are several other losses of substance
Chiefly along surface of valvulae Conniventes
on squeezing the common duct bile flows from
the Papillae
Common bile duct pervious & normal
Hepatic artery natural
Portal vein in the ligament admits index finger
On slitting up 3 or 4 portal vessels are seen entering the
liver the largest having the diameter of a lead pen
Passing up towards the ant. border is a large vein
which joins the distended umbellical vein
this umbellical vein is 2 centimeters in circum

Inferior Cava enormously distended admitting two
three fingers where it passes through the liver
Hepatic veins also large 2 of them admitting the
index finger to the first joint

Liver large very irregular in shape particularly on under surface. The upper surface presents numerous irregular nodules. Capsule is smooth & no small granulations.
The under surface there is considerable deformity from a large mass formed apparently by the bottom of the left lobe, ~~is detached~~ on section the organ is fibroid, the increase in fibrous tissue the individual lobules not much fibrous tissue between them. Liver weighs 1755 Grammes
Left lung crepitant throughout
Right lung ~~crepit~~ near the apex is airless the lung tissue infiltrated with a greyish soft material which is extremely friable readily ruptured beneath the finger & in places breaking down under a stream of water, the ant. & lat. portion of the lung is covered by a moderately thick layer of pleural beneath which the lung tissue has broken down in a great part of its extent. it is not caseous nor is it gangrenous but the tissue is soft & shreddy & breaks down with considerable ease
Lower lobe crepitant middle lobe in central part

Heart large, Right auricle large R. ventricle average size trabeculae unusually developed, valves normal Tricuspid orifice allows the heart cone (6 inches) to pass freely. L. ventricle hypert. measures 7½ centimeters from aorta ring & apex ant wall middle portion 25 millimeters in thickness, septum 20 millimeters papillar muscles large Mitral valve thickened & gelatinous on auricular edges
Aortic valves competent & normal. Few patches of atheroma in first part of arch
Kidneys large, Capsule detaches with slight difficulty Surfaces thin, surfaces a little granular, on section organ contains a good deal of blood Malpighian bodies very distinct, vessels of the pyramids also injected small arteries not very prominent

Brain normal, arteries at the base atheromatous

327 28.54) 370 (13
283
870
849

Body — that of average aged much dropsical woman — esp in lower extremities and back — ~~abdomen~~

On opening Abdomen — liver extends a full hand's breadth below ribs & ensiform cartilage — about 12 oz of milky turbid fluid taken from peritoneal cavity — In thorax universal adhesions of left side — On Rt side only at upper part of pleura & about 8 oz of fluid taken from this cavity —

Rt Auricle contains a large gelatinous clot c̄ numerous ulcerations and the vena. In Rt vent a fibrinous &

327

Montreal General Hospital.

MEMORANDA FOR THE PATHOLOGIST.

Case Pulmonary Phthisis (Friendless)

Name Victoria Genot Age 45

Date of entry June 6th Date of death June 27th

Brief History

Chief Symptoms Dyspnoea — Cough with muco-purulent Expectoration Night Sweats — Fever — Haemoptysis; & Diarrhoea —

Temperature range

(Signed)

A. W. Imrie.

P.S. Drs. Fenwick & Roddick operate at twelve thirty (12:30) — A.W.I.

---

full of dark clot
decolorized clot.
blood escaped
l — Musculi Pect. Wist
dilated — measures 11.5 cm
to 6 m m thick —
e in m thick. Mitral
mainly 4.5 in in circum
ctured —
ble together with
e to chest wall &
ts are firm, uniform
tissue & irregular
coval —
the whole of the
mately dry with the
e which is ~~ad~~ adventitious
t only at ant. border
s & contains at the
of a small apple
y a good many
in groups.
in fibroid region
firm, pulp breaking
le detaches c̄ but
should been proven
process of amoeboid
tion! — On section
pale — opaque lines
second stage of
weighs 290 — has
ntity of dirty fluid
ing. Firm in which
out the middle of

the post. wall is a small yellow-white slough measuring 6 x 10 m m & involving ~~all~~ the coats as far as the muscular. — At the Pyloric ring is an ulcer 25 x 8 m m — situated directly upon the pyloric ring & passing to the depth of 3 to 4 mm.

Gall bladder small — contents no bile but 2 large gall stones — Common duct full size — Cystic duct pervious. Portal vein — normal — Artery also. —

Liver weighs ~~3~~ 3500 grammes. —

Liver large very irregular in shape particularly on
under surface, the upper surface presents numerous
irregular nodules. Capsule is smooth & no small
granulations.
The under surface there is considerable deformity
from a large mass formed apparently by the lobus
Spigelii & Caudatus. This mass which is half the
size of the left lobe, ~~is detached~~ on section the organ
is fibroid, the increase in fibrous tissue
the individual lob[illegible] much fibrous tissue betw
them. Liver weigh[illegible]
Left lung bro[illegible]
Right lung ~~con~~
the lung tissue
which is extreme
the finger + in
of water, the a
by a moderately
lung tissue has b
extent, it is not
the tissue is so
-siderable ease
Lower lobe cre

Heart, large, Rig
size trabeculae
Tricuspid orifice
freely. L. ventr
from aorta
portion 25 m
millimeters
thickened & fel
aortic valves
of atheroma
Kidneys large, b
Thin surfa
organ contains a
very distinct
small arteries

Brain normal,

327 (28.3+) 370 (13
283
870
849

Body - that of average aged much dropsical woman - esp in lower extremities and face - ~~Abdomen~~

On opening Abdomen - liver extends a full hand's breadth below ribs & ensiform cartilage - About 12 oz of milky turbid fluid taken from peritoneal cavity - In thorax universal adhesions of left side - On Rt side only at upper part of pleura & about 8 oz of fluid taken from this cavity -

Rt Auricle contains a large gelatinous clot & numerous [illegible] into the veins - In Rt. vent a firmer & more decolorized clot. Left Auricle full of dark clot. Left vent contains a tolerably firm & decolorized clot.

On opening heart about 20 oz blood escaped. Heart weight 370 grs - Rt Aur. dilated - Musculi Pect. visible over the whole sinus - Rt vent. dilated - measures 11.5 cm in length - Trab. much developed - walls 5 to 6 mm thick - Tricusp. open. nearly 8 in circumference

Left vent 9 cm long walls 10-12 mm thick. Mitral valves thickened at edges - orifice nearly 4.5 in in circum. - Aortic valves normal - Aorta natural -

Rt. lung - post part of upper lobe together with the middle lobe very closely adherent to chest wall & torn in removal - these parts are firm, airless & made up chiefly of fibrous tissue & irregular cavities which were torn on removal -

The ant pt of ~~upper~~ upper lobe & the whole of the lower lobe are crepitant, moderately dry with the exception of the extreme lower edge which is oedematous.

Left lung - upper lobe crepitant only at ant. border, remainder of lobe firm, airless & contains at the outer part ~~[illegible]~~ cavity the size of a small apple - Lower lobe crepitant, contains a good many miliary tubercles - some arranged in groups.

Bronch. tubes tolerably normal - in fibroid region thickened

Spleen weighs 300. grs moderately firm, pulp making sections much difficulty

Rt. Kidney very large - capsule detaches with much diff. - Surface smooth - stellate veins prominent - Surface also mottled - areas of anaemia alternating with ~~[illegible]~~ areas of congestion. - On section cortex much swollen, moderately pale - opaque lines seen in places - present picture of second stage of Bright's Disease weighs 325 grs

Left Kidney - not so large weighs 290 - has much same appearance. -

Stomach contains a small quantity of dirty fluid - in one of and portion present along lines in which ~~the~~ it is infiltrated with blood. About the middle of the post wall is a small yellow-white slough measuring 6 x 10 mm & involving ~~all~~ the coats as far as the muscular. - At the Pyloric ring is an ulcer 25. x 8. mm - situated directly upon the pyloric ring & passing to the depth of 3 to 4 mm.

Gall bladder small - contains no bile but 2 large gall stones - Common duct full size - Cystic duct pervious also. -

Portal vein - normal -

Liver weighs ~~3~~ 3500 grammes. -

Liver weighs 3500 grammes - Enormous size retains shape, firm on section, some what pale & in a condition of advanced amyloid disease

Spleen & Pancreas - taken on bound down to post part of uterus - the external membrane adherent thick & dense — numerous pale corpora lutea — Ovaries normal —

Aorta gives a few traces of fatty degeneration

283 | 35-00 (123.
283
670
566
1040
849
1910

123

328

Contents of Kid. Pel Ves

June 26. 79

Body of an old poorly nourished woman. In abdomen liver extends three fingers breadth below costal border and the margin is cirrhotic. On opening the chest heart occupies a large space. In right pleura adhesions and a turbid slightly blood-stained fluid: upper and middle lobes adherent. In right pleura ʒiv x iv of fluid. In left pleura ʒx. In pericardium of fluid ʒfs. Right chambers distended with blood. Left auricle cont. a large gellatinous clot: left ventricle also contains a thick gelatinous not decolourized clot. In removal abt. ʒx x iv escaped from the cavity. Right auricle dilated. Tricuspid orifice large, (the heart cone passes through it). R. Auricle a little dilated: Trabeculæ distinct. Valves normal. Pulm. semilunar Jenestrated. Chamber measures 11 ctms. from pulm. ring to apex. Left ventricle large and hypertrophied: walls measure 16 m.m. in thickness: mitral valve thickened and firm at free edges: orifice 4 in. in circumference: aortic semilunar valves competent and a little opague. Muscle substance pale, in places streaky. Weight of heart 430 grammes

Right lung upper and middle lobes crep. and contain good deal serous fluid. Lower lobe solid, dark in colour, Lower lobe consolidated heavy: anter. and lower border very dark in colour, appearing in a condition of haemorrhagic infiltra. Upper & post. lbs. slt. crep. and contain a large amount of serum. On opening up the pulmonary artery a large thrombus is seen to occupy the main division passing to the lower lobe: it is colourless and extends into all the branches passing to the lower lobe. It is firmly attached in these branches, and in some of them is only partially decolourized

Left lung crepitant except at one small narrow piece in the lower and natural border.

Kidneys small and present numerous cysts over the surface, some filled with clear fluid others with a yellow turbid fluid, & others with a dark brown fluid. Capsule is adherent. On section the organ is firm, the surface is granular, the cortical part diminished in size, the small arter. at the base of the pyramid very prominent Renal artery very thick and atheromatous. In the left kidney there is a large cyst the size of a wall-nut. L. kid. 83 grammes. Right 110

Spleen small. Capsule fibroid. On section organ firm, trabeculæ and vessels very distinct. Weight 83 grammes.

Liver firm, small: in anterior margins fibroid. Gall bladder full. Weight 1040.

Uterus normal size. Mucous membrane of cavity haemorrhagic

Aorta dilated, particularly in lower part and numerous atheromatous buttons down its course

Brain. Arteries at base atheromatous

Pyaemia

Body of medium size & of good muscular development & well nourished. No exfoliation in the body or face. The face is of rather a pallid hue. In several places as along the sacrum & hips the veins are discolored.

~~Head~~ & Abdomen - On opening the abdominal cavity the organs seemed to be in their normal position & the stomach moderately dilated. A very small amount of fluid in the peritoneal cavity

Spleen - of a dull brown color very soft & slightly enlarged size - weight 250 grains.

Thorax - Heart slightly above the normal size. Contained no blood in either auricle or ventricles, but was distended with air; soft in texture, valves healthy no deposit of pus & no trace of any pyaemic abscess.

Lungs - No fluid in any appreciable quantity in the pleural sac. Right lung strongly adherent to the diaphragm. Both lungs found in healthy condition only having exceeding quantity of serum & blood in dependent parts. No pyaemic abscesses in them

Kidneys - Of equal size - very soft - of a duller hue than normal. Capsule somewhat adherent. Right kidney weighs 190 grs - Left - 200 grains

Stomach - Had a quantity of matter of a dark color & moderately distended with air. Mucous membranes soft like the other organs

Intestines - Nothing abnormal about either large or small intestine. The small intestine were distended with gas.

Liver - Is extremely soft. When cut shows a dull leaden hue. No pyaemic abscess. Of average size

Brain - Not examined.

Scapula - Cap infiltration of pus into the tissue surrounding the scapula. No deposit of pus at the elbow or wrist. The scapula was found to have been fractured in a very irregular manner & divided into 5 parts.

Mr V. thought that not
Pyaem. – Perhaps Septicaemia

Complaining of fracture
How he got the
fracture

As to Pneumonia

Howth

Montreal General Hospital.

330

Montreal, Dec 24 1879.

Body that of a small, much emaciated woman. P.M. 7 hrs after death. In abdomen, position of viscera, normal. Strong adhesions, both pleura. In Right auricle, fluid blood. In Right Ventricle gelatinous clots and small firm decolorized one at apex interlaced c Columnæ Carnæ. Tricuspid orifices in. Valves normal, one segment fenestrated. In Left Ventricle. A firm leathery clot attached to the Cordæ and to the wall. Mitral Valve Normal. Aortic Semilunar, same. One segment has a small fenestra. Substance of organ, pale. Heart. Weight 1 lb 0 grammes.

Left Lung. Universally adherent. Parietal pleura removed c it. On stripping off parietal pleura, the visceral layer covering the upper lobe, particularly anterior part is closely studded over c tubercles, varying in size from a pin's head to a small shot. The pleura over lower lobe, is thickened. At the apex, there is a large irregular cavity filled c somewhat bloody pus. It is irregular extending low down on the side of the lobe and behind. It is crossed by numerous trabeculæ, lining membrane rough, reddish in spots and covered c greyish membrane. Towards the Anterior part there are also a number of smaller cavities and the intervening tissue is stuffed c tubercles. Lower lobe, upper part behind, several small cavities, size of marbles.

In pulmonary tissue surrounding them, is occupied by groups of closely set tubercles some of which have softened, others, are

rapidly becoming Caseous. Throughout upper and Ant^r. part of the lobe, there are numerous isolated groups of tubercle, about many of which the lung tissue, has a gelatinous look. Bronchial glands are moderately swollen. Right Lung. Pleura universally adherent and both layers are thickened being impossible to separate them. Upper lobe is composed of a series communicating cavities. There is hardly a trace of normal lung tissue in the lobe. The Antr. borders are occupied by numerous cavities and breaking down Caseous masses. The Lower lobe is almost airless; at its Upper and back part, there is a large cavity which communicates with the one in the upper lobe. Entire tissue is infiltrated with innumerable small greyish yellow bodies, in spots very closely set together, in other places, more loosely arranged and all surrounded by a somewhat greyish pale infiltrated tissue. It is only at one or two spots, in the lower border that there is normal looking lung tissue. At the back part of the lobe, there are great many small Cavities. Bronchial glands belonging to this lung are large, greatly swollen, but, are not Caseous.

Spleen. Large. wt. 225 Grammes. Malpighian bodies in a state of Amyloid degeneration. Kidneys. Natural size do not look Amyloid.

Uterus. Os large and transverse. Length from Int. os. almost as great as the body. Folds in the neck very prominent. On left side, clear cyst, size of a marble near F. tube.

Intestines. Several small ulcers in lower 2 feet of Ileum and in Cecum. None in Colon or in other parts of small intestines.

Liver. In a state of Amyloid infiltration fibrosa.

Stomach. Mucosa pale, Normal thickness, very much Varicosed.

Brain. Nothing special. No tubercles at the base.

Cause of Death
Hemorrhage
2/12/95

331

Caries of Vertebræ

Body that of average sized moderately well nourished woman. Slight oedema of ankles, Skin pale. In abdomen, Stomach

slight ounces

a

icardium 3 iv

e distended c

sized in its

icle

. in left Vent.

an abscess

mall ~~[illegible]~~ quantity

t serum 4 oz

hae & bronchi

ous, mucous memb.

ary anteriorly free.

ly crepitant

organ in a condition

in lower lobe

[illegible]

the district

is internally

rhagic

l On the upper

is a firm spot

n slitting up.

l the lung is

are a few groups

sion at the apex.

Spleen; average size tissue firm, malpigian bodies distinct & in a state of amyloid infiltration. ~~Kidneys~~ Spleen weighs grams 145

Kidneys Capsules detach readily cortices pale tissue firm. On applic of Iodine traces of

Liver not enlarged, pale does not look waxy, but on iodine test a

& a few spots over the tissue became of a mah

Montreal General Hospital.

MEMORANDA FOR THE PATHOLOGIST.

Case Caries of Vertebræ

Name Annie White Age 22

Date of entry May 29th Date of death Dec 16th 79
1.30 am

Brief History

Always enjoyed good health until a year and a half ago

Chief Symptoms

Pain in Rt. Sacro-Iliac region swelling of rt side of Pelvis.- abscess pointing at back – grad. failure of powers great anaemia & pulmonary complications & death. Oedema of lungs at last

Temperature range

98 – 100 F.

(Signed) James Bell

Uterus. Os large and tra[illegible]verse. Length from Ext. os. almost as grea[illegible] as the body. Folds in the neck very pr[illegible]minent. On left side, clear cyst, siz[illegible] of a marble near F. tube.

Intestines. Several [illegible]small ulcers in [illegible]to Cecum. Gone [illegible]all Intestines. [illegible]d Infiltration [illegible] pale, normal [illegible]ted.

[illegible] to tube etc

Hawaiian

Caries of Vertebræ

Body that of average sized moderately well nourished woman. Slight œdema of ankles, skin pale. In abdomen. Stomach distended c̄ gas. In thorax eight ounces of clear serum in Rt. pleura

Heart & Pericardium; In pericardium ℥iv clear serum; Rt. auricle distended c̄ large gelatinous clot decolorized in its upper portion; Rt. Ventricle

In making preliminary incis. for left Vent. cutting parallel to the septum an abscess was opened in the wall & a small ~~[illegible]~~ quantity pus escaped: Weight of heart grams 400

Lungs: On slitting up trachea & bronchi a great deal of frothy serum, mucous memb. clear. Branches of pulmonary artery free. Rt. Lung almost airless & fully crepitant only at the apex, the rest of the organ in a condition of dense œdema. No infarcts in lower lobe One branch of pulmonary artery plugged. The lung tissue (in the branches) in the district supplied by these branches is intensely œdematous but not haemorrhagic

Left lung also very œdematous On the upper & inner face of lower lobe there is a firm spot of haemorrhagic infarctus. Upon slitting up pulmonary artery, the apex of the lung is slightly puckered & there are a few groups of small tubercles, no adhesion at the apex.

Spleen; average size. Tissue firm, malpighian bodies distinct & in a state of amyloid infiltration. ~~Kidneys~~ Spleen weight grams 145

Kidneys capsules detach readily cortices pale tissue firm. On applic. of iodine traces of

Liver not enlarged, pale. does not look waxy. but on iodine test a

& a few spots on the tissue became of a mah

332

7

Body that of well nourished woman, rigor mortis present, Extensive bluish white cicatrices on left thigh & a deep irregular ulcer on lower & anterior asp of same thigh & another on anterior aspect of leg Nothing special in abdomen, Cicatrices also on outer aspect of R. Forearm & round the arm of same side

Thorax. No adhesions

Heart

Right auricle & Large Veins full of blood, L. Auricle also contains fluid blood. L. Ventricle almost empty. On Dissection of Heart. Valves normal, tricuspid orifice little large, Muscular substance little pale

Lungs

Left Lung crepitant throughout, contains good deal of blood in dependent portions Nothing in arteries or veins

333

Aneur of Bardas. Heart mem. – 510 m

Dr McConnell's case:–

Heart enormously enlarged – gen. hypertr. Pericardium universally adherent not much thickened. Rt aur full of clots, partly decol. at [illegible]. Tricuspid valve persists as large. Tric. orif over 15 cm in circ. very large. valves thin. Rt vent cont. blood & clots. Chamber sev. dil. & hyper. Pul semi val. Muscl. thick and prom. trabeculae prominent. Left auricle dilat & large. Endo opaque & in several spots thickened & rough. Mitral orifice dilated. ca. 6 cm circ. valves thickened & opaque, chordae large & firm. not. Chamber enormously dilated & bulges to right vent. Meas. ca 7" fr. aortic ring to apex. Trabec flattened some thin, others, deeper ones, large. Muscle substance pale looking &

valves semi-opaque thick & crumpled, the free edge being nearly 3/4" below the line of attach of the [illegible]. The thickening is chiefly at the central part and along the free borders, the left ant. the shortest, the rt ant. the widest. Free edges are rounded & thick. Sinuses of Val. small. Aortic circ orif a usual distance above the free edges –

55
36
71

Mucous
lesions at
pper part
of the le
& the pl
lease,
case
it is dark
ly extent
is a larg
sen into
Vagina
there by
be seen
reas of the
shed
with
breathe the
d

ning a large quantity of purulent fluid co-
; it was not measured but quantity was all
was less between 20 & 30 ounces. The whole
is divided into a number of loculi some of
as large as an orange. Walls are rough
covered over with a tenacious slough
, & they all communicate with the pelvis
organ which is only moderately dilated
proportion to the kidney. Ureter communicates by
row orifice not much larger than the
al tube. Below this, it is dilated and in the
as large as the thumb. Walls are thick
pale, not ulcerated. On tracing ureter d
trains its larger size to within half an inch
dder when it appears to terminate in a blind

333 A

Cancer of Uterus. Pyometra.

June 6th 09

Uterus contains hardened faeces. Mucous membrane normal.
Bladder normal, closely adherent to Uterus at lower part.
On Slitting up Vagina, ulceration at upper part of Post. Wall is perforated, no trace of the os in the front. Orifice is narrow, walls of this portion puckered, exceedingly hard and dense, immediately surrounding the contracted portion of W. is not distended. Mucous membrane is dark & unaffected in the upper boundary of the ulcer lying to the left side. Behind the Uterus is a large sac filled with pus, it extends deep down into broad ligament, & lifts and almost to the Vagina walls above slightly and crossed here and there by trabeculae. No fallopian or ovary is to be seen on this side. On the right side the tissues of the broad ligament are not so much involved. Kidney greatly dilated, being distended with pus. In the body it extends from high up, beneath the liver, to a level with the crest of Ilium.
On opening a large quantity of purulent fluid escaped. It was not measured but probably in all must have been between 20 & 30 ounces. The whole space is divided into a number of loculi some of them as large as an orange. Walls are very thin and covered over with a tenacious slough. This all communicates with the pelvis of the organ which is greatly dilated in proportion to the kidney. Ureter communicates by a narrow orifice not much larger than the normal size. Below this, it is dilated and in the body was as large as the thumb. Walls are thick mucosa pale, not ulcerated. On tracing upwards it gradually increases in size to within half an inch of the bladder where it appears to terminate in a blind

extremity. At bottom of this apparent cul-de-sac there is a small orifice, through which a bristle can be passed into the bladder. The canal, through which it passes is about three fourths of an inch. The stricture lies about a quarter of an inch from the normal uterine neck and has resulted from the involvement of the tube by the contraction of the tissue at this part. Tube immediately beyond the constriction is of normal size and appearance. Ureter communicates with the pelvis by a comparatively narrow orifice which measures one centimeter in circumference. The capsule of the kidney is thickened particularly at upper part. It strips off easily leaving a dark surface which still retains some appearance of kidney structure. Wall of kid. is exceedingly thin ranging from 1 to 2 millimeters in thickness. Left Kidney is normal size, pelvis somewhat dilated and the dilatation extends to the Calyces, many of the pyramids of ~~the~~ are flattened. On right side immediately outside of and a little behind the left ovary is attached and is in a saccular condition being dilated ~~to~~ size of a small apple, in the wall are pigmented spots some of these still yellowish in color. Arteries & Veins of Pelvis are not affected.

Case CCXXI
Cancer Uteri.
Pyonephrosis.

ual

al Vol 8 in full

McGILL UNIVERSITY MONTREAL

Dear Dr Fulton

Please insert advt.
as usual.

a fleshy "thickening in the free border. Corp arantii [illegible] all
[illegible]

ommon ... The branches
ich enter the liver are small
numerous - 10 or 12 in number

er - small - tissue soft
brown in color. Not ...

tremity At bottom of
is a small orifice, thr
be passed, into the bla
which it passes is
The stricture lies about
narrowed along with
involvement of the, tube
at this part. Tubes
is of normal size and
mmunicates with the
ifice which measures
wance The Capsule
particularly at upper
leaving a dark
appearance of Kid
is exceedingly thin
ureters in ~~[illegible]~~ si
ze, pelvis. Conversion
extends to the Calyces,
are flattened
On right side immediately
the left ovary is attached
dilated to size of a small apple ~~and~~ [illegible]
are pigmented spots some of these still yellowish
in color Arteries & Veins of Pelvis are not affected,

emerging from left vent. over left
Bronchus & then ascends as the
thoracic Aorta — 7 m m from origin
it gives off the Pulmonary Artery
25 m m from origin it gives off
the left subclavian which forms a long
branch which passes vertically up to
the first rib. —

Left Vent. is tolerably large chamber walls thick
from 3 to 5 m m. — Ventricular Sept
Mitral valve normal —
is imperfect — the orifice is the size of a
goose quill. — To its upper border the
left segment of the tricusp is attached &
can be drawn down so as almost
to close it. —

A vessel is given off from this vent.
about half the size of that from the Rt.
which passes up upon the trachea for
12 m m & then bifurcates into two vessels one
the innominate giving off the rt car. & sub. the other the
left carotid. Just at the point of origin of this vessel
are three or four small fibrous bands which pass down upon
the ventricle, and one is attached to the left aur. appendix
On opening the orifice two semilunar valves only are seen. One large one
situated to the right & a small one toward the left. both are
thin and natural looking. From the side of the artery a median
raphe is seen passing down on the arterial wall as far as the attach-
ment of the valve. The coronary arteries are given off from this vessel
the left from normal situat. the right 4 m m above the valve

On opening the right vessel — aorta — only two valves are found. both
measuring about 1 cm along free border & between them is a small
imperfect valve. The large valves are situated right & left. At their point
[illegible] they do not meet, i.e. their raphes do not join but leave
a space 2 m m intervening. In this space the imperfect valve is
situated  forming a small membranous fold
filling in the interval between the other & at margin not reaching
the same level. The left valve [illegible] —

Case CCXXI
Cancer Uteri
Pyonephrosis

on removing ant. wall of thorax –
Heart seems in normal position – of large
size – Pericardium drawn down into
the costal arch –
Lungs small – Rt larger than left –
the kidneys ~~occupy a large space or~~
project high up – the Rt to the level
of the 5th rib at lateral point – the left to
the 6th – Separated from the lungs
by a membrane which appears to be
the diaphragm. –
The Supra renal organs are situated ~~at~~
~~the [illegible]~~ below the kidneys

Heart perhaps a little enlarged – smaller about
the size of the child's fist.
Rt. auricle normal contains a small
amount of blood
Eustachian valve well developed
foramen oval open –
a very thin translucent [illegible] can be
drawn up from the left border of the
foramen & when stretched nearly half
closes it –
Tricusp valves & surface normal
two small hemorrhagic nodules on the
valves –
Rt ventricle has a larger cavity than
the left walls moderately thick 2 to 3 mm.
Conus normal – from this cavity a large
vessel is given off 8 mm across at
the root – it takes the course of the
aorta but has no definite arch but passes
immediately to left across the vessels

---

al Vol 8 in full

---

which enter the liver are small
numerous – 10 or 12 in number

er – small – tissue soft
e brown in color. Not [illegible]

tremity. At bottom of
is a small orifice, th
be passed, into the Ur
which it passes is
the stricture lies abou
forward already with
involvement of the tube
at this part. Tube
is of normal size an
municates with th
ifice which measur
ence The Capsule
particularly at upper p
leaving a dark one
appearance of Kid
is exceeding by thin
ureters in ~~[illegible]~~ as
ize, pelvis convert a
extends to the Calyces,
are flattened
On right side immediately
the left ovary is attached a
dilated to size of a small appl
are pigmented + spots some + of these still yellow
in color Arteries + Veins of Pelvis are not e

Cancer Uteri
Pyosalpinx

334

Tip of ear to tip across open — in 8½
Fronto occiput —— 12 3/4
Hat measure —— 12½
Pari to Maxillary —— 13⅛

Entire length c m 32. — Lft. Up. Ext. from shoulder to wrist 10 c
from wrist to tip of fingers 4.75 cm. —
Rt. Up. Ext. Shoulder to end of Radius 11. cm

Projecting from centre of abdomen is a large mass. size of a cricket ball — covered in the greater part of its extent c a translucent membrane through which the liver + intestines can be distinguished — circumf. 17. c.m. — circumf. of base 7.5 c.m. — Umbil. cord — attached on left side of this — is a little smaller than natural — It appears to spread out on under + left. surfaces of sac.

On opening sac the liver, stomach, spleen and almost all large + small intestines are contained in it. — The upper convex surface of the liver lies ~~antero-laterally~~ upwds + fdwds c the ant. sharp border of the organ being directed towards the spine — the rounder post border downwds + fdwds —

The Umb. vein passes round the left side of the sac taking a sharp curve near the ribs then forward to enter the fissure in the narrow margin of the liver. —

The general position of the viscera is tolerably natural — liver to right — spleen to left — Stomach wedged vertically between them — intestine ~~below all~~ in lower part.

Mitral valve disease

Case 335   Can. M & S journal Vol 8 in full

ich enter the liver are small

numerous - 10 or 12 in number

er - small - tissue soft

e brown in color. Not

Mss. Vomiting of blood. Probably case of Leukaemia

— Case referred to in C M & S Jour Vol XI No 3 or 4

Spleen - 330 grammes capsule shrivelled - tissue moderately firm - tissue reddish brown - Vein and artery appear normal, no thrombi in them.

Stomach - contained some dirty black fluid. Mucous membrane ale - nowhere blood-stained - no race of ulceration or any stinct pathological process - Pylorus and Duodenum normal.

Portae Vein and Branches -

Splenic Vein large - Gastric Vein normal - At the junction of superior esenteric with Splenic the intima somewhat thickened - opaque nd elevated in two places Just above junction of these three branches the vein divides into two main portions - these pass towards the liver and subdivide into 3 or 4 branches - The branch t e right appears to surround common duct - The branches which enter the liver are small but numerous - 10 or 12 in number

iver - small - tissue soft ale brown in color - Wt 990 grammes Lying in one of branches of Portae in is a thrombus - moderately firm t very closely adherent - brownish llow in color and in places opening of the centre

Examination of the softened
edema. It is made up of
granular matter and numerous
leucocytes

337

Purulent Peritonitis

Body that of a short fairly well nourished woman - rigor present - In Abdomen slight ecchymosis of fluid Pylorus is situated below & 1/2 inch to the right of Zyphoid Cartilage - Left Lobe of Liver a hands breadth below Zyphoid Cartilage - On opening Thorax the Pericardium seen to be much distended when opened about 3½ oz of purulent fluid removed visceral & parietal layers thickened & covered with numerous & shaggy masses of lymph - In right Pleura 2 ozs. In left a small amount of turbid fluid. Heart - right chambers contain small clot - valves of right side normal - ~~thick~~ On left side valves a little opaque left ventricle thickened much substance of a pale brown. Parietal Pericardium a good deal thickened, in places 3 to 4 m/m, a good deal of subpericardial fat - particularly at base covered over with irregular fibrinous masses. Lungs - ~~left~~ Right Capital & Apex at upper lobe which is collapsed - some small ecchymosis on the Pleura - Left lung - Collapsed at Anterior border Apex at -

Spleen small weighs 100 grs - presents nothing abnormal

Kidneys a little small - Capsules detaches readily - blood vessels moderately full - small arteries not specially thickened -

Stomach - (Aorta presents some scattered patches of atheroma) looks Bile duct pervious - Lining of mucous coat - contains a good deal of Blood small central veins of lobules large -

Uterus small narrow Polypus fills the canal of the Cervix & projects beyond the OS. attached just above the internal OS.

Nothing special in large intestines -

338

338

Tuberculas Meningitis - Mary B— age 3. ill abot 2 weeks body well nourished - On removg Calvaria - a good deal of blood escaped - Dura Mater adherent at Longitudinal fissure - removg the brain a considerable quantity of fluid escaped. at the base, parts about the optic Commissure opaque matter together with lymph - and the same extends out to the Sylvian fissure, The Arachnoid is pretty clear, numerous Tubercles are seen about the Pia Mater in this situation most of them small, on the right side of the Frontal Lobe there are 2 or 3 small tubercles, size of small peas, as slicing the Brain. the Ventricles are found much distended, the walls softened particularly in the Posterior Cornua -

339 mus m
wt p 58

425-N

Monday Sept. 29.

Gen. Tuberculosis

Child, 2½ yrs old.
Not emaciated; no enlargements of sup. lymph glands
In opening abdomen, found intestines pale, peritoneum
covering them smooth. Liver looks large, numerous
greyish white spots through substance
In Thorax a mass of enlarged glands, size of a large
unshelled almond occupies upper portion of ant
mediastinum lying upon the superior V. Cava.
On removal & incision this is found to be a group
of caseous lymph glands, grey ish-yellow in places,
soft and beginning to break down. A few adhesions
in Rt pleura. Lt lung crepitant throughout, pleura
covered with numerous firm greyish-white bodies.
Many much larger than the ordinary miliary tubercle, others
of them showing all the characters of these structures
On section of lung both lobes seat of disseminated
tubercles, both isolated & in groups, firm & when collected
in small masses the centre has a pale yellowish color
while periphery is more translucent
Bronchial glands of hilus of this lung are moderately
enlarged & caseous. Rt lung also capitient
presents a similar condition. Bronchial glands
much larger on this side than on left; are caseous
Glands at bifurcation of trachea greatly enlarged
at the fork there is a mass as large as a walnut
on Rt side of trachea extending as high as top
of sternum is another mass of similar size

Spleen closely adherent to diaphragm; externally is rough from projection of greyish-yellow nodular bodies varying in size from head of large pin to 8 cent piece
These are all over the surface of organ & there are also some small greyish miliary tubercles on the capsule & on loose fibrous adhesions attached to it.
On section greater portion of substance of organ is occupied by masses of cheesy tubercle, tolerably firm, greyish in color & usually presenting in centre a depressed spot of softening; the organ is considerably enlarged, weighs 70 grammes
Mesenteric glands are moderately enlarged & some of them are becoming caseous
Glands in hilus of liver also enlarged and cheesy
Liver is of full size & presents numerous scattered tubercles chiefly of small size but some are as large as peas. These larger ones present a central cavity, which is filled with greenish yellow bile. Most of them when any size present this peculiar condition
No enlargement of Peyer's glands,
Brain at base great deal of gelatinous exudation & thickening, extending out to olfactory bulbs & post as far as beginning of basilar, it is also very thick out sylvian fissures & pia mater lungs are closely matted together on orbital surface of parietal lobe about 8 Ct. entering to left olf. bulb is a small mass of caseous tubercle 2 X 4 M.M in extent. 2nd small mass on inner surface of occ lobe: lateral vent much distended: walls soft: fornix particularly so also septum.

Fibroid pleura & lung

420 Sept 14th 1880

Body that of average sized but muscular man. Rigor Mortis well marked. Right side of chest looks smaller than left.

On opening Abdomen Omentum found adherent to Ant. wall, partic. in region of transv. Colon, Coils of Small Intestine Slate colored & covered c small amt of greyish white exudation.

Thorax – R Lung firmly adherent & its ant. Edge corresponds c a line a little within the junct. of the Cartilages of ribs c the bone. L. Lung – full in volume & Extends beyond the Middle line, no adhesions on this side

Heart – Gelatin partly decolorized clots in R Chambers. Left ventricle contains small clot, on further dissection R Ventricle looks large. Tricuspid orifice dilated. admits Heart Con firmly. Valves on both sides healthy, one small spot of atheroma in Aortic [illegible] Semilunar.

Peritoneum – numerous adhesions between the coils. One from the Duodenum which united the commencement of Sig flexure. Just above this point the gut looks narrowed & there is

a small cleft at the point of attachment
Towards the Sternum there are numerous
adhesions between the Coils, at the lower
part these become more extensive, the Coils
are matted together & are also firmly adherent
to the Bladder

Lungs: Right Lung - very firmly adherent to chest
wall, only separated by greatest difficulty.
On Section the Pleuritic membrane is found
to be enormously thickened over the lower &
anterior parts of the Lung forming a firm
hard, almost fibroid investment almost
Cartilaginous in density in places it is
fully an inch in thickness & presents
several irregular small patches filled
a whitish fluid. Over the upper
portion of the Lung the membrane is
not so thick & cleft towards the apex
On Section it is found to contain very
little crepitant tissue, at the apex
& narrow Cortical zone about it is fibroid
Scattered throughout the substance are small
Cavities which can be traced to Bron
tubes & some of them represent Dilated Bronchi
the greater portion of the Lung is of a pale
grey with Color in places pink, in others spots
very soft & yielding pus

Left Lung - crepitant throughout. Scattered throughout it are a few nodular masses projecting red in color. Pink looking. on section projecting from the surface. none larger in extent than a quarter

Spleen - firmly united to the Diaphragm soft & slightly enlarged. Kidneys & pelvis Liver is large

Stomach - Mucosa firmly injected. it is somewhat dark colored otherwise natural

Small Intestines - present nothing special lower part somewhat congested

Note. History of illness only a week no definite rigor

427

Sept 12th 1880

Pneumonia

Case

Body that of average size well developed man Skin has icteroid appearance. Abdomen; position of viscera normal. In thorax—effusion in left Pleura turbid and yellow. Pericardium has several well marked spots of striation on right ventricle, right chambers distended with clot. large gelatinous dark in Rt auricle. In Rt ventricle a yellowish decolourized clot firmly adherent and extends into pulmonary artery. Left auricle contains large dark gelatinous clot Left ventricle also contains large decolourized clot firmly adherent to valves.

Left Lung weighs 1520 grammes Rt 720

On further dissection of heart valves are healthy. tricuspid orifice much dilated measuring over 6 inches in circumference. one segment of semilunar [illegible] Mitral orifice 4 $\frac{3}{4}$ inch. a few swollen spots of atheroma in ascending aorta close to coronary artery.

Left Lung lower $\frac{3}{4}$ of pleura is inflamed and covered with thin sheeting of lymph. this becomes thicker at lower & diaphragmatic surface. except anterior $\frac{3}{4}$ of upper lobe Lung uniformly solid & airless On section from apex to base the solidified part found to be in condition of gray hepatization Surface is

is of mixed purple yellow color the substance is friable. The bronchial tubes contain dense purple yellow plugs. The anterior portion of lung is very edematous and in places looks cirrhotic with yellowish stroma
Bronchial glands swollen moderately
Rt Lung crepitant except few spots - at back part of lower lobe. an Action mucous edema at lower and back part less & anterior and upper. & commencing in lower lob
Spleen large weighs 285 grammes soft. pulp dirty yellow brown color and of tolerable consistence
Kidneys natural size nothing unusual noted
Bladder almost empty. Mucous membrane looks normal
Liver large Hepatic Hyperemia & mixed large & small engorged.
Nothing abnormal found in large bowel

Nothing special about Medulla on Section or in any part of Brain

428

Sept 12th 1880

Tetanus

A small wound about 2 centimetres in length & 1½ in breadth over metacarpal bone of 4th toe, covered with greyish exudation.

On 30 August while working on canal ran a pick into his foot causing above wound

On making an incision into wound it is found to extend between 3. 4th metatarsal bones and a pocket of pus situated above the deep muscles of sole of foot about teaspoonful of reddish pus escaped in this this small bit of hairy looking substance probably tow found. There is no direct wound of tendon but ligamentous structure between the metatarsal bone is suppurating

Nothing special in abdomen

In thorax strong adhesions on both sides of pleura

Pericardium slight excess of fluid

Heart right chambers contain large clot of blood. Tricuspid orifice measures over 6 inches in circumference. Left side nothing special found muscle substance healthy.

Lungs crepitant throughout. Spleen normal and malpighian bodies very distinct.

Kidneys large firm contain good deal of blood

Liver firm & has several patches of anaemia on upper surface

Brain very thin skull cap. no excess of serum or cerebro spinal fluid. vessels of [illegible]

58

939

26/4/79

Case. Carcinoma Ventriculi

A. Mc D. æt 53, single woman, with healthy record. Had been ailing for about 3 months with symptoms of dyspepsia. Lately a tumor has been felt in left side epigastric region, low down so that it was suspected to be in the colon. A nodular pad was often felt by one of the phys. Vomiting not constant was a very distressing symptom. No cachexia. Body moderately well nourished. In abdomen organs pale-looking, and about the pylorus end of stomach there is an indurated white appearance. No fluid. no cancer-nodules. In thorax lungs not adherent. heart of average size substance pale, valves a little thick at edges & stiff. Otherwise normal. Lungs quite healthy. Spleen firm, has 4-5 deep notches in anterior border. Kidneys pale, capsules detach readily. Organs of & of natural looking as those of a young person. Arteries just a little more prominent than usual. Liver elongated & flattened having a transverse groove in the upper surface, the anterior border & left lobe being specially flattened & elongated, causing dummy-like appearance that the organ was enlarged. - On section is fatty - moderately. No nodules. Nothing abnormal in small intestines or colon.

Stomach contains ½ pint of half digested milk curd with mucus.

Case. 340 Corrosive Sublimate Poisoning. 29/9/79. 12 h. P.M.

A-B. at 11 drank a small amount of sol. of Cor. Sub. by mistake previously to the 14th. Symptoms of Vomiting, purging suppression of urine for 5 days. Vide Report in Body that of a moderately well nourished child. Signs of inflammation or excoriation about the mouth. Abdomen Liver extends 2 fingers breadth below costal border. & has a granular appearance. No signs of inflam. of stomach or intestines on the peritoneal surface. In Thorax, Lungs. Rt adherent laterally, & at apex; heart & pulmonary chambers contain dark clot & a peculiar dirty muddy-lake colour, & they extend into the vessels. Left cavities empty. Valves & origins normal. Lungs healthy, bronchial glands coarse & mortar breaking down & purulent. Stomach contains about 2 ozs of fluid mixed with curds & opaque mucus, which latter is very closely

adherent to the M. M. This is of a pale grey colour, presenting innumerable fine dark branching lines particularly numerous along the neck: they are due probably to pigmentary changes in the smaller vessels. At Pylorus fine the muscularis mucosæ & the veins are lower part of mucosa are full - no capillary injection. Membrane of normal thickness, no excavations or ulcerations. Pylorus normal. Duodenum, healthy. Small bowel contains a yellowish tenacious mucus & food pieces. Mucosa presents no changes. Large bowel presents numerous diphtheritic patches of a grayish yellow color, situated upon congested areas & extending transversely; most abundant in the ascending colon, becoming more transverse and absent from descending in which there are no scattered patches of injection. The patches are thin 1.5 - 1 M.M. in thickness, not very closely adherent & when scraped off leave a pigment granular looking and vascular surface. None of them appear to involve the entire thickness of the mucosa. There is no ulceration. About the patches the M. is dark red in color. Solitary glands distinct, presenting a dark centre & periphery with an intermediate white zone.

Spleen of average, hard firm & dark. 147. grms.
Liver 1260 grms. looks large & is exceedingly dense & firm, anteriorly, upper surface is finely granular & the capsule in this part is thickened. The surface of right lobe is smooth. On section in antero-post. & left lobe the lobules are very distinct & evidently separated by an abnormal amount of fibroid tissue in the substance of which the vessels are unusually marked. Gall bladder & ducts

natural. Portal vein of average size. Pelleny spots on Gall bladder.
Kidneys Left. 23⅝. Rt. 21⅝. Organs enlarged. Capsules delach readily leaving a smooth chocolate colored ~~organ~~ surface on which no vessels are noticable. On section, substance exceeds morbidly any normal amount of serum, partially blood tinged flows over the section. The tissue looks glistening & edematous. Cortex swollen. Of a light brown color, uniform, neither lines of tubules nor vessels evident. Pyramids of a dusky brown-red color, more vascular.
Bladder contains 4 ozs of dark greenish black urine

Pharynx & larynx removed together. Rt. tonsil lower pt covered with a thin, depph. like membrane. Left & upper part. presents a suppurating spot which has burrowed in the tissue about the organ. Uvula & soft palate injected. Left tonsil also. Larynx pr pm membrane, mucosa, especially about arytenoid cartilages deeply injected

2/10/79

341

Case Cirrhosis of Liver

Age 62 Admitted Sept 27/79 Died Oct 1st

Body that of an old, fairly well nourished man. Belly distended & a little discoloured. Little over large pailful of slightly blood tinged serum removed from peritoneum. Legs oedematous; no enlarged veins prominent. Scrotum slightly distended. In the Thorax about 1½ pints bloody serum in left Pleura. Adhesions on right side. In the Pericardium no excess of Fluid. In right Auricle fluid Blood & Clot and the same in right ventricle. In left auricle is a small clot & left ventricle empty. **Heart.** Muscle substance flabby & pale & looks fatty. Tricuspid & semilunar valves healthy. Tricuspid orifice admits heart cone. ~~fingers~~. Left ventricle, walls moderately thick. Mitral valve a little thickened. Aortic valve thickened at free margin one segment fenestrated. Aorta not dilated & presents numerous patches of Atheroma. **Lungs.** Left crepitant slightly collapsed at base. Right Lung heavy, not so crepitant & very oedematous. Small bony plate in pleura. **Kidneys.** Left average size or small if anything. Capsule detaches readily leaving a smooth surface. Cortex pale not swollen. No apparent increase of fibroid tissue. Right presents similar appearance. No signs of arterial degeneration. **Spleen** large weight grms ℥ 425 Capsule opaque thickened & covered in places with firm cartilaginous plate. Anterior notch absent. On section trabeculae very distinct. Stomach contains about ½ pint of ~~numerous~~ bloody fluid. Mucous membrane blood stained

342 Cerebral Hemorrhage. 1/10/79.

Cirrhosis Hepatis & Nephritis

Case. Weavell

Brain Lining of scalp bloodless, Calvarium moderately thickened. On opening the Spinal Canal moderate amount of blood & the Dura Mater accidentally Cut a large quantity of serum escaped Cranial Vault permanently adherent and brain had to be removed from Cut Cap. Base — Arterial arteries stiff and present patches of atheroma and some two rough Calcareous Coats. Basilar Artery full of blood and partially decolored Clot not adherent to the wall. Its Coats are ~~moderately thick~~ not much thickened. Right Carotid stiff and atheromatous and Contains blood and a fresh clot which Extends into the branches. Ant. Cerebellar. Cont blood Mid Cerebral art full blood vessel vessels over middle Convolutions full and over the lower and outer part of Right lobe of Cerebellum there is atheromatous Deposit Extension

no cirrhosis – the colour of tumor is uniform throughout, veins prominent

~~at abo~~ towards the pylorus somewhat ~~laminated~~ mamullated & here is not stained. Duodenum natural in appearance. Bile flows with difficulty on pressing the common duct & gall Bladder. Hepatic Artery normal. Portal vein thick and on splitting it up a pulpy soft thrombus fills its main branches. It is not adherent to the wall, is of a brownish color & friable. The branches passing to the right lobe of the liver appear almost entirely plugged with a firm yellowish thrombus. Weight of Liver grms 2400

Retains its shape, but ant. notch very deep. Capsule is a little opaque, not much thickened, except at right border where there are strong adhesions. On upper surface of left lobe, & left half of rt. lobe, irregular-shaped cirrhotic areas are to be seen. On the right half of the organ the appearance is quite different, there are numerous greyish white areas slightly prominent, ~~and~~ in places distinct from each other, the intervening spaces being more natural looking. They occupy in larger & smaller masses almost the entire surface of this part & they ~~[illegible]~~ are somewhat of cavernous infiltration. One or two isolated spots are seen on ant. border. On under surface they are confined to ant half, the right & post borders.

On section through the right lobe the rt half presents a remarkable appearance having lost the char. of normal or cirrhotic liver substance. The section is dry mottled in colour, some spots being of a light greyish yellow, others of a deep brownish red. The masses are ~~in~~ part separated by strands of whitish grey connective tissue, but large tracts occur having all the appearance of a tissue infiltrated with blood & in a state of infarction – in fact, quite like areas of infarct in the lung. Some of the spots are becoming of a yellowish colour. This tissue is friable, easily broken down and presents a marked contrast in consistence with the other regions

Branches of portal vein going to right lobe contain ~~a~~ yellowish thrombi, soft

fresh looking and not yet de-colorized. On taking brain out of skull cap Dura Mater intimately adherent. Longitudinal Sinus contains a recent clot, Dura mater removed considerable difficulty and Especially adherent towards frontal region. Pacchionian bodies not specially marked. On looking on superior surface of organ nothing special observable about convolutions. Left side somewhat fuller than the right. On dissecting out Sylvian fissures nothing special noticeable about arteries or convolutions

<u>Section I</u> through anterior part of frontal lobe presents nothing special.

<u>Section II</u> about 2 centimeters in front of ascending frontal convolution, this cuts through anterior angle of lateral ventricle, grey and white matter presents nothing special

<u>Section III</u>. through the bases of frontal convolutions. this exposes the Caudate and Lenticular nuclei no spot of softening.

<u>Section IV</u> through ascending frontal convolution. Inner surface of section

Jejunum contains a quantity of dirty blood still retaining blood tint. Mucous membrane is not blood stained. In the Illeum as far as Illeo-caecal valve there is a quantity dark tarry transformed. Nothing special in large intestines no transformed blood. Bladder normal. Aorta. Thoracic portion contains flakes of Atheroma in the Intima The same is found scattered throughout the abdomonial portion. At Bifurcation of the Aorta the Intima & part of Media are converted into a Calcareous flake. Nothing in the Inferior Cava (Liver Cut), but closely adherent to the wall. In the branch passing to ant. border, the thrombus is firm and in section presents signs of inflammation. Branches of hepatic artery pervious. Hepatic vein normal, no clot in it

the following appearance — on Right side the Lenticular nucleus and Caudate natural look. - on Left side occupying the position of the Caudate nucleus and lying immediately beneath the Lateral ventricle a brownish red Colored Coagulum with long axis transversely 25 m m long - below it rests on optic thalamus and internal capsule. the upper fibres of which look softened and in place homogeneous almost puriform appearance. this condition extends down and involves the upper angle of the outer (outer part) of lenticular nucleus also involved. In this section the External Capsule is but faintly seen and the Claustrum also invisible. The vessels at this spot look dilated and the tissue soft. The grey matter of the central lobe looks healthy

— <u>Section V.</u> (through posterior part of ascending parietal Convolution) In this section the thalamus opticus most prominent. only small part of tail of Caudate nucleus visible. No special signs of softening in this section. On reversing this section the hinder part of the spot of softening is seen. The clot is smaller. presents the

some appearance. The fibres of the Internal Capsule are swollen and have not become so soft as to yield to a stream of water. The upper part of the outer segment of Lenticular nucleus is also involved. Section of (through middle of Parietal lobe) Presents nothing special. Posterior Cornua of ventricle only larger. appendymata a little larger. yellowish

Occipital section nothing special or in the cerebellum. In Pons and Medulla no evidence of a descending Sclerosis. Left anterior pyramid. inner section has a slightly greyish tint

Heart. valves a little thickened at the attached parts. Aorta - a little firmer

Lungs - Emphysematous. particularly at free borders. a good deal of pigment. Upper and posterior part of lower left lobe purulent infarction size of horse chestnut. a good deal of Pigment & coloured over the pleura. Bronchial tubes contain a white. thick. muco-pus. particularly in lower Right lobe - many of the Bronchi here are dilated and on section are to be seen full of pus. quite close to the margin

Liver - Presents an entire posterior edge

groove on upper surface. Substance soft. Capsule smooth, no increase of fibroid tissue. no increase of organ

Left Kidney. Slightly reduced in size Capsule detaches readily. Small cysts at bases of pyramids prominent Considerable fat about pelvis

Right Kidney. Smaller. Pelvis, and Infundibuli much dilated and contain about ounce and one half pus. Pyramids much flattened. The mucous membrane of pelvis rough, congested and lodged in it are two Renal Calculi. One the size of split pea. the other about ½ that size

Bladder. - m m rough. very vascular in spots. also roughened and granular. particularly about prostate. There is one sacculus about the size of a marble the membrane of which

Case. 343 Cancer of Brain 6/11/79. 10 hrs. Pm.

-- Æt. 73. woman. in grey nunnery. Paralysed on left side since June. No satisfactory history. No record of convulsions. Par. came on gradually. Eyes -

Body that of an old moderately wasted woman. Teeth gone; hair grey. Scalp thin - Bones of skull ~~[illegible]~~ average thickness ~~separated~~. Dura closely adherent. On removal of organ, moderate quantity of serum escaped. Base - arach. a little opaque. Basilar & carotids much stiffened & present numerous atherom. patches & same are seen in Sylvian arteries. Pia over convolut. natural looking. On cortex. Pacchion. granulations small. On right parietal lobe there is a swelling and alteration about the gyrus angularis, and the pia strips off readily & leaves this convolution and part of adjoining a little more vascular looking & reddened than the others. Frontal, pediculo-frontal & parietal sections show nothing abnormal, but the lat. ventricles appear somewhat distended. In the ped.-parietal at hinder border of ascend. parietal convolution, the inf. pediculo-parietal fasciculus of fibres is altered, having a pink ~~reddened~~ look, mingled with grey, and the tissue is tougher & firmer than the wh. matter. On section of the remainder of this hemisphere it is seen that a tumour occupies the post. part of the parietal lobe, extending through the whole thickness, and involving on the □ lobe in the inner surface

344

Case: Myo-Sarcoma of Kidney 9/10/79.

A. B. female child at. 3¼. (Dr Fringe) had been ailing for about 6 weeks. slight pain in abdomen. vomiting at first. wh. was easily checked. always somewhat constipated. A tumor was felt in left hypoch. region pointing just below cartil. of 8 rib; quite soft & fluctuating & was thought to be an abscess. Ch. had not been in bed. - At 5 a.m. of 9th. was got up ~~bed~~ walking about when she suddenly dropped down & died in a few moments - choked - the parents said. -

P.M. 11 hrs after death. Body well nourished. On opening abdomen, coils of intestine natural looking, a reddish black tumor projects in lft. hypochr region ~~and~~ just beneath the cartilages, the colon covers it & descends in front. Stomach & intestine removed. - R. K. quite normal. T. is seen to lie behind peritoneum, in situat. of left kidney, occupying the lumbar & hypoch. regions pushing up the spleen & extending forward to the ant. axill. line, in the cost. cartilages. It is about the size of a cocoa oval in shape nut. and was removed easily, with ureter & bladder.

It is large & rounded below. pointed above. where the sp. renal body capsule, It is dark & mottled, on the upper surface; looking even haemorrhagic in spots & no appearance of normal kidney sub. On the under surface, close round the hilus for extent of 3 or 4 cm there is kidney tissue to be seen. Numerous veins course over it in front & at the sides. On dissecting tissue in hilus, artery & pelvis appz normal. R. V. much dilated, walls rougher & irregular having small bits of adherent tissue in its whole course

and close up to V. Cava; A soft pulpy mass exudes from its deeper parts. Ureter is pervious not dilated. pelvis small(?), a probe passes in for a considerable distance. On section through long axis of mass it presents appearance of a rapidly growing soft new growth. The ext. part. above is in part occupied by tissue deeply infiltrated with blood, partly recent, but some of it firm & changing colour. Towards the hilus and on the lower part of the tumour, the exposed surface is greyish white soft & cerebriform in character in places the seat of haemorrhage, in others fatty yellowish. At the upper third. the pyramids of kidney subs. are exposed, the soft growth surrounding them and compressing the calyces. Over the surface of this part of the kidney, a haemorrhagic mass spreads up from below. It measures 15 ctm in length by 7½ ctm in width.

345

Phthisis

Body that of average fairly well nourished man Not much emaciated On opening abdomen, position of viscera normal Thorax. adhesions above & posteriorly in each pleura 2 ounces of serum in pericardium In Heart; fluid blood & partially decolorized clots in all the chambers altogether about 14 ounces of blood removed from the heart. Heart R. Auricle large trabeculae distinct Tricuspid orifice large readily admitting the heart cone Valves a little thick at the edges one section of pulmonary semilunate of Walls somewhat hypertrophied Left. ventricle average size Mitral valve normal orifice 4 3/4 in in circumference Aortic valves healthy. Aorta normal Heart substance soft. paler in color than natural probably fatty.

Lungs. Left. upper lobe with exception of anterior border occupied by a large phthisical cavity, has smooth walls greyish red color trabeculae on the inner surface only pleura over it not much thickened. Tissue of anterior border indurated firm and fibroid containing a few small caseous masses. as a prolongation of tongue like mass of lung from lower & anterior border of upper lobe

lower lobe contains two moderate sized cavities at upper and back part. the rest of the lung extensively & emphysematous and contains a few scattered Cheesy nodules Right lung large volume very & emphysematous Upper lobe at apex contains 2 small cavities the rest of the tissue contains scattered nodules and a few small areas of Infiltration. lower lobe small cavity at upper and back part a good deal of blood & serum in dependant part very few nodules in the lower lobe: Bronchial glands dark colored not caseous Bronchial tubes contain a tenacious mucous. Elastic fibres unusually distinct

Spleen large 380 Grams Pulp soft natural color Kidneys. Right of full size capsule detached with difficulty. on section organ firm tissue coarse moderate amount of blood some of the tubules contain calcareous salt a good many cysts throughout the substance containing a dark colored fluid 240 grams Left Kidney large 340 grams surface covered over with numerous cysts Capsule detached with difficulty On section greater portion of substance of organ occupied by Cysts these vary in size from a pins head to a walnut

Stomach contains quantity of half digested

food ; mucous membrane soft - At the
pyloric end are numerous parallel transverse lines
separating small portions of mucous membrane
and giving to it the appearance of small closely
set folds
Liver large contains considerable amount of blood
chiefly in vessels of Hepatic system

14/10/74

Case. 346 Typhoid fever - perforation

Body, thin - & a small, poorly developed lad. Moderate emaciation -
On opening abdomen lower coils & small intestine covered & flakes & lymph - very slight injection & serous coat - About four ounces & turbid lymph in pelvis - Lower coil & ileum closely matted to caecum & very thickly covered & greenish yellow lymph
Ileum removed & slit up -
Upper part natural looking - no injection
At first half from valve the natural looking patch - next four below it also natural
At first from valve first taken seen occupying upper part & a large brown patch - Another smaller one exists in lower margin & same patch -
Both are oval transversely placed about a centimetre long - slightly dark colored slightly raised - base formed by unusually tissue - Below this are two small patches a little more elevated & dry mucosa between & no injection
Lower seven inches of gut is thickly congested & presents three ulcers

uppermost one. about size of a sixpence
& very deep - shelving & at extreme base
presents a small perforation - about ¼"
in length Base of ulcer covered
thin greyish white pellicle
One inch & half from valve the large
ulcer - 4-5. Centimetres in length
partially divided into three - Edges are
undermined - & ulceration is extending
latterly - base formed by Muscular tissue
Third circular one size of a pea with
still near valve & close to mesenteric
edge - One or two small ones near valve
Caecum is a little injected
in places - no ulceration

Kidneys - Left - capsules detach readily
renal stellate prominent - substance
pale - Other Kidney same
Spleen 15-3 grms - Moderately firm

Heart normal - Muscle fibre little pale
Lungs - Base congested very oedematous
L. crepitant throughout
Liver - full size pale - probably fatty
Stomach contains a greenish bile stained
fluid - Muc - Mem. normal
N.B. Large amount of lymph in pelvis

19/10/79

Case. 3464

Body that of a short stout woman. P M lividity in dependent parts and about face & legs. Pelechiæ (?) on abd. Rig. mortis present. On preliminary incision panicula adiposa very thick. In abdomen large quantity of fat on mesentary and momentum. In Pelvis body of uterus more toward right side In Chest adhesions in both Pleuræ. Small amount of Effusion. Right auricle distended with jelly like clots Colorless at upper part. In Right Ventricle same sort of clots as in Rt auricle. Left Ventricle contains a very small amount of blood. 20 Ozs of blood collected on preliminary inspection of heart. Nothing abnormal in right side of Heart- Left heart. slight atheroma about the attachments of Aortic semilunar Mitral Valves healthy

Splen small, pulp natural

Kidneys of average size capsule detached readily, substance healthy

Lungs. Left. slightly crepitant- lower lobe heavy. sodden & intensely oedematous right lung. pleura covered with a peculiar gelatinous infiltration chiefly covering lower part of upper lobe and there are small extravasations. base of this lung not specially oedematous though the surface is bathed with a moderate amount of oedema.

Stomach. nothing abnormal

Liver large yellowish brown ~~colour~~ Color

3 100 Grams

elongated from before backwards On section
exceedingly pale & anaemic, pinkish portions of
the lobules yellowish Organ evidently very fatty.
Uterus nothing special Ovaries much puckered

347

Case. Mortus Cordis. Oct 26th 1879.

body that of a large framed man, ~~subject~~ general anasarca,
arms more dropical than legs, Scrotum immensely distended.
On opening abdomen coils of small intestine greatly distended
covered here and there with flakes of Lymph & in places a good
deal congested, 6 or 8 ounces of clear fluid in Peritoneum - he was the
subject of a Hernia - signs of old peritoneal Inflammation - On opening the Thorax -
the Heart in Pericardium occupies & unusually large space - adhesions to both
Pleura very small amount of fluid in these sacks In Pericardium a few
ounces of Serum In Right Auricle fluid Blood & large gelatinous clots
in Right Ventricle semi-fibrinous clot adherent to the valves Left Auricle
full of dark gelatinous clots Left Ventricle also contains dark gelatinous clots.
Altogether about 250 g of Blood & clots collected from the Chambers of the heart -
Right Auricle large. trabeculae a good deal developed. Right Ventricle
greatly dilated & hypertrophied Length for Pulmonary ring to Apex 15 Centimetres
along anterior wall Circumference nearly 19 c.m. Thickness anterior wall
5 m.m. in other places reaches to 8 to 10 m.m. Trabeculae much developed

Tricuspid orifice admits the Hand Cone freely. Pulmonary valves a little opaque one segment- penetrated Pulmonary Artery slightly atheromatous- the artery also looks dilated Measures close upon 10 C.M in circumference. Aortic orifice incompetent - Left Ventricle has a somewhat rounded outline & when opened Chamber very large measures for aortic ring to Appt 10 C.M. in circumference 18 C.M. Musel substance thick - measuring from 15 to 18 M.M. Anterior Papillary Musels large Posterior very moderately developed, both are fatty Columnae Carnae moderately developed Musel substance pale, fatty- Mitral Valve - thickened at the free edges. orifice admits the Hand Cone with slight difficulty - Aortic orifice 10 C.M. in circumference along the tops of the Valves - Right Anterior Valve small crumpled & foreshortened- measures scarcely 10 M.M. along ventricular face it is thickened and at its junction with the posterior segment has a stiff calcareous projection which prevents the portion of the valve next it from being pressed against wall of the vessel- Posterior segment much thickened especially at free edge 20 M.M. along ventricular face. Left Anterior Valve also thick at the edge measures 16 M.M. along face, at its junction with Posterior Segment there is a long stiff calcareous projection occupying the ~~bottom~~ border of valve & also preventing it being pressed back against Arterial wall Orifice of Right Coronary Artery quite 10 C.M above margin of valve Left only 1 or 2 M.M. Coronary Artery slightly atheromatous - right a little more so - Aorta ascending portion moderately dilated 10 C.M in circumference intima thickened rough very atheromatous - Numerous reddish spots, soft denuded of epithelium & soft atheromatous substance occupies the spaces. Left Auricle Large - Endocardium thick - Weight of Heart with arch of Aorta attatched - 970 grammes Kidneys not enlarged Capsules slightly adherent substance firm the portion between the Cortex & pyramids

natural the small arteries not any prominent. renal artery large & wall thick small artery size of a crow quill enters the Kidney substance in anterior upper surface Left Kidney, paler than right. Right 303 Left 313 Weight of Kidneys. Liver. two superficial grooves across upper & Anterior part of right lobe projects - veins of the Hepatic System. full Weight of Liver 1800 grammes Spleen Small capsule opaque substance natural looking - Weight of Spleen 115. Lungs. Left very slightly crepitant - on section rusty brown color throughout tissue characteristic color of brown induration Right Lung. heavy, contains but little air - same state as Left. branches of Pulmonary Artery down both small subdivisions present numerous atheromatous patches Bronchial Tubes stiff bands of plastic tissue very prominent the mucous membrane very much reddened. Descending Aorta extensively atheromatous in its entire length. Nothing special in Intestines -

Case. 348 Elephantiasis

Body fairly well nourished. Skin pale. Right leg large and presents, as described in clin. Report, a no. of cysts lymphoid excrescences chiefly on the thigh, inner surface and on the pool.

On abdomen, 900 g of milky fluid in peritoneum. Omentum & mesentery fatty, fat rather firmer than normal one or two milky patches in peritoneum over mesentery. Liver is small & cirrhotic. In thorax, right lung intimately adherent to chest wall, left only by a few bands. Pericardium united to heart, & had to be removed with it, membrane not much thickened, a good deal of fat on outside. In apex over left heart, [redacted] two layers of pericard, have not united

Rt. aur. & vent. contain dark clots. chambers normal. Left vent. one small clot. chamber of full size not hypertr., muscle substance dark brown. Valves a little stiff & aortic semilunar, atheromatous at attached edges. Asc. aorta presents a few flakes of ath. & at lower part of arch is a calcar. plate.

Lungs, crepitant throughout, contain a good deal of blood and serum in dependent parts.

Kidneys a little large, cortices slightly swollen.

Spleen double normal size. capsule opaque; tissue firm.

Liver reduced in size, surface rough & granular from the presence of innumerable small nodosities

Portal vein of full size, admits index finger into right branch. Duct. normal. -Artery. do. Gall bladder contains a pale yellow bile.

Stomach. large. Mucosa slate coloured, pinkish at fundus. Not mammill. but tolerably tough. Two small tumours size of peas in ant. wall of fundus.

Intestines present nothing abnormal. Peyers patches not visible a yellowish coloured ~~fluid~~ substance ~~clay~~ mark in them

Thoracic duct dissected out appeared quite normal. no dilatation. Receptac. chyli of natural size, branches leading

to it not distended. A longitudinal section was made across Popliteal by. along front of thigh to knee, and the femoral vessels dissected out, Surrounding femoral vein inside were 4-5 enlarged and dark looking lymph glands, not compressing the vein: the branches seen entering these glands are not enlarged. The femoral artery is exceedingly stiff & atheromatous - Same on the left side. It is much more so than the iliac or the aorta. The section exposes at least 1½ inches of fatty tissue, the lobules of which are very distinctly seen each one surrounded by a gelatinous looking, infiltrated tissue, and quantities of serum mingled with fat oozes from the cut surface. There is a considerable increase in the connective tissue which can be seen as opaque white band passing between the fat lobules. The skin itself is thickened and there peculiar button like projections do not extend beyond its limit. (A section should be made out by careful dissection (no dilated lymph vessels). The thickness of the infiltrated panniculus diminished greatly by the loss of serous fluid

349

Case. Typhoid Fever Perforation

Body that of a small well nourished woman.
Int. Abdomen. Sup. coils of intestines a little injected
Lower coils of Coecum & caput Coeci covered with
lymph - the latter free - not adherent as usual at post
Surface. Ileo Append. Vermi. passes vertically down and
is attached by lymph to lateral wall of the pelvis.
Lower coils of Ileum matted together and cover-
ed with greenish yellow lymph
In Thorax no adhesions in Pleurae - Small amount
of Peri Cardial fluid. - Rt. Ven. Cav. small amount of
fluid blood. Small amount of blood in other chambers
Heart. Small - nothing of note in Rt. Chambers -
Rt. Lft. Heart valves normal. - In Aortic Semilunar one
seg. punctured. - In Pulmonary Semilunar one seg. punctured
- Muscle substance pale - Weight 190 grs
Lungs crepitant throughout - a little heavy and
dense post. ly. - contain a slight excess of blood
& serum - Bronchial tubes filled with a dirty
mucid secretion.
Spleen enlarged - tissue moderately soft. - Wt. 270 grs
Kidneys - Pale cortices - some larger vessels
full - nothing else of note.
Ileum. When slit open - moderate amount
of greenish yellow feces. - Upon post. does not

Montreal General Hospital.

MEMORANDA FOR THE PATHOLOGIST.

Case Typhoid Fever

Name Mary J. Crotten Age 24

Date of entry Oct 23rd Date of death Nov 1st 79
6.30 P.m.

Brief History

Illness began four weeks ago as general vague disturbance of health & stomach. Took to bed 14 days ago. Epistaxis. Fever. No diarrhoea until purged a week ago. Very profuse then & since.

Chief Symptoms

Not been great nervous prostration. Signs - Atonic. Quiet low muttering delir. & great tremor.

Temperature range

100 - 105°F. & 105½°F.
Two hours before death: 108°F.

(Signed) James Bell

---

present … -
first p … valve-
In it … first
Fig. exami … then is
a serie … to sege
of 6. d. … soft
grey iole … muscle
fibres.- … Evenly
ulcerated … parsely
-bases … me of
three … ~~to a line~~
is sm … length
Edges … ulcers
adherent … ove
extend … remaining
valve … covered
— In … deep red
with … cated food.
color.-
Stom
Pylorus
Pancr
Liver … ty brown
color

Aorta presents patches of atheroma. - numerous patches of fatty degeneration beneath the intima

349

Case. Typhoid Fever Perforation

Body that of a small well nourished woman.
Ileo Cæcal Valve. Sup. coil of intestines a little injected
Lower coils of Colon & caput Coeci covered with
lymph - the latter free - not adherent as usual at post
Surface. Ileo Append. Vermi. passes vertically down and
is attached by lymph to lateral wall of the pelvis.
Lower coils of Ileum matted together and cover-
ed with greenish yellow lymph
In Thorax no adhesions in Pleuræ - Small amount
of Peri Cardial fluid. - In Rt. Lung. small amount of
fluid blood. Small amount of blood in other chambers
Heart. Small - nothing of note in Rt. Chambers -
In Lft. Heart valves normal. - In Aortic Semilunar one
Seg. punctured. - In Pulmonary Semilunar one seg. punctured
- Muscle substance pale - Weight 190 grs
Lungs crepitant throughout - a little heavy and
dense post. ly. - contain a slight excess of blood
& serum - Bronchial tubes filled with a dirty
mucid secretion.
Spleen enlarged - tissue moderately soft - Wt. 270 grs
Kidneys - Pale cortices - some larger vessels
full - nothing else of note.
Ileum. When slit open - moderate amount
of greenish yellow feces. - Upon post. does not

present any ulceration – glands not swollen –
Just patch effaced about 1½ inch above valve –
In it little glands swollen & at top part just
beginning to ulcerate – In ascending part there is
a series of small ulcers – from size of 3d. to size
of 6d. Edges swollen – pores filled up with soft
grey pale white matter – thus composing the muscle
fibres. – Last 4 inches of ileum most extensively
ulcerated – 3 large ulcers – flat – extend transversely
– fibres of muscular coat. – In middle of one of
these at about 1½ in. from valve ~~about to valve~~
is small perforation about line & half in length.
Edges of ulcers swollen covered a greyish
adherent substance. – The lowest of the 3 ulcers
extend almost entirely around just just above
valve only two small bridges of mucous membrane
– Its outer surface found slightly congested covered
with lymph – at ~~right~~ side of perforation of deep red
color. –

Stomach contains a quantity of half digested food.
Pyloric Zone much mammillated. –

Pancreas – nothing special

Liver average size – tissue soft of dirty brown
color

Aorta presents patches of atheroma. – numerous
patches of fatty degeneration beneath the intima

88

Montreal General Hospital.

MEMORANDA FOR THE PATHOLOGIST.

Case Phthisis

Name Mary Ann Todd Age 32

Date of entry Sept 25th Date of death Nov 1st 79
6.20 P.m.

Brief History Ill for 14 years Cough Expect
Expectorate.

Chief Symptoms Cough purulent expectoration
loss of flesh & strength. Lividity & dusky appearance
of depend parts

Temperature range
98 - 100°7.

(Signed) James Bell M.D.

Rt. Vent dilated. from Pul. ring to apex 11. c.m. -
Circumference of Rt. Vent 17. c.m. — Valves
normal — one seg. of Pul. valves fenestrated.
Walls thick — Col. carneæ strongly developed.
Fenestrated clots observed in interspaces between
them - particularly at apex — measure from 5
to 8 m.m. in thickness. Left Vent. much smaller
than Rt. 8 c.m in length = 11.5 in circum. -
Walls 8 to 10 m.m. thickness. Mitral orifice
4½ in. in circum. Valves normal — Aortic semi
lunars — on Rt Post seg - Vent face. is of
tolerably recent organization. (2) two of its pins
are pedunculated & loose — the left Post. has
also a small sessile vegetation also on
Vent surface

Rt. Lung. Crepitant below. — Upper part nodular
& firm - at post part of apex is a cavity
the size of a good sized apple. — Walls of cavity
rough - lined by greyish mass. — Crossed by trabeculæ
Ant. Portions of upper & middle lobes crepitant
& oedematous tissue about bronchi & vessels
greatly increased. — Lower lobe upper part
contains numerous groups of small firm
whitish bodies — tissue about these pigmented.
Left lung. cavity in Post part of upper lobe.
walls irregular — greater portion of this lung
crepitant - only a few scattered tubercles in

Case 350 - Phthisis. Admd
- Todd. private at 32.

Stomach large - contents much lower than natural -

On Thorax. Heart occupies large space - Pericard. fluid slightly in excess. - Strong adhesions in Rt. Pleura - in Left R. adhesions chiefly behind. -

Rt. Lung crs with dark, moderately firm coagula. - Left Lung same sort of clots - Left Pleura also dark coagula.

Heart - Rt. Ven. somewhat hypertrophied - tubes very distended - Tricuspid orifice 6-3/4 in. in circum.

Rt. Vent dilated. from Pul. ring to apex 11. c.m. —
circumference of Rt. Vent 17. c.m. — Valves
normal — one seg. of Pul. Valves fenestrated.
Walls thick — Col. Carneæ strongly developed.
Fenestrations in intervening spaces between
them — particularly at apex — measure from 5
to 8 m.m. in thickness. Left Vent. much smaller
than Rt. 8 c.m in length = 11.5 in circum. —
Walls 8 to 10 m.m. thickness. Mitral orifice
4½ in. in circum. Valves normal — Aortic Semi
lunars — on Rt Post seg — Vent face. is of
tolerably recent organization. (2) two of its pins
are pedunculated & loose — the left Post. has
also a small sessile vegetation also on
Vent surface

Rt. Lung. Crepitant below. — Upper part nodular
& firm — at post part of apex is a cavity
the size of a good sized apple. — Walls of cavity
rough — lined by greyish mass. — Crossed by trabeculæ
Vent. Portions of upper & middle lobes vicinity
fibroid & fibrous tissue about bronchi & vessels
greatly increased. — Lower lobe upper part
contains numerous groups of small firm
whitish bodies — tissue about these pigmented.
Left Lung. cavity in Post part of upper lobe.
walls irregular — greater portion of this lung
crepitant — only a few scattered tubercles in

upper lobe. – Bronchial glands dark colored – not caseous. – Bronchial tubes somewhat injected & thick. –

Intestines in some what injected up. at upper part – no ulceration – no peyers patches visable

Stomach contains a quantity of dirty fluid. Inner mucous co. ant. wall & lesser curvature an immense deprived spots – looking like loss of substance – no injection of tissue about them – some are round others irregular – about the size of split peas. Some of these spots have red dish black base & resemble hemorrage in erosion.

Liver – left lobe & ant. border of Rt. L. pushed in surface & present numerous fine granulations – fibrous tissue throughout increased – Wt. 1140 gr.

Kidneys – small – nothing special – one cyst size of small marble – capsule easily detached. –

Spleen – average size – four small supplimentary spleens. –

Uterus. Normal size in supply injected almost hemorrage at fundus. –

Aorta. not atheromatous. – No plugging in femoral. – Internal Iliac on Rt. side contains colloidably firm thrombus. –

Case 351 Chronic Meningitis

Spinal Cord. Spinal Canal opened & moderate amount of Blood at upper portion. Veins in ant. pt. particularly Lumbar region full. Dura M. torn slightly in Lumbar region on removal. Arachnoid is exposed & is distended with fluid yellowish in Color & is opaque. The opacity is more or less General but is most marked in the Lumbar enlargement and on Dorsal region In places the membrane is quite matted to the Pia M. and is much thickened along a ridge passing down the Centre of the Post surface from about the Cervical enlargement downwards. Then is a definite layer of lymph upon the Pia of Lumbar enlargement and the filaments of the Cauda Equina are loosely matted together by this same On the Ant. Surface of lower Lumbar region a layer of lymph is very thick
This matting and opacity of the Arachnoid is most marked on the ~~Anterior~~ Posterior chain

Montreal General Hospital.

MEMORANDA FOR THE PATHOLOGIST.

Case Paraplegia

Name William Maxwell Age 62

Date of entry Oct 2nd Date of death Nov 7th 79
12.15 Am

Brief History

Old Paraplegia Gradual
Rect

Chief Symptoms

Lately. Urination. Cough & febrile
attacks

Temperature range

98 - 104°7.

(Signed) J Mills Bell

Brain. Arteries at the base, atheromatous
Middle Cerebral on both sides dilated

Case 351 Chronic Meningitis

Spinal Cord. Spinal Canal opened & moderate amount of Blood at upper post. Veins in ant. pt. particularly Lumbar Region full. Dura M. loose slightly in lumbar region on removal Arachnoid is exposed & is distended with fluid pearly white in Color & is opaque. The opacity is more or less General but is most marked in the Lumbar enlargement and in Dorsal Region In places the membrane is quite matted to the Pia M. and is much thickened along a ridge passing down the Centre of the Post surface from above the Cervical enlargement downwards. Then is a definite layer of lymph upon the Pia of Lumbar enlargement and the filaments of the Cauda Equina are loosely matted together by the same On the Ant. Surface of Lower Lumbar Region a layer of lymph is very thick
This matting and opacity of the Arachnoid is most marked on the ~~Anterior~~ Posterior Chain

on the ~~Post.~~ Ant. Surfaces. In Sections cervical region about middle enlargement Post. Med. Columns greyish in Color & translucent other Cols. appear natural looking. this Condition persists in upper dorsal though less distinctly marked & there appears to be in this part and abnormal translucency of the Right post lateral Cerebellar tract. As the Centre of Dorsal region is approached the glistening appearance of Post Med. Cols. disappears the lower dorsal region Columns look natural. As the Lumbar Enlargement is approached a greyish translucent area appears in the Right lateral Column in the situation of the Crossed Pyramidal fasciculus In the Lumbar swelling itself the grey matter is somewhat pinkish towards the margins of Post Cornua the outlines are ill defined, the white Columns look laterally natural

Brain. Arteries at the base, atheromatous Middle Cerebral on both sides dilated

Pia mater and arachnoid, opaque. Veins moderately full

Heart. Large amt. of fat on surface of pericard. 2 layers of this membrane adherent in places by firm fibrous bands. Sub Pericardial fat very abundant. In Pericardium, at base of R. Ventricle are two Calcareous plates and there is a third at hinder part of L. Ventricle. Muscle substance of Heart, extremely friable, that of R. Ventricle particularly so. It is pale, often mottled and looks fatty. Valves are healthy. Fenestration in both Aortic & Semilunar valves.

Kidneys. Small, surface a little granular. Capsule adherent. Moderate number of Cysts throughout substance. Small arteries not very distinct.

Spleen. Small. Pulp soft. Weight 80 grammes.

Lungs. Emphysematous at anterior border. Atheroma. Good deal of Carbonaceous matter.

332

Case. Typhoid Fever Hæmorrhage. 7/11/79

M. R. at 16 a stout well developed M. A. D. cm. p. 38.

Montreal General Hospital.

MEMORANDA FOR THE PATHOLOGIST.

Case Typhoid Fever

Name Madison Russel Age 16

Date of entry Nov 2nd Date of death Nov 7th 79
1.4 Am

Brief History

Always healthy until.
Sunday Oct 21st 79 When present illness
began
Chief Symptoms

Typh. Fever - has diarrhoea. Suddenly
Coming out 24 hours before death. Sudden and
alarming hæmorrhage - (Glandular) blood from which
he has rallied - Blood directly from lung blood
Temperature range

104 - 105

(Signed) J. Mc Bell

Pia mater & arachnoid, opaque. Veins moderately full

Heart. Large amt. of fat on surface of pericard. 2 layers of this membrane adherent in places by firm fibrous bands. Sub Pericardial fat very abundant. In Pericardium, at base of R. Ventricle are two Calcareous plates and there is a third at hinder part of L. Ventricle. Muscle substance of Heart, extremely friable that of R. Ventricle particularly so. It is pale, often mottled and looks fatty. Valves are healthy. Fenestration in both Aortic & Semilunar valves.

Kidneys. Small, surface a little granular. Capsule adherent. Moderate number of Cysts throughout substance. Small arteries not very distinct.

Spleen. Small. Pulp soft. Weight 80 grammes.

Lungs. Emphysematous at anterior border. Atheteris. Good deal of Carbonaceous matter.

352

Case. Typhoid Fever Haemorrhage. 7/11/79
M. R. at 16 a stout well developed lad. M. A. D. ca. p. 38.

On opening Abdomen upper coils of intestine look natural. lower ones dark colored from the presence of blood in the interior — When intestines removed & ileum slit up lower foot & a half contains slightly altered blood. Caecum & Colon contain a dark reddish black blood. Above the valve the mucous membrane extensively ulcerated for a couple of inches. hardly a trace of natural mucous membrane remaining. About 6 ctm from the valve there is a large circular patch of ulceration measuring 5 × 4 centimetres. The edges are swollen the surface dark colored much ulcerated 2 or 3 of the ulcers being very deep. And it is probable that from one of these deepest ulcers that hemorrhage has arisen. 10 ctm further up there is a smaller circular patch presenting the same character. The intervening mucous membrane containing many swollen solitary glands. Some of which are ulcerated. The next 40 ctm of the mucous membrane is studded with swollen glands the majority of which have ulcerated on the surface. The upper portion of the ileum presents three oval patches which

form irregular ragged ulcers - Ileum presents one small ulcer. Nothing of note in jejunum -

Spleen - Greatly enlarged 450 grammes - On section Pulp soft. Malpighian bodies moderately distinct On cutting at one point hemorrhage was found to have taken place in the tissue beneath the capsule The same is noticed in two other spots of little [illegible] Kidneys ~~considerably~~ extremely anaemic otherwise natural looking -

Stomach natural looking - Liver large. Moderately firm. tissue of a dirty brown color - In several areas particularly a large one near right border the tissue presents a mottled appearance - part of the lobules being deeply injected - the portions being of an opaque white -

Heart - Right chambers contain blood & soft clots. Left ventricle firmly contracted and empty. Valves normal - The segments of aortic semilunar fenestrated.

Lungs Congested & oedematous. at Posterior Part
& Good deal of blood.

353

Care. Typh
Am. in C. at
Body Fat of a
An opening at
In Thorax no
fluid blood, a
fibrinous clot
contents. Noth
substance a le
Lungs: Left- Hepat
Right Lung cr
ains very little
of Pneumonia.
Spleen. Super
marble. Organ
consistency, w
Kidneys: A
ains a great de

Uterus average
looking Vessels
small vessels

Montreal General Hospital.

MEMORANDA FOR THE PATHOLOGIST.

Case Typhoid Fever

Name Ellen McGuinness Age 17

Date of entry Oct 7th Date of death Nov 16th 79
11 P.M.

Brief History

Always healthy. Until present illness

Chief Symptoms

Typhoid Fever. Diarrhoea & great hæmic prostration Delirium & Hæmatemesis

Temperature range

101°7. - 106°7.

(Signed) James Bell

form irregular ragged ulcers - Ileum presents one small ulcer showing & little disposition to repair -

Spleen - greatly enlarged 450 grammes - on section pulp soft. Malpighian bodies moderately distinct on cutting at one point hemorrhage was found to have taken place in the tissue beneath the capsule the same is noticed in two other spots of little [illegible]

Kidneys ~~ex extremely~~ extremity anaemic otherwise natural looking -

Stomach natural looking - Liver large. Moderately firm. Tissue a dirty brown color - In several areas particularly a large one near right border the tissue presents a mottled appearance - parts of the lobules being deeply injected - the portions being of an opaque white -

Heart - Right chambers contain blood & soft clots. Left ventricle firmly contracted and empty. Valves normal - The segments of aortic semilunar fenestrated.

Lungs Crepitant throughout. at Posterior Part c̄ Good deal of blood.

353

Case. Typhoid Fever. 11/11/79

Ann. M C. æt 17th.

Body ~~that~~ of a small, fairly well nourished young girl. On opening abdomen, position of organs normal. In Thorax no pleural adhesions. In Right Auricle fluid blood, and one thin clot. In right Ventricle pale fibrinous clot and fluid too. In left Auricle, similar contents. Nothing of special note in the heart; muscle substance a little pale.

Lungs. Left dark coloured and collapsed at the base. Right Lung very heavy, dark coloured posteriorly, contains very little air, lateral part

of Pneumonia,

Spleen. Super

marble. Organ

consistency. w

Kidneys: A

ains a great de

Uterus average

looking venia

small vessels i

(1) Feb. Phthisis –
(2) Ch. Meningitis
(3) Fract of skull.
(4) Memb. Croup. –
5 Typhoid fever –
(6) Emphysema –
(7). Cirrhosis of liver –
(8) Cardiac abnormality
(9) Small. tumour of face
(10) Carcinoma of breast.

form irregular ragged ulcers - Caecum presents one small ulcer. Nothing of note in jejunum -

Spleen - Greatly enlarged 450 grammes - On section pulp soft. Malpighian bodies moderately distinct on cutting at one point hemorrhage was found to have taken place in the tissue beneath the capsule the same is noticed in two other spots of little [illegible] Kidneys ~~exceedingly~~ extremely anaemic otherwise natural looking -

Stomach natural looking - Liver large. Moderately firm - tissue a dirty brown color - In several areas particularly along the near right border the tissue presents a mottled appearance - parts of the lobules being deeply injected - the portions being of an opaque white -

Heart - right chambers contain blood & soft clots. Left ventricle firmly contracted and empty. Valves normal - the segment of aortic semilunar fenestrated.

Lungs Congestion & Oedema at Posterior Part
A good deal of blood.

353

Case. Typhoid Fever. 11/11/79

Am. in C. at 12 Mt.

Body that of a small, fairly well nourished young girl.
On opening abdomen, position of organs normal.
In Thorax no pleural adhesions. In Right Auricle
fluid blood, and one thin clot. In right Ventricle pale
fibrinous clot and fluid too. In left Auricle, similar
contents. Nothing of special note in the heart; muscle
substance a little pale.
Lungs: Left, dark coloured and collapsed at the base.
Right Lung very heavy, dark coloured posteriorly, contains very little air, lateral part of upper lobe, in a condition of Pneumonia. The section of it is dark coloured, granular.
Spleen. Supernumerary Spleen present the size of a marble. Organ not much enlarged. Pulp of moderate consistency. weight 1953
Kidneys: A little aff; cortex swollen, Right organ contains a great deal of oo

Uterus average size, dark coloured, and congested looking beneath the serous coat. Other natural looking small vessels injected. Ovaries large, containing numerous

Graafian follicles, several of large size. several stellate yellowish cicatrices of Corpora Lutea

Intestines upper part of illium Peyer's patches are swollen, mucosa about them, injected, surfaces reticulated, five or six patches in this condition. "first ulcerated patch is met with about a foot and a half from the valve, is irregular, superficial, and only extends to the submucous tissue. In the succeeding foot of bowel, are six or eight ulcers, ranging in size from a threepence to a shilling, edges are dark somewhat elevated, bases formed of submucous tissue. except in one instance, the last six or eight inches of bowel is injected, and presents many irregular ulcers. none of them oval in shape, but irregular and with sinuous borders. The greater part of the superficial layers of the mm is denuded. The muscular coat is only exposed in one or two places. The valve ileo-cæcal presents several small ulcers on its lips, the Cæcum presents 15 or 20 ulcers, small, round, and with grayish infiltrated bases. several of them exist just at the entrance of the appendix.

Stomach contains some yellowish fluid, mm soft and mammilated, at cardiac end there is post-mortem solution of the superficial layer

100

Case 354 Membranous croup

Re-printed from "The Canada Medical & Surgical Journal," December, 1879.

CROUP OR DIPHTHERIA, WHICH?

By William Osler, M.D., M.R.C.P., Lond.

Professor of the Institutes of Medicine, McGill University; Physician to the Montreal General Hospital.

On Monday morning, Nov. 10th, 8.30 a.m., I was hastily summoned to the Infants' Home by a message that a child was dying. On arriving, I found Fritz, a well grown boy of 4½ years, in a state of urgent dyspnœa, and rapidly becoming cyanotic. I was informed that the child had had a slight cold on Sunday, but had been about, and had taken his food as usual. In the evening the matron noticed that he was somewhat restless in his cot, breathed rather heavily, and had a "croupy" cough. Towards morning he became worse, and he was put in a warm bath, and had mustard applied, with considerable relief. At 7 a.m. he got worse, and they again tried the ordinary remedies, but without affording any relief. I found him in the state above mentioned; breathing very laboured; cold sweat on the forehead; skin livid; extreme restlessness; and on inspection of chest, there was seen retraction of lower zone and epigastrium. The child had had a somewhat similar attack about three months before, and another last winter, and has always been regarded as "croupy"—*i.e.*, on taking cold had a cough with a peculiar "bark" or ring. A younger brother died of croup. Seeing that no time was to be lost, I got Dr. Shepherd to perform tracheotomy, which afforded prompt relief; the breathing became quiet, and the natural colour was restored. Pulse full and strong. When the trachea was opened, we could see quite plainly a thin layer of false membrane on the posterior wall. After the operation, the fauces

Case 55-5 . Emphysema. 9-11-79.

Name Catherine Boyde
Body That of an Old Woman
Rigor mortis Present to a slight extent
Chest – Barrel Shaped, deep Constriction in Antr-lateral part of Thorax – On Abdmn exposition Viscera Normal – Intestines distended with Gas –
Lungs – They meet and overlap in middle line & project beneath the Sternum. Few adhesions at Right Apex.
Heart – Remarkably Globular in shape – Over Right Ventricle

Case 354 Membranous croup

were thoroughly inspected, and appeared natural; no swelling; no exudation. There is no enlargement of cervical glands. For a couple of hours the child was easier. When seen at 1.30 p.m., respirations were hurried, 60 per min.; pulse, 140; and temperature high. At 5 p.m., condition the same. Tube was cleansed of muco-pus, but respirations continued very rapid. Colour good. Takes milk well. At 9 p.m., very restless; respiration, 55; pulse over 140; skin hot and dry. Has passed a small amount of urine, but it had not been kept. Has been vomiting a good deal. Mr. Rogers kindly watched the child during the night; it was restless at times, and kept feverish, but seemed, on the whole, somewhat easier. At 9.15 a.m. was weaker: pulse almost uncountable; respirations over 60; temperature, 105°. Tube is clear. Unfortunately the nurse had, in spite of instructions, failed to keep any urine. Death occurred at 1.30 p.m.

Autopsy.—Face suffused; lips and finger-tips livid. In thorax, lungs do not collapse. Right side of heart and great veins gorged with blood. Pharynx, larynx, trachea and lungs removed together. Uvula and soft palate somewhat suffused. Tonsils not enlarged, and of good colour: at upper and back part of left there is a small greyish-white patch, 2×3 m.; near it are two open follicles, with a little exudation in them. In right organ, three follicles are filled with greyish-white soft material. No membrane on pillars of fauces, or on upper surface of epiglottis. Entire larynx is filled up with a greyish exudation, which lines the under surface of epiglottis, the true and false chords, and the arytenoid cartilages, completely closing the *rima*. It can be lifted as a definite membrane, tolerably compact, but loosely composed on its surface. Thickness about 2 m. From the larynx it extends into the trachea as a continuous sheeting as far as the incision. The tissue beneath it is deeply congested and somewhat granular-looking. From the lower margin of the tracheal wound, it extends down the tube into the bronchi, and can be followed in the latter to branches of the third degree. The membrane here is not so consistent, and is more difficult to remove as a continuous sheeting. Mucosa beneath deeply injected. *Lungs*, crepitant in front, dark-coloured, collapsed and congested behind. At hinder part of right upper lobe the tissue is very firm, and in spots granular—pneumonic. *Heart:* right chambers gorged with blood and jelly-like clots; great veins distended. *Spleen* a little enlarged; pulp not very soft. *Kidneys* much congested; on section, blood drips from the surface. No special alteration of substance noticed. Nothing of note in gastro-intestinal tract.

Microscopic examination of grey patch on right tonsil showed a network of fibrils, with numerous round cells, leucocytes, and granular débris. The exudation in follicles of left tonsil appeared softer, and was made up chiefly of very closely-packed corpuscles. In the membrane from the larynx the same elements were found: meshes of fibrin-fibrils, large and loosely arranged, with round cells and epithelial flakes. Here and there groups of micrococci were met with, and some of the cells contain isolated forms. They are not, however, specially abundant, and the same elements occur in numbers on the fur of the tongue. The kidney epithelium was granular, and in cortical tubes swollen. No micrococci found. The capillaries were very full.

Remarks.—Croup or diphtheria, which? I believe it to be the former, for the following reasons: (1.) The sporadic nature of the case; the child had not been exposed to contagion, and no cases subsequently developed in the Home, although the conditions for the spread of the disease are most favorable.* (2.) The mode of attack, and locality first affected. Up to a couple of hours prior to the first symptoms the child appeared in his usual health, though suffering from a slight cold. The difficulty in breathing came on very early, and was the prominent feature throughout; the larynx was primarily affected. Before the effect of the chloroform had passed away after the operation, the fauces and tonsils were most carefully examined by Drs. Ross, Shepherd and myself, and no membrane seen, not

* Up to the time of the operation the child was in the same room with about a dozen children, from 3 to 5 years of age. Subsequently, he was isolated.

even injection. (3.) The absence of swelling of the neck and fetor of breath, symptoms rarely missed in severe cases of diphtheria. (4.) The situation of the exudation ; primary laryngeal diphtheria is very uncommon. On the other hand, the slight extension in the tonsils in this case does not invalidate the croup view, as in this disease the membrane may also occur in the fauces. The extension of the membrane into the tubes does not tell much either way ; it is seen in both affections. In 17 cases of diphtheria, of which I have *post-mortem* records, extension of the membrane in the trachea and bronchi occurred in eight of them. (5.) The absence of signs of septic poisoning at the *post-mortem*. The blood was clotted and natural-looking, no staining of walls of vessels or of tissues about them ; only the usual conditions met with in death from asphyxia. (6.) The absence of micrococci in internal organs, especially the kidneys. Their presence in the exudation in larynx does not go for much, when the same elements occurred on tongue. They were not in the same numbers as in diphtheria, in which they swarm in the membrane. (7.) The fact that the child had been subject to "croupy" attacks, two of which were accompanied with dyspnœa and lividity. A younger brother also died of croup.

Croup I believe to be a non-specific inflammatory affection of the laryngo-tracheal tract, accompanied with a membranous exudation. It is never contagious, is usually sporadic, and rarely occurs in adults. Kills by asphyxia ; never by blood-poisoning. Is a local disease, the constitutional manifestations being those of impeded respiration ; is never followed by paralysis. There is never fetor of breath, or swelling of glands of the neck. To this picture the above case corresponds in its essentials.

the Pericardium is injected - Visceral Layer, lower part is covered with small extravasations - The same are abundant over Left auricle - Right Aur contains large Clot colorless at its upper part, dark Colord below - Right Ventricle contains a colorless Clot - Chamber is moderately enlarged - Tricuspid Orifice measures nearly 5 inches in circumference. Mucous Lining pale & Soft very slightly hyp. Left Aur normal - Left Ventricle greatly hyp. Walls measure from 1/4 to an inch in thickness. Chamber from Aortic & mit. to Apex 3 inches in length. Mitral Valves thickened at edge - Orifice about 4 inches in circumference - Aortic Valves also are thickened particularly at attached borders. They are competent - Aorta, moderately atheromatous One large Patch exists just above Right Coronary Artery.

Lungs - Extensively emphy particularly at Anterior Border - They do not collapse & present usual appearance of Organs in this condition. Bronchial Tubes filled w a Semifluid mucous - Mucous Membrane of Trachea & Bronchi very florid & dark colord -

Spleen average size - Pulp normal.
Kidneys - Small - Capsule detaches easily - Surface of Organs a little granular - Small Arteries not very prominent Renal is not particularly stiff - Walls not atheromatous Cortex perhaps a little diminished -

Liver Small. Dark Colored - Soft, tears easily - It is elongated in Antero posterior diameter

Gall Bladder Projects - Has sort of One for 2 inches beyond the Margine - It is dilated - Some what puiforme in Shape & is filled with a Clear Serum and contains 2 Gall Stones One size of Walnut The Other the size of Large Marble & is lodged in the Crifice of the Cystic Duct -

Stomach - It contains nothing abnormal - Some slight Post - Mortem Solution of Mucous Membrane - Vast much atheroma of Aorta & no dilatation -

Uterus - Small - Os is reduced to a Small Crifice the size of Pins head - Ovaries almost completely Atrophied - On the Sigmoid Flexure projecting from its Serous Coat are a number of Rounded Cahulform Bodies - They are Connected with Some of them Contain faeces & they appear to be Sacular Dilatations of the Mucous Membrane

21/11/79

356

Case. Typhoid Fever

8½ hrs p.m.

Alice F.. at 25. death from haemorrhage from bowel.

Body that of a fairly well nourished woman. Lips and skin of face a little livid. In Abdomen, transverse colon distended with gas. Intestines pale.

Thorax, no fluid in the pleura. Few adhesions on Rt side and none on the left.

Heart, Left Auricle, fluid blood & brown coloured soft clot. Similar coagulum extends into Left Ventricle. Left Ventricle empty.

Valves of heart normal. Muscle substance very pale and anaemic.

Lungs crepitant throughout, a little dark colouring in dependant parts.

Spleen enlarged weighs 250 grms. Tissue consistent. but is of a dark chocolate brown colour

Intestines, affection is confined entirely to lower two feet of the ileum. Upper portion is pale. 1st affected patches are within 2 feet of the valve. Patches elongated irregularly ulcerated. Edges of ulcers swollen & injected. Largest amount of ulceration occurs 1 foot from the valve where there is extensive area 2 inches long greater part of which is ulcerated. Base of ulcer are formed in part of musc tissue. Some present a thin lymph membrane. Close to valve are 4 or 5 irregular ulcers, but the tissue about them

Montreal General Hospital.

MEMORANDA FOR THE PATHOLOGIST.

Case Typhoid Fever

Name Alice Nott Age 25

Date of entry Nov 1st Date of death Nov 25th '79
6.15 P.M.

Brief History Healthy until attack of fever. Which was a mild course up to two or three days before death.

Chief Symptoms Headache - Moderate fever. Eruption - no diarrhoea - no tympanites but tenderness (moderate) and [illegible] Profuse Haemorrhages two days before death -

Temperature range Meteorism Tympanites and high temp. - 105 F. for 24 hours before death
100 - 105½

(Signed)

James Bell

Dark co

Old

Stoma P.M.

Colu healthy

Kidne daily

Organ about the

Base of

Liver

Mesen branches

Inne soft

Uterus

ed to

Pu

21/11/79

Case. 356 Typhoid Fever

89 hrs p. m.

Alice. F. at 25. death from haemorrhage from bowel.

Body that of a fairly well nourished woman. Lips and skin of face a little livid. In Abdomen, transverse colon distended with gas. Intestines pale.

Thorax, no fluid in the pleura. Few adhesions on Rt side and none on the left.

Heart, Left Auricle, fluid blood & brown coloured soft clot. Similar coagulum extends into Left Ventricle. Left Ventricle empty.

Valves of heart normal. Muscle substance very pale and anaemic.

Lungs crepitant throughout, a little dark colouring in dependent parts.

Spleen enlarged weighs 250 grms. Tissue consistent but ~~as~~ of a dark chocolate brown colour

Intestines, affection is confined entirely to lower two feet of the ileum. Upper portion is pale. 1st affected patches are within 2 feet of the valve. Patches elongated irregularly ulcerated. Edges of ulcers swollen & injected. Largest amount of ulceration occurs 1 foot from the valve where there is extensive area 2 inches long greater part of which is ulcerated. Base of ulcers are formed in part by muscular tissue. Some present a thin sloughy membrane. Close to valve are 4 or 5 irregular ulcers, but the tissue about them

dark coloured and segmented.

Colon & Caecum are pale. Stomach
Stomach contains small amount of fluid, P. In
solution in deposit at bottom, otherwise healthy
Kidneys Cortex Jab Capsule detach readily,
organ has a good deal of blood in vessels about the
base of the pyramid
Liver Pale Blood exist in large portal branches
Mesenteric glands are swollen, Moderately soft
Some of them stuff congested.
Uterus normal size, Mucous membrane is
swollen.

357

Typhoid Fever.

Body that of an average size, fairly well nourished man. Rigor Mortis present.
In abdomen, position of viscera, natural.
Thorax no adhesions in pleura.
In Pericard. slight excess of fld.
In Rt. chambers of heart fld blood & one small clot (veins of neck cut much blood oozed out)
Left vent. globular & empty
Rt vent normal Tricuspid orif. dilated 6cm
valves normal. 1 Segment of Semilunar penetrated
Walls of left vent. look thick - measures from 12 to 15 mm in thickness. Length of Chamber 7½ Centim.
Muscle sub. pale mod.
Aortic Semilunar valves normal. 1 Sg. penetrated
Aorta appears narrow. - measures only 5·4 m m in circumf 1½ from valve.

Rt. Lung. Pleura at posterior lateral part of upper lobe and along edges of middle & lower lobe are numerous ecchymoses. Similar seen at root of lung surrounding bronchii vessels. Post part Upper lobe & extreme base are airless. In former on section the tissue is greatly infiltrated much serum & blood oozes and at edge is an area of diffuse extrav. of blood
Lower lobe at base is collapsed
Rt Lung. Crepitant throughout, as lower edge are several subpleural extrav.

Bronchial Glands. not enlarged
Spleen 380 grs. Soft. reddish brown.
Left Kidney. Large 220 grs Rt 180
Capsule detaches readily. On section
tissue coarse looking. good deal of blood
in cortex & alternate lines of tubules vessels
very distinct Apices of both & pyramids pale
Liver is large. 2,400 grs.
Subcapsular ecchymoses. On section
entire area of lobules full. tissue coarse
looking soft. lobules look swollen tubes
Stomach contains dirty grayish-brown fld
Intestines. Jejunum pale. Upper part of Ileum
Solitary gland slightly swollen
Ileo Cæcal Valve patch as distance of 1½ ft from
valve. Patch consists of 2 portions. swollen
infiltrated appear. Slough beginning to form
& is stained yellowish. 3 in from it is patch
much swollen deeply congested, from
upper part a slough has separated exposing
Peritoneum which from outer side looks
yellowish & almost necrotic
Next patch, 1 ft from valve covered & yellowish
slough in process of separation. Edges much swollen
& congested. Three in. from valve is fourth patch
Slough of which is separated exposing muscle
below is base. Edges infiltrated and yellowish color

On lip of talus are 3 small patches in process of sloughing. On caecal lip is small superficial ulcer.
In Caecum is an ulcer 20 x 10 m m.
Solitary glands well marked in Ascending Colon. Solitary glands of Small bowel not much swollen
On left side of aorta thoracic portion is extravd blood, and beneath the pleura particular that covering bodies of vertebra are numerous extravs
The Aorta appears small
Mucous membr. of Bladder normal

358

Mary Ma

Body that
On openin
mal, no flu
bowels dilated
~~side~~ pleura.
of heart, wa
dilated. Mea
L. ventricle e
shows pale
heavy and
little carbo
very soft,
test pale s
vessels i
worn paler,
Intestines
with faeces,
2½ in. in
a condit
swollen and
sent the stomach has separated in irre-
gular ways, the solitary glands are also
swollen, some of them deeply congested.

Montreal General Hospital.

MEMORANDA FOR THE PATHOLOGIST.

Case Lobular Pneumonia

Name Mary Murray Age 25

Date of entry Nov 20th Date of death Nov 25th/79

Brief History

Three weeks Intemperate habits

Chief Symptoms Nervous prostration delirium
typhoid fever and death from collapse
without pain

Temperature range

102 - 103° F.

(Signed) J. Wm Bell

Please Coroner - Body must be removed by 4 o'clock train and Grant hall everything put in order before friends arrive or business to be done today

On lip of valve are 3 small patches in process of sloughing. On caecal lip is small superficial ulcer.
In Caecum is an ulcer 20 x 10 m m.
Solitary glands well marked in ascending colon. Solitary glands of small bowel not much swollen
On left side of aorta thoracic portion is extravd blood, and beneath the pleura particular that covering bodies of vertebra are numerous extravs
The Aorta appears small
Mucus membr. of Bladder normal

Typhoid Fever.

Mary Machiay Age 25, Date of Entry Nov. 20th

Body that of a large well nourished woman, On opening abdomen, position of viscera normal, no fluid in peritoneum, intestines pale, large bowels dilated. In thorax no adhesions on either ~~side~~ pleura. Heart - Fluid blood in right chambers of heart, walls relaxed, tricuspid ~~valve~~ orifice dilated. measures 5 1/2 in. Left chambers normal. L. ventricle empty. Valves normal, muscle substance pale. Lungs — crepitant throughout, heavy and congested at bases, they contain very little carbon. Spleen large, weighs 400 grammes pulp very soft, dark coloured. Kidneys — left cortex pale small veins only prominent straight vessels of pyramids full, right kidney is even paler, cortex swollen and opaque looking Intestines — Ileum contains quantity of yellowish faeces, at the valve there is a large patch 2 1/2 in. in length the surface of which is in a condition of sloughing, edges of patch are swollen and to the greater part of its extent the sloughs have separated in irregular ways, the solitary glands are also swollen, some of them deeply congested.

there are two or three sloughs immediately on the lip of the valve, up the ileum there are nine oval patches each about from 3/4 to 1 in. in length; much swollen projecting to a considerable distance on the surface, the margins of some over-lapping, the lower ones are congested and on their surface present loose, shreddy sloughs, uppermost patches have not ulcerated. The solitary glands have a good deal swollen and project like small buttons from the surface.

Mysenteric glands are greatly swollen, tissue soft and pulpy. Liver - of average size tissue is soft of a muddy brown colour large veins only contain blood. Stomach - contains a quantity of curds. fundus of the organ is dark-coloured a tenacious mucous is adherent to it. duodenum and jejunum normal. Uterus and Ovaries - Mucous membrane of the uterus natural looking, ovaries are of full size. one spot on the right, a yellowish dot which on section is found to be continuous with the remains of a corpus luteum. at the upper part of this ovary, there is a corpus luteum containing a central clot of a brownish red colour together with some reddish serum.

Montreal General Hospital.

MEMORANDA FOR THE PATHOLOGIST.

Case

Name Mrs Shea Age

Date of entry Dec 9th Date of death Dec 9th 11.30 Am.

Brief History Friends have not knowledged any existing illness

Chief Symptoms Friends have not observed any symptoms - dropped dead without having left room an hour before in apparently perfect health

Temperature range

(Signed) J Mundell

Have secured all of my with kind kindness and have pledged myself that they can have the body at 3 Pm tomorrow without any visible sign of dissection

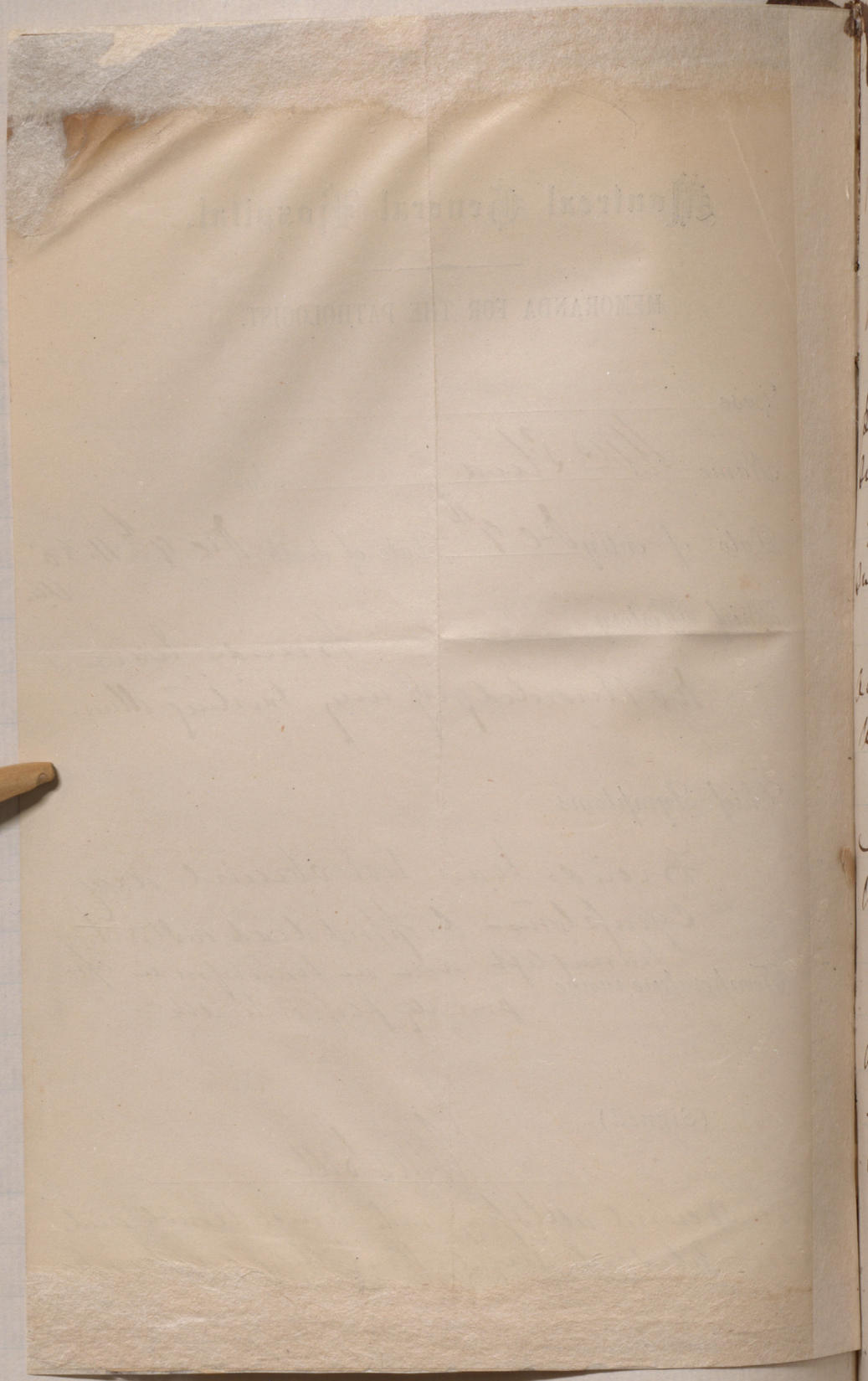

359

Aneurism of Ant. Communicating artery

al.

Body that of a well nourished woman – Nothing particular noticeable on external inspection – Rigor mortis present.

In Abdomen – Lacteal vessels beautifully marked on intestines & mesentery. –

In Thorax position of viscera normal. – Pericardium normal – **Heart** weighs 340 grs. normal size. Rt chambers full of blood – valves normal Tricuspid tr. 5½ in. in circumference – muscle substance good color. –

Lungs – Left. crepitant throughout – At apex small adhesion. – Here beneath it a firm caseous mass encapsuled in fibrous capsule –

A good deal of blood in dependent portion – **Right Lung** – almost universally adherent crepitant throughout

Spleen wt 200 grams – Substance normal

Kidneys wt. Rt 160 grs. Lft. 150 grs – Capsule a little adherent – Surfaces slightly granular – Substance uniformally injected & blood organs of a deep red color – Rt Kidney is unusually movable.

Brain. Not excessive quantity of blood in Skin. – On removal of Skull cap.

Con. on page 115

Continued from Page 115

June 1st. 1930 – left lobe annulo elongated into towards left & posteriorally making two flat elongations. –

Continued from Page 113

Dura Mater looks natural – Dusk color of pia mater evident through it – Longitudinal Sinus empty (Head was opened after thorax) – On removal of Dura M. extravasation is seen beneath the arachnoid along the longitudinal fissure & extending from it ~~along~~ down the sulci –

The fronto parietal convolutions esp on left side are flattened. – Along both the Sylvian fissures & the bounding convolusions are these clots most marked in sulci. – The extravasation extends over ant. part of frontal lobe.

On removal of organ there presents a uniform coagulum extending from the medulla behind to the olfact. bulbs in front filling up the space beneath the basilar process & extending along the lateral & under surfaces of the cerebellum – out the Sylvian fissures & along the longitudinal fissure. –

The Medulla looks somewhat flattened and wedged in between the lobes of the cerebellum

Continue on Pg 114

360

Morbus Brightii

Jean Reynaud.

Dec. 19. 97

Age. — Date of entry Oct 12th. Died

Body that. of an emaciated aged man, general anasarca, left leg greatly swollen. covered with bulla. Both legs stained In abdomen several pints of clear colored serum. Intestines pale. (Body still warm, rigor mortis just beginning) Nothing special about position of viscera In Thorax no fluid in pleura: pleuritic adhesions on both sides: pericardium contains 2 oz clear serum: Heart: left ventricle greatly contracted: Coronary veins full Right auricle distended with large gelatinous clot: that portion of it in superior part is decolorized: for more than one inch in thickness: this decolorized part covered over with thin sheeting of dark red colored clot. which is in close contact with the endocardium. In right ventricle is a firm leathery clot closely adherent to the chordae & trabeculae In Pulmonary artery the clot is decolorized in upper part Left & Right auricle contains fluid blood (small quantity) Heart altogether contains a large amount of blood.

Right chamber enlarged in size: one in two the columnae carneae are fibroid: tricuspid orifice 4 1/4 inches in circumference.

Valves healthy. Left ventricle is hypertrophied. Chamber measures from apex to ring 9 cm. Walls from 15 — 20 m.m. in thickness: substance a little pale. ~~Posterior~~ papillary muscle very fibroid at apex. ~~Anterior papillary~~ Muscle. &c &c

In Post segment of mitral valve there is a hard calcareous projection situated on ventricular surface at junction of the valve with the heart muscle, extending along the surface of the valve, in its central part. Keeping the valve in the horizontal position. On either side of this end mass the valve is quite normal, edges not thickened.

Aortic sem. valve, a little opaque, one segment penetrated: one small ath. mass. Aort a healthy. At post. surface of left Vent, a whitish patch 3 by 2 cm, ~~also~~ is seen beneath the pericardium. A section of this at it is seen to be a patch of fibroid degeneration. The tissue firm whitish, like ordinary fibrous tissue, in the neighborhood of it is ~~found~~ interspersed with muscle substance. ~~Left~~ Lung crepitant without ~~Heart weighs 4 5~~ Right. Bronchial tubes contain a quantity of mucus. Pulm. artery when slit up contains clots. In one hand going to upper lobe it is firm, decolorized & closely ad-

herent to the wall. In main branch going to lower lobe there is also a firm partially adherent thrombus. It occupies the primary subdivisions & is very closely adherent.

Left Lung also crepitant. Pulm art. also contains clots, tolerably firm, rest is decolorized but firmly adherent at points of division

Spleen. a little large, substance ~~of~~ healthy. At anter part of upper border is a convex bulging triangular shaped yellowish body. In section it is soft but not diffluent & is evidently the remains of an old infarct. 2 cm — length by 1½ — depth

Kidney (Right) fully capsule moderately thick: when removed a large pale organ is revealed. About the middle of ant. surface is a clear cyst. The Capsule is opaque, not adherent. In removal general surface of organ is opaque (an opaque white), mottled by the presence of irreg. dist. vessels etc. In section cortices of a dead white in places but swollen in other spots the pyramids approach the surface. The cortex is of a remarkably homogeneous appearance, very anemic, not presenting any trace of the medullary rays

Weighs 270 grammes.

Left Kidney also large. On section, organ presents same appearance as the Rt. In the cortex can be seen numerous round, somewhat indistinct opaque white bodies. Ureters and Bladder normal.
{Left Kidney. Same weight as the Rt.}
{On Rt side of Oesophagus about middle of its course lie two large pigmented glands}
Stomach. pale. Mucous membrane thin.
Duodenum unfilled with Serum especially the subcutaneous tissue.
Liver. hepatic art. presents 2 or 3 patches of Atth
Portal vein, normal. Liver a little cirhotic at ant. Edge. otherwise normal. Aorta presents very numerous patches of Atth. some very translucent & cartilaginous like especially at bifurcation of small last arteries.
Brain. Duramater natural looking. Arteries at the base somewhat Atth. Good deal of Serum about the membranes.

361 Pneumonia

Body that of an old poorly nourished man
On opening abdomen the ileum projects a handsbreadth
below the costal border.
On opening thorax adhesions on both sides
Heart
of average size. Rt Auricle contains a large gra-
ulous clot decolorized at upper part. Rt Ventricle
full size; tricuspid orifice dilated admits the hand
cone; valves normal and left side mitral valves a little
thickened at the edges, the aortic semilunar valves
normal; muscle substance of deep brown color. Weight
of heart. 315 grms Spleen a little large; capsule
at one part opaque; pulp normal.
Lungs. Left weight 1950 grms. Organ of large volume
Crepitant only in lower half. On section from apex
down the following condition is presented The su-
perior apex is in a condition of intense edema
The surface section being bathed with abundant
frothy serum. The greater part of the upper lobe
exposed on this section is mottled varying in
color from a greyish white interspersed with
redish and haemorrhagic spots to a condition
in the lower part more resembling true
hepatization. The surface is bathed with a pinkish
tint fluid, which towards the base is much
blood stained. In the upper part numerous
small granules can be seen. In this region

Montreal General Hospital.

MEMORANDA FOR THE PATHOLOGIST. ~~3rd~~

Case Pneumonia

Name Harry Wright Age 26

Date of entry Nov 25th Date of death Dec. 6th 6 a.m. /79

Brief History

Chief Symptoms

Apex Pneumonia about three weeks ago. gradually extending over greater part of left lung. Delirium Restlessness high fever & finally some consolidation of right base

Temperature range

102- 104.7.

(Signed) James Bell

---

they are
reddish
scattered
and at
anaemic
The centr
irregular
contents.
edaemat
Right
Emphy:
anterior
Bronchi
Kidne
Left
a wall-
Aorta
Intestin
Lower
spots or
mammal
downwa

ion
ation
lobe
ure
e small
ular
ly
ii
id
size
estine
fibroid
ent
above

Pneumonia

Body that of an old poorly nourished man
On opening abdomen the ileum projects a handsbreadth
below the costal border.
On opening Thorax adhesions on both sides
Heart

of average size. Rt Auricle contains a large gra-
ulous clot decolorized at upper part. Rt Ventricle
full size; tricuspid orifice dilated admits the hand
cone; valves normal and left side mitral valves a little
thickened at the edges, the aortic semilunar valves
normal; muscle substance of deep brown color. Weight
of heart. 315 grms Spleen a little large; capsule
at one part opaque; pulp normal.

Lungs. Left weight 1950 grms. Organ of large volume
Crepitant only in lower half. On section from apex
down the following condition is presented The su-
perior apex is in a condition of intense edema
The surface section being bathed with abundant
frothy serum. The greater part of the upper lobe
exposed on this section is mottled varying in
color from a greyish white interspersed with
redish and haemorrhagic spots to a condition
in the lower part more resembling true
hepatization. The surface is bathed with a pinkish
fluid, which towards the base is much
blood stained. In the upper part numerous
small granules can be seen. In this region

they are grey. In the lower lobe they are more reddish. There are several spots of extravasation scattered throughout the tissue in the upper lobe and at the anterior border the tissue is more anaemic. There are several spots of softening in the central portion of the upper lobe. There are small irregular very ragged uneven walls and purulent contents. The posterior base of lung is extremely oedematous and congested

Right lung. Weighs 650 grms.
Emphy: at lower borders; tissue is dry in anterior part moist and oedematous behind
Bronchial glands enlarged

Kidneys

Left Kid: 210 grms. On cutting into a cyst it the size a wall-nut deeply placed.

Aorta

Healthy.

Intestines nothing to be noted on large intestine Lower end of oesophagus contains some firm fibroid spots on the mucosa. Stomach mucous membrane mammalated. Liver much flattened from above downwards; weighs 2270 grms. Organ firm

382

Hyp. of Right Heart.
Chr pleurisy

Body that of a fairly well nourished man - No oedema - Veins of the legs somewhat distended particularly the smaller branches - Face & hands slightly cyanosed. On opening Abdomen Liver seen projecting a hands breadth below the ribs. -

The Stomach presents a peculiar constriction about 4 inches from the pylorus & has in consequence an hour glass shape -

In Thorax both lungs closely adherent to chest walls - Heart. Rt Auricle contains much fluid blood - Rt. Vent full of soft dark clots - Left Vent almost empty an inconsiderable quantity of fluid blood escapes from heart & vessels - In Rt Auricle very large Musculi Pectinati greatly developed - fibrinous clots exist in the meshes between them. - Tricuspid orifice about 6 in. in circumference - Valves a little thick at the free edges. - Rt Vent. dilated & hypertrophied - measures 5 inches from valve to apex - The Col. Carnae very large & thick - Intermediate walls 8 to 10 m.m. thick - Muscular substance tolerably good color.

Left Vent small as compared with Rt. 3/4 in from valves to apex - Mitral valve a little thick - walls softer than Rt. better if any hypertrophy. - muscular substance pale - Mitral orifice 4½ in. in circumference weighs 330 grains

Rt Lung – Pleura thickened – on section deeply engorged c̄ blood – At Post. part very oedematous. – Between the two layers of Pleura behind is a layer of gelatinous oedema ½ in thick. – Organ very slightly crepitant – Bronchi full of thick reddish fluid – membrane very dark in color Pulmonary arteries large & present spots of atheroma Index finger can be introduced to 2nd point in main branch.

Left Lung – same characters as right Around the branches of the Pulmonary Artery are small ulcerations –

The anterior margin of the lung are emphysematous. –

Spleen small capsule thickened – tissue firm & hard. wt. 165 grams.

Kidneys average size – capsules thin & detach readily – on section normal amount of cortex Malpig. bodies uniformally injected – small arteries going to cortex also distinct – Renal tissue between them of natural color – St. vessels of Pyramids full – venae stellatae not marked. – ~~Left~~ Rt Kid. 180 grs – Left kidney organ is moderately firm – arteries not thickened

Stomach – somewhat distended – thick glary mucous covers the surface. – Mucosa reddish in color – hourglass constriction disappeared when stomach was laid on table

Liver small – Capsule fibroid in spots. – wt 1350 grs

Central veins & Capillaries greatly engorged —
— Aorta presents a few spots of Atheroma —
— Intestines — slightly abnormal. —
— Vessels at base of brain normal

363 Arthritis of liver 2/1/80

Body that of an average sized man; face & upper extremities emaciated; belly greatly distended legs as high as upper part of thighs oedematous Scrotum distended; left side of dorsum sloughed skin at posterior part of thighs and legs dark-coloured; penis sloughed on dorsum and left side. Somewhat over a large pail full of fluid, claret coloured, is removed from Peritoneum On opening abdomen, small bowels shrunken general Peritoneal surface opaque; a rich plexus of veins exist beneath the Peritoneum over both Kidneys and along the parietal Peritoneum in the flanks. This plexus is particularly dense over right kidney and lumbar region — Lower zone of Thorax distended; liver falls down from contact with thoracic wall — On opening Thorax, left

Montreal General Hospital.

MEMORANDA FOR THE PATHOLOGIST.

Case Cystitis Phthisis

Name John Lowe Age 35

Date of entry Dec 18th 79 Date of death Jany 6th 80

Brief History

Chief Symptoms

Temperature range

94 - 107.

(Signed) J Allan Bell

lungs is
lung clo
On upper
unusually
about th
Two veins
accompa
and emp
The cha
large gel
and deco
Left aur
ventricle
Clot — A
of heart,
but is p
valves are
inches in
a little hea
right lu
apex so
Spleen
It is not
Kidneys flattened, capsules detach easily
substance a little coarse. In left organ there
are two small spots like infarctions —
Stomach contains half digested food —
Mucous membrane pale

Central veins & Capillaries greatly engorged —
— Aorta presents a few spots of Atheroma —
— Intestines — slightly abnormal. —
— Vessels at base of brain normal

363 Cirrhosis of Liver 2/1/80

Body that of an average sized man; face & upper extremities emaciated; belly greatly distended legs as high as upper part of thighs oedematous Scrotum distended; left side of Dorsum sloughed skin at posterior part of thighs and legs dark-coloured; penis sloughed on Dorsum and left side. Somewhat over a large pail full of fluid, claret coloured, is removed from Peritoneum On opening abdomen, small bowels shrunken general Peritoneal surface opaque; a rich plexus of veins exist beneath the Peritoneum over both Kidneys and along the parietal Peritoneum in the flanks. This plexus is particularly dense over right kidney and lumbar region — Lower Zone of Thorax distended; liver falls down from contact with thoracic wall — On opening Thorax, left

lung is collapsed and not adherent; right lung closely adherent to chest wall
On upper surface of Diaphragm there is an unusually dense plexus of veins particularly about the oesophageal end of the Stomach
Two veins about the size of crow quills accompany the Phrenic nerve at right side and empty into the Innominate vein
The Chambers on Right side of Heart Contain large gelatinous clot continuous into the vessels and decolourised at upper part —
Left auricle Contains a similar clot. Left ventricle contains a small partially decolourised Clot — Nothing special noticeable about Chambers of Heart, valves normal — Aorta looks large but is perfectly healthy. The Aortic semilunar valves are large; tricuspid orifice over six inches in circumference; Crepitant throughout a little heavy and oedematous posteriorly. In right lung the Pleura is thickened. At the apex some dark fibrous bands extend in
Spleen not much enlarged, weighs 200 Grammes It is not unusually dense.
Kidneys flattened, Capsules detach easily substance a little coarse. In left organ there are two small spots like infarctions —
Stomach contains half digested food —
Mucous Membrane pale

Mucosa pale. In Gastro Hepatic Omentum the portal vein is normal, it is not narrowed, it admits the index finger into right branch The Hepatic Artery is large - Gall Bladder is distended but on pressure Bile flows out from the Papilla Biliaria
Liver weighs 1700 Grammes
Common duct is dilated no apparent narrowing at any part The dilatation extends to the branches in the Liver — Liver subst. extremely firm, surface irregular presenting numerous coarse nodules which are themselves covered over with fine granulations
Intestines very redundatous, otherwise very normal

Case 364 . Typhoid Fever. admitted. Nov 25th Died. Jan 3rd. 4/1/80

Body that of a small feebly developed
woman
and toler
also over
arm bu
small i
places
under
up the li
do not c
no adhes
Heart _
is seen
clot close
& passing
Left Auric
Valves nor
Aortic & se
trifid larg
Rt Ventric
pale, Smo
not much

Spleen
weighs 95

Montreal General Hospital.

MEMORANDA FOR THE PATHOLOGIST.

Case Typhoid Fever
Name Bella McNeil Age 35
Date of entry Nov 25th 79 Date of death Jany 3rd 80 7 P.M.

Brief History

Present illness began about ten days before admission

Chief Symptoms — Old typhoid Symp. Fever gradually disappeared and about two weeks ago began to suffer from bladder irritation & then retention. Has catheterized twice three times. Has lately been passing 20-24 oz daily of smoky dark urine. Containing clots and of blood - grew worse to death

Temperature range

95 - 104 7.

(Signed)

James Bell

Mucosa pale. In Gastro Hepatic Omentum the portal vein is normal, it is not narrowed, it admits the index finger into right branch The Hepatic Artery is large - Gall Bladder is distended but on pressure Bile flows out from the Papilla Biliaria
Liver weighs 1700 Grammes
Common duct is dilated no apparent narrowing at any part The dilatation extends to the branches in the Liver — Liver subst. extremely firm, surface irregular presenting numerous coarse nodules which are themselves covered over with fine granulations
Intestines very redundatous, otherwise very normal

Case 314 4/12/80

Typhoid Fever. admitted Nov 25 died Jan 3rd.

Body that of a small feebly developed woman Small ecchymoses in upper and lateral regions of left thigh and also over vaccination mark in left arm On opening abdomen coils of small intestine dark colored in places Hepatic flexure of colon lies close under the right lower ribs and pushes up the liver On opening chest lungs do not collapse they meet in median line No adhesions

Heart In right Auricle a gelatinous clot is seen In right ventricle a fibrinous clot closely adherent to the trabeculae & passing up into the Pulmonary artery Left Auricle contains a dark loose clot Valves normal One segment of both Aortic & mitral valves fenestrated Transverse diameter large 5½ inches in circumference Rt ventricle a little large Muscle substance pale Lungs Congested throughout not much blood in them

Spleen not enlarged firm weighs 95 grammes

Kidneys weigh 180 grammes

Rt 1

Kidneys not enlarged On section the substance is pale Pelvis and calyces covered with a thick opalescent membrane from 2 to 3 millimetres in thickness which is very extensive occupying the entire membrane and extending to the upper part of Ureter

Right Kidney

Affection of pelvis not nearly so extensive membrane is confined to one patch in the lower and anterior part about the size of a ho'penny.

Bladder is full of a dirty greyish substance thready in character There is also a considerable portion of dirty sloughing membrane about 3 millimetres in thickness The true membrane of bladder is in great part covered with a thick greyish white exudation most extensive in the lowest Zone In the upper part the masses are isolated they project from 2 to 3 millimetres on the surface At the orifice of the urethra there is a large membranous flake and

the tissue about the orifice is quite haemorrhagic In the upper part of the organ the true membrane is dark gray in color but not covered with membrane

Vagina The greater portion of mucosa covered over by a thick greyish white membrane It is chiefly at the sides and on R side it ends to the OS covering part of its margin Towards the lower zone of vagina the membrane surrounds almost the entire canal

Intestine

Ingesta contains a brownish yellow viscous substance which gets darker towards the stomach In stomach there are about seven dark looking patches all of a dark blackish red color at the base Those about the last 4 inches of the gut are very small and are in process of cecatrization one or two of them have already healed Lower 4 inches of gut presents 3 patches, uppermost one is still open edges elevated deeply

congested the base very dark covered
with a thin greyish pellicle
Surrounding the valve the membrane is very
dark colored and there are one or two
patches in process of healing

Stomach
Contains a greenish fluid nothing
special about the membrane

Liver
A little soft and contains a good deal of
blood particularly in the portic vessels

365 Acute Otitis 18th Jan 80.

Case. Purulent Meningitis.

William Johnston Æt 35. Ent. Jan 17th. death Jan 19th.

The body that of an averaged well sized man – In front of right ear black bits dried blood in external meatus. no swelling over either mastoid. over right Mastoid – On removal of Brain. Nothing special in soft parts. Skull cap of average thickness not adherent to the Dura Mater.

On right side the Dura Mater was sawn through in a small area and Pus oozes ~~oozes~~ out at the spot – In right Lateral Sinus there is a recent Clot decolorized at upper – no pus in the Lateral Sinus –

On removing the Dura Mater the following condition is presented –

Convolutions of the right side covered over with a quantity of greenish yellow creamy Pus It is most abundant along the outer ~~[illegible]~~ side, but over the convolutions surrounding the back part of Sylvian Fissure it is uniform.

The Pus covers the posterior half of

this hemisphere with exception
of the lower Occipital Convolution
The course of Longitudinal ~~Longitudinal~~ Fissure is far
in the middle of the frontal lobe
On the left side.
The Base of the Brain presents flakes
of Lymph in the [illegible] and along
the optic nerves - the exudation extends
out along the margins of the Cerebellum
the outer angles of which are particularly affected
.

Heart - Gelatinous Clots in Rt Chambers
those in the Lt Ventricle de"colorized
Gelatinous soft & extend into

the Pulmonary artery for a considerable
distance, Smaller blot in left Ventricle
Bi-cuspid Orifice large Muscle
substance healthy - Tricuspid Orif
over 6 inches in circumference
Lungs Crepitant throughout - Oedematous
& congested posteriorly - Small spot
Pneumonic consolidation in the middle
of Rt Lower Lobe
<u>Kidneys</u> coarse looking Blood vessels full
Small Ecchymoses on mucous memb
of Pelvis
<u>Spleen</u> nearly 200 grammes pulp soft
in places looks Hemmoragic
Nothing Special in Stomach
Liver healthy

366

21/1/79

Morb. Cordis

Body that of an undersized man, of fair development. Face cyanotic & a little swollen. No anasarca, left hand a slightly adematous. Up. & post. pts of body present large areas of hypostasis. Veins of legs & abd. prominent. On inner & ant. aspect of left thigh, numerous small distended veins.

In peritn. incision in body & head, much blood and serum escaped. In abd. a moderate amt. of serum. with faintest. fæcal smell.

On opening Chest an enormous heart is seen occupying the greater portion of lower and anterior part of cavity

In situ it Measures 20 Cm. from apex to base of auricle No fluid in pericardium — Visceral layer are a few fibrinous spots Rt Auricle Enormously distended & fluid blood - and a dark soft clot - On section 20 oz escaped from this chamber —

Lft Auricle not much distended full of dark clots & blood

Rt Ventricle dilated - from pulm. ring to apex 15 Cm. Walls range from 8 to 12 Mm. in thickness —

Tricuspid Orifice slightly over 15 Cm. Valves Normal Pulmonary Valves also Normal - Nothing special in Rt Auricle walls not specially hypertrophied —

Left Auricle not much distended. Nothing special

On opening left Ventricle this chamber is greatly distended & a large loose flabby clot which lies in the chamber, it is dark & Nowhere decolorised & only adherent at Mitral Valve Chordæ Measure from Aortic Ring to apex 13½ Cm.

Circumference 18 1/2 CM   Walls much hypertrophied - measure from 18 --

posterior wall of vent.

in circumf

– Anterior segment

& upon it is a spot.

m & below aortic

d

1/2 CM in circumf

& they are all

t is much cramped

only 17 MM across

along the thickened

oss its face is

rowned beyond the

t 850 grms

lins – Not much blood

s on right side

rd and a little

—

norary organ present

istinct Weight – 150 grs

smooth

Not much blood

Montreal General Hospital.

MEMORANDA FOR THE PATHOLOGIST.

Case Heart Disease

Name George Dougherty   Age 26

Date of entry Jany 18th   Date of death Jany 21st 80
8.30 a.m.

Brief History

Aortic valve disease for several years

Chief Symptoms
For one week before admission great cardiac distress. On admission great oppression of circulation surface blue & cold radial pulse very feeble great dyspnoea – Symptoms continued accompd by vomiting & acute pain. Relieved twice by bleeding

Temperature range

(Signed) James Bell

---

organs remarkably firm —

366

Morb. Cordis

21/1/79

. Body that of an e
face. cyanotic. a
highly edematous
hypostasis. Veins
Left thigh, numer
In pectus. incisum n
In abd. a mod am
On opening Chest
greater portion of lo
In Situ it Meas
No fluid in perica
Rt Auricle Enorm
clot - On section
Left Auricle not mu
Rt Ventricle di
Walls range fr
Tricuspid Orif
Pulmonary Valves
walls not hyp
Left Auricle n
On opening Left
large loose fla
Nowhere decalc
Chordae tend

Circumference 18½ Cm Walls much hypertrophied - measure from 18 -
to 20 MM in thickness - thickest - over posterior wall of Vent.
in neighborhood Mitral Orifice 15 Cm in circum
Mitral Valves thin & healthy looking - Anterior segment
large Papillary Muscles - post flattened - & upon it is a spot
of fibrinous degeneration ½ x 1 Cm
In the posterior Wall just behind the Septum & below aortic
ring is a depression in the substance
Aortic Orifice when open measures 8½ Cm in circumf
Valves are incomps. Edges thickened & they are all
foreshortened The left anterior segment is much crumpled
thickened at attachment & measures only 17 MM across
its face & presents one fenestration and along the thickened
edge are a few pin vegetations
Posterior segment - nearly 2 Cm across its face is
much thickened & opaque
Right-Anterior in same condition
Aorta not dilated some patches of atheroma beyond the
left subclavian Weight of heart - 850 Grms

Lungs
Crepitant throughout No infarctions - not much blood
particularly anemic in upper & middle lobes on right side
lower lobes contain a little more blood and a little
frothy serum may be squeezed out -

Spleen Average a small supernumerary very pale present
size pin - Malpighian bodies distinct Weight - 150 Grms
Kidneys perhaps a little small - surface smooth Not much blood
Organs remarkably pale -

Right Kidney 150 grms - Left 130 grms

Liver Small - Weight
Jaun - but not Cirrhotic Small central veins a little fat

Stomach
Mucosa Coated & a thick tenacious mucus
Capillaries Small veins injected
Aorta healthy —

367

22/1/80

Phthisis

Body emaciated. Face particularly so. In Abdomen pyloric end of Stomach ten C.M. below Xyphoid cartilage, Transverse colon passes low below level of navel

Thorax. Right Lung extends over beyond median line, adhesions on this side at the upper & lateral parts,

On left side universal adhesions.

Heart. In Right Auricle a tolerably firm clot Quite colorless in its upper part. It is very firm closely interlaced with the muscular columns & extends into the Cavae, from which it can be withdrawn as a distinct mould. That from the superior Cava is firm, colorless in its upper part, dark colored below. In Right Ventricle is a perfectly colorless clot, adherent to the valves, gelatinous looking at its upper part. In Pulmonary branches it is colorless almost to the bifurcation & in some of the branches there is a thin fibrinous layer at the upper part. The clot in Right Ventricle is also interlaced with the fleshy columns at the apex

In Left Auricle, dark clots. In Left. Ventricle a small firm coagulum, leathery & extending into Aorta.

In opening Heart, Valves normal. Tricuspid

orifice 5½ inches in circumference. Right chamber a little large, walls not hypertrophied

Right Lung

Close pleuritic adhesions. On section a large irregular cavity at apex, much broken up by trabeculæ. Lining membrane gray, the lower part of upper lobe contains numerous small tubercles chiefly about the bronchi

In the upper part of lower lobe is a small patch of red Hepatisation. Anterior border of lung Emphysematous

Left Lung

Universally adherent. Entire upper & posterior part of upper lobe is occupied by a large cavity. The anterior part of the lung is airless, occupied by Caseous masses & Small tubercles.

Many of Bronchial tubes are filled up with Cheesy matter. The lower lobe contains numerous groups of tubercles

Spleen

Not enlarged, on section. Malpighian bodies large & in state of amyloid degeneration. Weight of Spleen 165 Grains

Kidneys Large. Capsule detaches with difficulty & is thin. On Section cortex swollen & anæmic. The pyramids contain blood & in consequence the contrast between

the two portions is well marked.
On examining the cortical substance closely
The irregular translucent areas are seen interspersed with others of an opague yellow color
Both kidneys much alike
Weight of both kidneys one 230 other 255
Liver
Not enlarged, does not appear amyloid

Intestines
Nothing special in jejunum In ileum M. membrane is food deal injected. Peyers patches are swollen. the individual elements distinct & there are several small ulcers.
Caecum inflamed, in places dark colored & there are numerous irregular losses of substance There are numerous small irregular ulcers in the ascending & transverse colon. At pylorus just outside ring there is a peculiar condition as follows.
There appears to be a loss of substance about fifteen x fifteen M. M. Base smooth, the edges of M. Membrane overlapping very much This sore was cut through in slitting up the orifice. A small dark spot with a little dispersion is seen just outside the ring not far from the loss of substance, On cutting into this there is a definite cavity

beneath the M. Membrane is a small cavity containing some turbid fluid

368 Phthisis. Aneurism in Pulmonary Artery.

January 26th 1880

Body that of a delicately built, moderately emaciated man. Abdomen: liver a little depressed: pylorus and Stomach is 8 c.m. below ensiform Cart. & about 3 c.m. to the right of middle line. Thorax: Rt Lung firmly adherent Left only at apex:

Heart: Valves healthy: one segment of aortic semilunar fenestrated: Muscle substance pale, mottled, & about normal thickness: Weight 215 grammes: Ri cupid orifice measures 5 1/4 inches: Mitral 4 1/4 inches

Lungs: Lt & Rt universally adherent: fibrous bands between two layers of pleura are infiltrated with serum: (Rt ventricle dilated at & forms the apex of heart: chambers 13 c.m in length) especially at lower part & surface Diaphragmatic Lower & posterior border of Rt lung, only is crepitant, the rest of its extent solid & airless; in

involving the entire upper lobe & greater portion of the middle there is a large smooth walled cavity, lined by a distinct rough greyish membrane which can readily be peeled off, very few trabeculae cross the walls and those present are confined to the inner surface, the walls of the cavity are thick in this cavity are a number of dark clots mixed with purulent matter, in the lateral part of lower lobe there is another cavity the size of a small orange and in the posterior part are 5 or 6 cavities, ranging in size from a pea to a walnut they all contain blood & clots, the tissues surrounding these cavities is airless, firm, grey coloured, and somewhat gelatinous looking

Left Lung A smooth walled cavity at apex situated more posteriorly, numerous other small cavities in this lobe most of them containing clots, lower lobe

crepitant, presents numerous nodular masses, bronchi contain blood clots, upper & back part of this lobe several cavities, bronchial glands large soft not caseous,
Spleen wt 300 grms, pulp soft organ not amyloid,
Kidneys contain much blood, vessels very full tissue very firm,
Liver. wt 1800 grms also contains a good deal of blood tissue soft,
Intestines No involvement of Peyer's gland, in the caecum some of the solitary glands are swollen, contents cheesy, and there are two or three small losses of substance
Stomach contains numerous clots & dark bloody mucus. Mucous Membrane is stained in places,

Jany 27th 1880

Body that of a moderately small, emaciated woman. In Abdomen intestines distended with gas, Liver projects somewhat more than a hands breadth below the xiphoid cartilage - The right lobe is prolonged into the iliac fossa where it lies in contact with the caecum. The margin of it is 14 cm from the costal border in mammary line. Pylorus is 11 cm from tip of xiphoid cartilage, and 2 cm to the right of the median line. In thorax adhesions on right side except at antero - lateral portion below - On left side, adhesions appear to be universal. In right auricle firm clot colorless, at upper layer - In right Ventricle a firm cadaveric clot almost entirely decolorised closely interlaced with the trab., and extending into the Pulmonary artery. In left auricle dark clot. In Left Ventricle a firm coagulum. In Right Ventricle valves healthy, orifice admits 5½ in. in circumference, valves a little thickened at edges. Finest in all the segments of Pulmonary Semilunar. At apex of Ventricle are numerous small globular concretions, whitish in color, firmly adherent in the meshes. They are not large, one of them has softened in the centre. In Left Ventricle Chamber much smaller than right

Mitral valve normal. Aortic Semilunar fenestrated, one fenestration in right posterior segment is 9 mm by length by 5 mm in breadth. Muscle substance is pale looking, right chamber measures 10 cm from pulmonary ring to apex. Weight of heart is 270 grammes. Right Lung - crepitant throughout, at anterior border, and inner surface very emphy. Good deal of serum in the organ, no nodular masses, weight of Lung 550 gram. Bronchial glands large, soft, swollen, not caseous. Left Lung - solid throughout, weighs 1430 grammes at the apex. There is a cavity size of a small orange, walls thin, pleura covering it much thickened. Lining memb. smooth, greyish. Not crossed by trab. communicates at lower part with the bronchus. Over the rest of the Lung there is a tolerably firm false memb. which can be readily stripped off. On longitudinal section the entire lower lobe is in a condition of hepatization. At the upper part, and anteriorly it is becoming greyish, in the rest of its extent it is reddish, and presents the usual appearances of a Pneumonia in the second stage. The upper lobe is not inflamed, but the tissue about the cavity is infiltrated with serum, and ~~numerous~~ fibrous bands pass in at the anterior margin. There are also numerous nodular

bodies, firm.

Kidneys - A little fibroid, rough on the surface capsule detachs with difficulty, and there are numerous small cysts throughout the organ particularly the left.

Spleen - weight 100 grammes - natural looking

Liver - deformed - right lobe measures 24 cm in antero-posterior diameter, and 16 cm in transverse. A shallow groove passes across the anterior surface about the middle. Three smooth fissures run along the upper surface of the organ, substance looks fatty -

Stomach - mucous membrane is thin, intestines natural. Aorta a little atheromatous

Uterus small. the right half of the fundus looks larger than the left. The cavity is somewhat dilated, contains a brownish yellow secretion. The neck is constricted, and there are traces of past inflammation about the external os in the shape of fibrous bands.

370 Phthisis. Tuber. Peritonitis

Daily Body that of an average aged much emaciated Man
On opening abdomen, about ℥ XXXV of purulent fluid
The lower part the two Layers of Peritoneum are closely united together, the Omentum greatly thickened & covers over the transverse Colon & the Coils of the small intestines, being very closely united with them below.
The Coils of bowel are very closely glued together and covered over with a dirty greyish yellow Exudation — It is almost impossible to Separate them without tearing
The serous Surface of the Liver is adherent to the subjacent tissues. The upper Surface of left Lobe is united with the diaphragm by fine fibrinous

Heart. Rt Auricle filled & a yellowish clot infiltrated with Straw Colored Serum It is dark colored only at dependent portions. — Lft Auricle Contains a dark clot — Lft Ventricle a small partially decolorized one which extends into the pulmonary artery — The Chamber is not much dilated walls a little thicker than

normal. Valves normal — Tricuspid orifice
Large, admitting passage of Heart Cone
Left Ventricle normal. one segment of
Aortic Semilunar fenestrated.

Lungs. Rt. Closely adherent to Chest
wall at upper & back part.
Pleura of posterior part thickened, infiltrated
with serum and covered over with recent
lymph — On section from apex to base
Upper lobe post. part. presents numerous
small cavities, softening caseous masses
and others of firmer character
The tissue between these is in part
natural, and in part infiltrated with
small greyish yellow spots many of
which have a foliacious appearance
Very many of these shew a distinct central
spot representing ~~the~~ small bronchiole
In anterior portion of upper lobe are
~~two~~ larger cavities the size of small walnuts
and the tissue in this region contains
many more tuberculous nodules which
are fused together into irregular caseous
masses
Left Lung only slightly Crepitant
The gr. portion of the tissue being occupied

by cavities and softening cheesy masses
The apex and postero-lateral portion present a
series of communicating cavities of large size
filled with a very tenacious blood stained
mucus — In the anterior portions there
is crepitant lung tissue through which
numerous nodules are scattered.

Kidneys Rt. about normal size
and of natural appearance
Left. nearly normal same appearance. but pale
one small nodular mass.

Spleen Of Average size
Malpighian bodies distinct
Liver Small uniform in Color
Tissue uniform — no tubercles
Weigh 1220 Grammes

Stomach
Mucous Membrane pale but
otherwise natural looking

On section of the intestines does not appear that there is any ulceration on mucus surface. Portions of intestine and the ileum are greatly matted together

371

Phthisis 7/2/80

Body that of an averaged sized man, no special emaciation.

In abdomen: Stomach somewhat dilated, pylorus orifice lies about 3 inches below the Ziphoid cartilage & fully 2½ inches to right of median line, lying close under the liver in vicinity of longitudinal fissures. Cæcum & first part of asc. colon are unattached & lie transversely at the upper border of the pelvis. Fæcal masses exist in asc. colon & sigmoid flexure, only 2 or 3 in transverse.

In Thorax No adhesions on right side: On left side effusion turbid serum mixed with flakes, about 2 to 3, lung is adherent in upper & back part. See on lower circumference

Heart: Rt chambers full of clots, not adherent, partially decolorized

Valves normal. Left side. valves healthy, wall of left ventricle a little thick. Mitral orifice large, admitting heart one. Mitral orifice 4 3/4 in in circumference. Heart weighs 320 grammes.
Rt lung: crepitant throughout, lower part & ant. lobe several nodules are felt, which on section are seen to be fibro-caseous in character & surrounded by connective tissue, at post. part of this lobe is a larger caseous mass imbedded in firm fibrous tissue. ~~The upper~~ this lobe is very edem. at posterior part ant. part dry; lower lobe not edem.
Left Lung: very slightly crepitant at upper part of lower lobe, rest of lung airless: pleura covering lower 3/4 of lower lobe & lower & ant 1/3 of upper lobe, thickened & covered with partially organized lymph. diaphr. surface is also covered with lymph which is firm & partially organized
Upper lobe, in antero-lateral part is occupied by a series of cavities, with irregular walls and partly filled with fluid pus
Ant portion of this lobe occupied by smaller cavities & caseous masses surrounded by a deposit infiltrated lung tissue
In lower lobe about center of post. surface is a small depressed spot about size of little finger nail, over which the membrane

is exceedingly thin, but does not appear to be
perforated. In section thus is seen to cover a small
cavity with cheesy caseous walls: whole of this lobe
contains numerous caseous masses + small cavities +
the tissue about them is purplish + solidified
The bronchial glands are little enlarged pigmented
Kidneys: long narrow, lobulated, substance
has healthy appearance
Spleen enlarged, flabby, pale, soft.
Liver: not enlarged, little soft.

February 8th 1880.

Phthisis

Body that of a small much emaciated woman

Liver extends considerable distance below the ribs.

Leathery clot and blood in Rt Auricle

Same in Rt Ventricle closely ~~entwined~~ interlaced in Chordae Tendineae

Valves on Rt side normal. Small fenestration in Pulmonary.

Left Ventricle decolourised adherent clot.

Chambers of normal size. Valves normal

Aorta Healthy.

Lungs.

Left Lung. Is solid in upper lobe. Crepitant in lower lobe and contains numerous nodules.

On section, numerous small cavities and softening caseous masses. Intervening lung tissue between these is greyish in colour and in many spots air cells are seen filled up with small yellowish white mass.

Considerable increase in the connective tissue (interlobular)

In the lower lobe, there are numerous groups of greyish yellow, nodular bodies, Lung tissue about these is crepitant. Bronchial Glands much enlarged, and moderately pigmented

Left Lung

Very large cavity occupies entire

apex and extends down to middle lobe
Walls are rough crossed by many trabeculae. In ant.
part smaller cavities and hepatized spots, surround-
ed by greyish lung tissue. Lower lobe shows cav-
ities at the upper part. Lower portion, is not
crepitant but presents numerous small tubercles
scattered through the substance. Most of them are
in groups many around the small bronchi

Bronchial gland here are large firm, the gland
is firm and cretaceous

Spleen

Is firm, uniform, brownish grey in colour.

Kidney

Presents nothing abnormal

Stomach

Muc. mammillated except at pylorus, here other-
wise normal. Liver flattened from before
backwards

Liver substance is firm, otherwise natural
looking

Intestines

Heart weighs 260 grms

11/2/80.

Fractured Ribs Laceration & Gangrene of Lung

373

Body average size signs of injury ecchymoses & abrasions on front of legs one or two small ones on head. and another above sternum on right side In abdomen nothing special On opening Thorax. R Pleura full of bloody fluid about 50 ounces. Lung is collapsed. & covered with fibrinous membrane adherent at apex behind and at one spot laterally. Left 5th 6th 7th Ribs are fractured The former in 2 places the innermost about an inch from it's head the inner most is comminuted & the bit projects through the pleura The 7th is fractured about 2½ inches from sternal end has lacerated the pleura & projects for some distance into the sack Heart: nothing special. Walls & Cavities somewhat thinner than normal & very dark brownish red color R. Lung. universally Collapsed & airless. Pleura covered with flakes of lymph. at the mid portion of lower lobe third (3) lacerations of lung substance largest about an inch long ½ inch in width the tissue soft deeply blood stained Beneath it and extending laterally & towards anterior border there is a considerable area in which

lung tissue is soft & shreddy and in condition of commencing Gangrene. On section of other portions of lung are found dark colored L. Lung. Heavy. very slightly crepitant & contains large quantity of Blood & Oedema at lower & lateral part of upper lobe there are small areas.

Spleen. small weight 60 Grams. accessory supernumerary organ present

Kidneys smaller than natural. substance healthy.

Liver looks of normal size substance normal

Stomach. nothing special.

Intestines " "

Brain. Calvaria thick. over anterior part of frontal lobes & lateral part of left Hemisphere the Arachnoid is opaque somewhat thickened & considerable excess of Cerebro-spinal fluid nothing special about vessels at base is no Atheroma. Organ carefully sliced nothing special found in substance Vessels moderately full

Mitral valve disease. Embolic cerebral softening

374

Body small tolerably well nourished woman. numerous ecchymoses on face, rt. leg & l. arm. In Abd. nothing special on superficial exam. Pylorus lies 3 in. below & a little to left of xiphoid cartilage.

In Thorax lungs not adherent.

Heart large. veins & rt. aur. large distended c̄ clots which are not decolorized. Wall somewhat thicker than natural. Tricuspid orifice measures 4¼ in. in circumference. The auricular surface of the valve close to the edge presents a circle of recent vegetations bead-like in character minutely cauliflower in appearance. several of them rounded & pedunculated. ~~Tricus~~ Rt. vent. measures 4¾ in. in length. Walls hypertrophied, firm, ant. nearly ⅜ in. in thickness. post. wall a little more. L. Auricle full of clots dark col. and c̄ fluid ōō with these was a round clot about size of blue plum, mottled in color, chiefly reddish; soft elastic feel, ext'l portion of it. The endocardium very opaque walls thickened & tough. chamber considerably dilated. wall not very thick. Mitral orifice greatly narrowed.

scarcely 1/8 in diameter. From auricle there is a circular depression corresponding to the valves at bottom of which the button hole orifice exists. From the vent. the orifice has thickened irregular edges & almost cartilaginous consistency. The chordae tendineae are much shortened particularly those from ant. mural which in reality is itself directly attached to thickened valve. The Chordae & post. mural are short. Surrounding lips of orifice & auricular surface are numerous recent vegetations.

The L. Vent. is small measures 1½ in from ring to apex. Muscular walls about ½ in in thickness. Aortic semilunar valves & pages somewhat thickened particularly about corpora Arant. and along vent. surface is a row of minute cauliflower. Chiefly below free edge & valves most numerous on ant. & sl. post. segments.

The aorta measures 2½ in across ascending portion. R. artery 3¼ in circumference.

Lungs crepitant throughout but it is tough & leathery. On section the capillaries are not very full in places but small veins & arteries are greatly distended. The bronchi tinged brown indicating not especially well clean. The Bronchi are filled with a tenacious fluid & membrane injected. The lungs are much carbonized.

Splen ~~Spleen~~ wghs 3150. exactly by firm no infarcts.
Kidneys. Rt very small surface much puck. ered presents signs of old infarctions.
L. kidney larger.
Liver firm a little roughened surface. on section somewhat cirrhotic. Central veins prominent. interlobular vessels also distinct.
Stomach. vessels full nothing special about mucosa. Intestines look normal.
~~Brain~~

Brain. Calv. thick. Pacchionian granulations on removal Dura mater natural. nothing special in Lungs. Lungs on removal of R. Arachnoid opaque & thickened particularly at the side & Long. fissure. A good deal of fluid beneath arachnoid over entire Base of brain. Natural looking. Arachnoid slightly opaque. Main vessels & Circle of Willis empty. No special matting. Vessels not atheromatous. Convolutions of the base & those of central Lobe look natural. Convolutions of surface look natural. On slicing the organ following appearances noted. Ventricular section normal. Pedicles & frontal normal.

Frontal section. on left side there is a spot of yellowish softening & following extent. The extreme upper part of upper capsule is known in extent the central fibres of it between lenticular nucleus & corpus striatum are firm. The extreme ant. end of optic Thal. which is exposed in this section is on left side softened & distinctly yellowish in color. The lentiform nucleus in central part looks pretty natural, but in outer portion it is softened. The Claustrum is also softened on this side. The structures on the other side are normal.

Parietal section. On this section the spot of softening involves the Lent. nucleus the upper part of internal capsule ant. lent. nucleus and caudate. The Thal. Optic. looks small on on left side than on right. The chief part of softening is in portion of brain between the frontal & parietal portion. In the ant. portion of this section it is situated chiefly in Thal. Optic. In post. part chiefly in Lentic nucleus.

Occipital Parietal Section looks normal. On ant. surface softening still to be seen involving Lent. nucleus tail of Caudate nucleus and upper & outer part of capsule between them.

Nothing special noted in Pons. Lesions of descending columns in Medulla.

375 · Pneumonia 28/2/80

Papyrographic report. p. 117

376 Womary. Inspectation 29/2/80.

Body. that of an old well nourished man
an abdomen position of viscera normal
Apex beat lies about an inch below & inch & half to
right of ensiform cartilage
heart
Firm clots in right chambers. Valves normal
Left chambers also has clots. Left ventricle appears
little thick
Lungs.
Congestant throughout. Moderate amount of
blood & serum in dependent part. On apex of
left lung there is a patch of thick fibrous in-
filtration almost cartilaginous in con-
sistency Splen. small pulp light
brown colour Kidneys. undivided
Cortices somewhat pale malpigian bodies
distinct. Splen weighs 120 grammes.
Left kidney presents on the surface numer-
ous small opaque white spots. Some isolated
others adhere together. Most of them on
on section are seen to be confined to the out
most portion of the organ Several of them on
section can be seen in connection with whit-
ish lines running towards the pyramids

Bladder & Urethra

Bladder firmly contracted fails firm & dense walls greatly thickened measuring in places fully half inch (½ inch) in thickness

Mucous membrane presents numerous ridges which are deeply congested the intervening portions lighter in colour. On the right side near the orifice of the Ureter ~~&~~ situated close to its wall there is a small abscess in the wall the size of a marble. The prostrate looks normal and is not enlarged. The tissues in front and about the Urethra from the membranous portion are in a condition of suppuration & ~~&~~ sloughing

Walls of Scrotum - in fact the entire bag ~~&c~~ is infiltrated with pus and superficially is in a condition of gangrene

About 2½ inches from the meatus. The catheter passes through a large orifice in the wall over ½ inch in length and involving at least ⅓ of the circumference of the tube

From this point to near the prostrate the urethra presents a series of false passages

Nothing special in the stomach
Intestines look normal

Mitral Stenosis

377

Case -

March 15, 1880

The body that of a well nourished woman. & nothing special in abd. Ryt. at middle line about 4 inch. below Xyph. Cart. Ri. Pleura about 70 oz slightly blood tinged serum. Lung on this side collapsed lower 3/4 covered with thick fibrinous exudation places haemorragic no adhesion in left lung

Heart all chambers contain. dark clots no white decolorized. & which extend into the vessels The R. chambers cont. the largest. R auricle is large Liab. prominence ant. surf. presents a row beads veg. Orifice is not much dilated 4¼ inch in circumf. R. vent. is dilated & Hypt. The wall considerably thickened & very firm. L. aur. much dilated. endocard. very opaque. The seg. of mitral valves have fused & form a narrow button hole orif into which tip of little finger fits. The edges are thickened & presents a few small dilatation L. vent. small. walls not Hypt. & very much softer than those right side. Aortic valves are opaque edges thickened & on the vent. side are several beads of veg. specially abundant ~~& on~~ on the post valve The aorta is healthy.

Lungs. L. lung. crepitant throughout. but firm & cuts with grit resistant. when first exposed section is of brownish red color & soon changes with action of the air to a vivid red. bronch. tint throughout

the org. one spot of infarction on lower lobe
R. lung is collapsed except at the apex. The rest of the org. is excedingly firm, on section it collapses firm & dry. Lower lobe the same condition at the extreme margin there is a small infarct. over this site. The middle & greater part of lower lobe is covered, lipid. The branches of pulmonary art. are thrombic
the spleen is small & firm weighs 145
Kidneys no infarct are of size, present a distinct injection
R. organs also firm, no infarction

Case 378 Ulcerative Endocarditis

Man). Walker. March 15, 1880

Body that of a poorly nourished man
nothing special on ext examination
On abd. stomach distended Pyl. about 3 inch below

Brain Org full size & firmness. at the base
vessels are moderately fatty at. cort blood on the
basilar art. sit. on the fronts. is a small aneurism
about the size pea, involving the cortex circumf. On
the cortex there is considerable meningeal in-
flammation. This is confined almost to the left
side & is extensive over the post part of first frontal
convolution over its post front. over the ascending
frontal. convolution about the sylvan fissure &
extend. over the superior parietal lobule. The ex-
sudation is thick entirely beneath the arachnoid
& is purulent in character. The convolutions
of the other side are not involved the vessels

Heart Decolorized clots in R. chamber. The
musc. dull dark brown color. The R. valves are
normal. The L. vent. is slightly dilat. Musc. pale
pale color. mitral valve passes an unusual
several small heads of veg. Aortic sig greatly
obstructed with large endocard veg. which
adhere to the former veg. The effect of Endocard.
veg is very marked. A large veg. adhering to
the vent. surf. In part this is greyish yellow in
color, but in greater part it is covered with

adhesions thruout. From the vent. surf. it is seen that outer half of the valve is destroyed & a perfor passes through the seg. The large mass of veg.
Lungs. Emphysematic ant. border. The post. & ant. lung heavy. The lung firm, at the base cont. much blood & serum. post. ~~sec~~ expired
right
Spleen. large soft no infarctions
Kidneys are size cortices pale. no specials
infarcts except one small grey infarct.
Nothing special in stomach. & intestine.

Case 379

Man   Gangrene of Toes   May 17th 1880.

Body of old fairly nourished man
Nothing special in abdomen. –
In thorax – A few bridles on left side
Lungs emphysematous. In heart Blood
clotted dark colored. Intima of R auricle
deeply stained. Pulmonary semilunar v
cribriform R. Vent a little thick
valves of L side normal. Aortic semil fenest-
muscle sub- dark colored. –
Coron Artery very atheromatous. Wt of Heart
325 Grms Lungs emphysematous in front
at Poster parts. very Oedematous. But Crepitant
Scattered over Pleurae are few opaq white spots
not elevated.
Spleen not enlarged. very soft Pulp diffluent
weighs. 125 Grms Kidneys small no special
staining. Organs appear normal
Liver some adhesions. About normal size
L. femoral vein dark grumous clots. blood stained
Big toe has been Amputated Stump Gangren
extended to other toes & ant part of foot
Nothing special found in veins on dissection
Slight Ulcer on the free border of true
vocal Cords

380

Case - Phthisis -

Body that of small moderately emaciated man
In Abdomen Liver projects below Costal border
in ster part of its extent In Thorax
tissue of Ant mediast infilt with
gelat serum In R Pleura 20 z Turbid
plastic & thin Lung is adherent at apex Behind
At Left side no adhesions
In R. auric fl Blood . In other Chambers
small dark Colored Clots. Tint in L ventricle
more decolorized .
Nothing special in R vent Valves normal
" " in L " On segment of
Aort-Semilunar penetrated Left- Lung
Aspirant- firm nod felt through it- On
Section thro seen to be made up of small
tubercles arranged in groups- Chiefly
about the small Bronchi In place
these have run together formed firm
masses becoming Caseous
R Lung firm solid covered with plastic
exudations On Section at- apex 4 Cavities
filled thick muco pus & Caseous matter the

lining membr thick irregular The layer
of thick Cortex size of large walnut & with
appearance one a Main Bronchus commun
directly. Rest of Lung airless & presents numer
ous softening cheesy masses In the interspaces
of which the tissue is gray colored firm
infiltr with serum & in this tissue are
numerous isolated grayish white bodies
most of which present small central dots.
Bronchial glands are larg one presents
a firm Caseo-Calcareous nodule
Spleen small. tolerably firm nothing special
in Kidneys Intestines in Ileum are
numerous Tuberculous Ulcers involving
chiefly the Solitary glands. Thes extend
into large intestine chiefly in Caecum
Liver small Mesent. glands Cheesy-

381

Cirrhosis of Liver.

April 19th 1880. Body that of a large sized woman, ~~Rigor Mortis present~~. not emaciated. Rigor Mortis present. On opening Abdomen a small amount of clear serous fluid is found. Spleen found projecting from left side almost to median line. Liver reaches only 2 in. below costal cartilages in median line; entirely retracted behind ribs. On op. Thorax & Pericardium found full of bld. stained serum. RV. Aur. contains dark grumous clot, & much fld. blood. RV. V. contains clot & fld. blood - & dark clot in vessels: left Aur. contains dark grumous clot: Left V. contains little blood: (much fld. bld. escapes from heart): Heart wgs 310 Grms. Valves normal:

Rt. lung partially adher. in upper lobe, and closely adher. to Diaph.

Left lung contracted & collapsed to upper & post. part of left cavity; pleura closely adherent throughout; On removal found small cicatricial apex occup. by a large cavity. lower lobe full of hard nodular masses (size large pinhead) wgs 650 Rt. lung wgs 970 grms. contains air, & sp. at apex, on section thick, bloody purulent thin fld. exudate

section above shows many small nod. masses. And part of low. lobe contains sm. cav's. more nodular than apex.
Kidney L. 250 - Rt 250 - large
Capsules can be detached. Inner below hyp's & Cort not very marked; while the tubules are ~~sep.~~ very distinct. as marked white lines.
Spleen. 930 gram ~~tonight~~ very large. hard & semi-cartilaginous to the knife. Cuts dry gran. red. pulp consist
Liver 1800 grams

Gall bladder empty.
Stomach nothing abnormal found.
Intest. mucous ment. congest. in open lym. areas
Brain. Nothing abnormal.-

176 19/5/80 (Haslam + Courtney boot race)

Case 382 @ æt. ca. 50 Suppurative Synovitis of left Knee.-
Patient attacked with simple synovitis - went into suppuration
disorganization of the joint. Opened, cellulitis in neighbourhood
+ burrowing in popliteal space. Death from haemorrhage.

Body not considerably emaciated (Has been a stout woman) Several sinuses about Left Knee
skin discolored. Pus oozes Nothing special
in neighbourhood of abdomen. L Thorax, Lungs
Collapse R Heart- contain small amt
of Blood.. L Vent- empty; Nothing special
in R. Heart.; Nothing special in L. Ventricle
Lungs Collapsed, crepitant, pale, Moderate
amt of serum, not much blood
Spleen average size, pulp dark brown color. not
extremely soft.
Kidneys. - soft cortices moderately pale,
Stomach - P. M. solution in fundus of Stomach

Liver. small adhesions on upper surface with diaphragm, substance
soft. Upper surf of left lobe small clear cyst
Uterus. contains a small amt of bloody
serum not much dilated. Ext os very narrow
Canal of Cervix wide Int os extremely constricted
admitting only a fine bristle

Brain. — moist
Femoral vein opened by incision at several parts small thrombi projecting from behind the valves
The source of the haemorrhage was not discovered; no ulceration in femoral or in the popliteal branches —
Knee joint extensively disorganized, cartilages have disappeared.

Vide Am. J. Med Sciences Oct. 1882

Case 383 Echinococci — Aug 2nd 3rd '80

Patient of Dr Angus McDonnell in Hotel Dieu. was asked to see him as consultant was suspected. Found a man with an enlarged splen & liver, dropsy of belly, great emaciation & irregular fever. No increase in white blood corpuscles. The splen was smaller, border not distinct and did not project much beyond the costal border. Liver was large, anterior border nodular, and on peritoneum was a large nodular mass below umbilicus. Diagn cancer - liver & peritoneum. death took place about 3 weeks after this. Patient was an Italian - had been in the city about 2½ (3) yrs in Hotel Dieu prior early in January.

Autopsy. Body much emaciated. In abdomen - liver projects more than a hands breadth below costal border. Is closely walled to stomach and omentum. Splen enlarged. Attached to inferior of liver is a large pear shaped - opaque white hydatid cyst, situated in mid-abd. region, & the large end about the size of the closed fist. Tapers to a narrow stalk. On the parietal peritoneum just below right border of liver is an irregular flattened cyst, presenting three or four branches or subdivisions. Lower down in the right iliac region is another, the size of an orange. The bladder is pushed up nearly as high as the navel and is flattened when lifted up it is seen that the entire pelvis is occupied by very large ~~clear~~ cyst, with a firm opaque wall, which is in close contact all round with the pelvis, compressing the rectum & allowing with difficulty the fingers to be inserted. Several smaller cysts are seen attached to the omentum & peritoneum. On dissection of the various organs the

following condition is presented :-

Liver greatly enlarged, shape retained, under surface and anterior edge of left lobe closely adherent to stomach & colon & omentum, which is thickened. On ant. edge are several nodular masses - small hydatid cysts. Organ was removed with stomach & duodenum attached. On section no cysts in right lobe. At back part of left lobe there is a large cyst the size of a cricket ball, which has suppurated and contains a quantity of greyish yellow semi purulent matter mixed with the remnants of cyst wall. Anterior to this in the ant. part of the lobe is a second cyst, somewhat larger than the first, with which it is in communication & is about the size of a penny. This sac projects from the under side of the lobe & near the ant. notch. It is closely adherent to stomach & duodenum. When slit open, much purulent matter with Echinococci shreds. On opening stomach and duodenum it is seen that the cyst has perforated into them. viscus in two places, one an orifice size of a penny at the ant. surface near the fundus, the other smaller ant two inches from it in lesser curv. In duodenum there is a third communication the size of a six pence. The margins of these orifices are very firm, smooth, . On the stomach itself at the fundus there is an irregular cyst, visible from outside, when it is attached near spleen. It perforates the wall and appears in the organ as a flattened mass the lining membrane of the sac covers both & thin layers of mucus. . . Spleen greatly enlarged, remains

Though somewhat rounded. At hilus are 3 cysts the
size of small apples attached to capsule. The increased size
of the organ is due to its distension with a large hydatid sac
the lung wall of which is very evident near the hilus and
has almost reached to the capsule on the convex side, a
thin layer of splenic tissue separating them. Above
and then is a thicker layer of tissue and the organ looks
quite natural. The large one in pelvis found un removed
& did not appear to have any special attachment, above
& the peritoneal tissue over the rectum.
Kidneys are pale, texture normal. Intestines present nothing
special. Organs of the thorax small. but no special pathological
changes. no hydatids.
The cysts themselves presented the following appearances:-

Case - 384 Fibroid Phthisis -

Body that of an old much emaciated man - Rig. Mort. present. In Abdomen - Left lobe of Liver projects 2 hand^s breadth below xyph. cart. - Pylorus situated 3 in below & 1½ in to Rt of Xyph. Cart. -

On opening Thorax. the left lung projects beyond the middle line & covers over the heart - Slight adhesions on left side - firm ones on Rt. side. -

On opening pericardium a small amount of fluid escapes. - In Rt. Auricle some blood & a firm gelat. clot decolorized at upper portion. - In Rt. Vent. a firm colorless fib. clot. - In left Aur. a dark grumous clot. In left Vent. a small partially decolorized clot c̄ a small amount of fluid blood -

Rt. Aur. moderately distended - not hypertrophied. - Tricuspid - admits two fingers freely through. -

Rt. Vent. chamb. large - walls not much thickened muscle substance soft. Pulm. Semilun. normal - small fenestrum in one seg. -

Left Vent. not dilated walls of average thickness. - Mitral valve a little stiff at attachments - Aort. Semi lun. firm & calcareous at attached borders - Post seg. decidedly larger than either other. Coronary Arts. a little atheromatous. Heart wt. 330 grms.

Left Lung - large - Emphy. at ant. border. - Numerous nodules felt throughout it. Organ crepit

out throughout - no cavity at apex.
On pleurae subscularly lower lobes are numerous grey granulations & the same seen on section throughout Substance. - At Ant. Border of upper lobe some of them nodular are large & present granular non-caseous appearance - Rt. Lung. Internally fibrous adhesions over entire surface of upper lobe. - Crepitant at base - Entire upper lobe airless, firm - Is occupied by large cavity which extends far into ant. border. - walls of cavity are firm - thick & pleura over it is in places ½ in thick - Numerous trabeculae - the remains of bronchi & vessels cross it on the inner of the middle lobe is firm - fibroid and presents several smaller cavities which are in communication & the large one - The lower lobe is crepitant & presents numerous small nodules some of them caseous in the centre - Others clear translucent & gelatinous in character. - There is no small numerous, nor any spot discovered from which the blood might be supposed to have come - The Bronchial glands on the right side are caseous - two of them firm & calcareous

Spleen large - weighs 8-8-0 grams. - Capsule at upper end has a spot greatly thickened & fibroid - On section organ firm - trabeculae

tissue well marked – Malp. bodies visable here & there & some small translucent bodies tolerably firm & about the size of millary tubercles. –

Kidneys average size – on section firm, capsules detach c̄ difficulty – a few small tubercles on surface. ––

Liver wt. 2150 grams – large, firm. Ant. border of left lobe puckered – fibrous tissue much increased between the lobules being seen as glistening zones surrounding lobules. –

Stomach Nothing abnormal. –

Aorta healthy.

Gall Bladder full –

Brain

Card – 385

May 3rd 1880. Aortic insufficiency –

13 hrs. after death.

Body that of a well built & well nourished man. No dropsy. Face has an ashy gray look – slight p.m. discoloration in dependent parts. Slight wound across bridge of nose

On opening abdomen. – Pylorus 3½ in. below xiphoid cartilage & ½ in. to right of middle line. Left lobe of liver a little depressed

In thorax small amount of fluid in pleura – no adhesions – heart enormously enlarged occupying very large space in anterior & lower part of cavity –

Heart In. Rt. Auc. distended – On section, large clot, decolorized in its upper portion – not adherent – continuous with similar clots in the veins. In Rt. Vent. Colorless clot not adherent prolonged into the pulmonary artery. In addition, a small amount of fluid blood. In Left. Auc. Dark grumous clots In. Left Vent. greatly dilated; a coagulum lies in its cavity, colorless in its upper portion, colored beneath – projects into the aorta, & can be withdrawn as a continuous mold of this vessel and its branches.

In removing the heart about ~~℥ix~~ 18℥ blood ~~were~~ escaped from chambers. — <u>On further dissection</u> <u>Rt. Aur.</u> moderately dilated walls not thickened. <u>Rt. Vent.</u> Dilated measuring from pulmonary ring to apex 6½ in — tricuspid orifice dilated admitting heartcone freely (over 6 in). Tricuspid valves normal. — Pulmonary semilunar valves also normal — one segment fenestrated. <u>Left Aur</u> dilated endocardium opaque, pulmonary veins entering it dilated. <u>Left Vent.</u> enormously dilated — walls hypertrophied. — Ant. wall middle part near septum ¾ in. thick — Post wall a full inch thick. Chamber measures from aortic ring to apex 5 in. — circumference about 8 in. — mitral valves opaque, not much thickened — circumference of orifice 4¾ in. Aortic orifice measures 3 in across, above segments. <u>Semilunar valves</u> present following appearance. Left anterior is thickened at its edge & projects out almost at 90° to wall of artery. It is crumpled shortened across its face measuring just ¾ in. Right Anterior also thickened at its edge, firm & fibroid. Posterior Segment less affected than the others, edge thinner & body not so opaque.

first portion of Jejunum + termination of Duodenum present in spots a peculiar opacity milk-white in color. At third portion of Duodenum this is very marked beneath the peritoneum, on section, a milky chyle-like fluid ~~exudes~~ exudes - it looks like an extra-vasation of chyle beneath the peritoneum. The part of the mesentery corresponding to this is also much infiltrated with chyle

Stomach Mucous membrane covered with tenacious mucus. Vessels moderately full. Immediately above cardiac orifice there are numerous small opaque white bodies situate in the mucosa, looking like little lymphoid follicles - there are a few scattered over surface of stomach.

Duodenum normal.

Liver not enlarged, hepatic veins full of blood, central veins of lobules prominent.

(Base of Brain nothing special.)

Nothing special in gall-vessels

Aorta presents moderate degree of atheroma

The upper portion of septum of the ventricle, is opaque & presents numerous irregular fibroid ridges. Muscle substance firm, looks pale in spots. Aorta very atheromatous presenting numerous opaque yellowish-white spots beneath the intima, and here and there a few calcareous flakes.

Heart weighs 900 grams. — On exam. heart's muscle under microscope — only a few brown granules noted & no speak fatty degeneration.

Left Lung — crepitant throughout — on section — upper lobe slightly œdematous at base of this lung bronchial tubes contain a little mucus — there is no disorganization of the tissue. Patient has taken [illegible] for something General tint of lung reddish-brown. Right Lung also crepitant throughout. Brown tinging of lung very well shown in some places

Kidneys. 190 grams of full size, capsules adherent, surfaces granular. On section, cortices of full size — some of tubes of pyramids blocked with whitish deposit. Small arteries prominent — substance coarse

Spleen. 205 grams. — Firm, trabeculae distinct — artery a little stiff.

Card. 386

Pneumonia. Acute Cirrh

May 17, '80.

Peter Riordan æt 53.

Body parvage age and fairly well nourished; left leg presents numerous cicatrices & shows patina in thickened & central part; a thickened lg. ulcerating cicatrix on ant. pt. of which head me on outer pt of lower surface of left arm

he abd nothing peper. note: pylorus in rt. hypo. left, 6 centimeters below rt. border side of tip of Xiphoid cartilage

Thorax, no fluid on left side; ant border lung full in volume. On left side, small ant. of fluid & weak adhesions

Pericardium, nothing peculiar. note: rt. all. distended with clot firm, & clot slightly decolorized; in rt. vent. above colored clot firmly adherent & trabeculæ & valves and extending into pul. artery.

Left Auricle full of dk. clots; left ventricle almost empty, one small decolorized clot projecting into the aorta.

Further dissect of Art., rt. all appears normal, Rt ventricle, not apparently dilated & thinner from pul. ring 6 by 12 centimeters. Valves normal,

muscle substance looks pale

Left Vent hypertrophied, Cham not much dilated measuring only 9 centimeters in length; walls measure 2 & 2½ cm in thickness

Mitral Valves normal, aortic semilunar valves also normal, mitral orifice somewhat dilated & measures 5 centimeters, circumf 5 3/4 cent.

Heart weighs 5 oz 4 drams.

Left Lung, no adhesions, entire pleura, except part for lung, is covered by a thin pleuritic exudation.

In region of fissure between the mid lobe & inferior lobe, the membrane is thicker, leathery & tenacious

The Lung is crepitant only at anterior & lower portion

On cut, surface is moist and in upper lobe a semi purulent fluid pervades it; in lower lobe in the state of red hepatization, surface moist glistening and much blood & serum oozes from it on pressure

The bronchial glands are not much involved bronchi contain a gt of tenacious mucous; none of bronchi appear to contain plugs.

Right Lung crepitant throughout: on sect, upper & middle lobes tol. dry: lower lobe heavy, sodden & oedematous.

Spleen, a little enlarged: pulp mod. soft. weighs 200 grams

Kidneys – left, capsules thin & closely adherent & removed with difficulty. Surface, gran., puckered & mottled having irreg. whitish nodules & opaque spots scattered over surface.

On Sect it cuts with firmness, ~~cortex~~ cortex is diminished with opaque whit yellowish color

Right kid weighs 80 grams; capsule removed with diffic, & organ there presents a pec. appearance; from ant. surface upper pt looks contracted shrunken & has gran. translucent & also brownish tint. Lower half of the organ is fuller in volume, projecting more, smooth, not finely gran., is mottled, the general color being light yellowish & over it (the org) a stellate veins (none over upper pt.)

From post surface, a much smaller area on upper pt is affected. On section, this organ presents same appearance as other, & in some more marked

Stomach has nothing special noted

Liver is large not fibroid & contains much blood

Aorta somewhat atheromatous especially at lower pt

Bladder contains small amt urine

Brain — At base membranes a little opaque over the chiasma; dura mater is firmly (very) adherent & there are firm adhesions along the longitud. fissure; the surface of the brain visible, of pia mater are fairly well injected.

On remov. of membranes the convoluts are pale.

Careful Sect of Brain, nothing but a little extra fluid and moisture met.

"R. S. P."

Colon is inflamed and presents numerous ridges of yellowish white exudation. this condition continues up the ascending colon, many of the patches are very dark in color almost black towards the upper portion they are more scattered patches round

Case.

May 17th 1880. 387 Cirrhosis of Liver

Body moderately well nourished - Belly distended - Face, pale, and general surface very anaemic - In Peritoneum half a pail full of fluid - Omentum is adherent and thickened in the neighborhood of the femoral ring and is also attached to Sigmoid flexure - Lymph shreds over coils -
In Thorax, viscera pushed up a small amount of exudation in Pericardium & Pleura
Heart - nothing special about the valves the Aortic semilunars are a little thick - the heart muscle looks very pale -

Lungs - small - crepitant ~~throughout~~ - present nothing special -

Kidneys - average size - a little firm

Stomach contains a quantity of bile stained mucous, membrane is pale nothing of special note, tissues of the gastro hepatic omentum present the following appearances - the Portal vein appears normal, the vein as it enters the liver is considerably narrowed admitting only the point of the little finger -
Hepatic Duct - contains some mucous otherwise normal -
The Artery appears normal -
Liver - large, retains its shape, 2150 grammes - organ is pale covered the surface with numerous shreds of recent lymph - general surface of organ pale, on inspection the surface is a little rough & presents numerous

small granulations these are seen chiefly over the upper and anterior surface and the left lobe - On section the organ cuts with increased resistance the surface is pale, the liver lobules are distinct and are surrounded by narrow zones of transparent connective tissue the increase in fibrous tissue does not appear to be at all excessive - the lobular tissue is pale yellowish white in color and evidently fatty - Organs weighs 2100 grammes - Very fatty & increase of fat tissue never
in appears on superficial inspection
Spleen - weight 500 grammes - firm somewhat fibrous, capsule opaque
Pancreas - firm and hard.
The tissue in the Pelvis a good deal matted together by adhesions omental fat
fibrous & Fallopian tubes twisted - and contain semi-purulent fluid
The Uterus - full size, mucous membrane thick and Blood stained, arteries in
the walls numerous but look very yellow in colour.
Intestines, Convolutions, thick, pale, nothing special in the rectum.

18/5/80

388

Case Case of Volvulus. . Autopsy 16 hrs pm

No p.m. decomposition

Body that of a large well developed man. Abdomen greatly distended & very tense. On opening Peritoneum quantity of bloody fluid oozed out. The bowels are enormously distended. particularly two large coils which pass obliquely from Right Inguinal region through the Epigastric to the left Hypoc. region where they push up beneath the ribs. These appear to be coils of large bowel. they are greenish in colour, and of enormous size measuring 9" in circumference.

The peritoneum is lustreless & thin in places the gut has a dark almost gangrenous appearance

Shreds of lymph coat the small bowels and there is great injection of the same. Most of the coils of small bowel are not greatly distended. Nothing special beyond what has been noted in small bowel from Duodenum to ileoc valve. (Enormously distended coil above referred to is large bowel, it is full of gas and bloody fluid, no solid faeces.

Diaphragm greatly pushed up by the distended coil reaching on the left side to the level of the nipple.

Transverse colon - large & contains fecal masses, not much altered in colour

Descending colon - as far as Brim of Pelvis also normal, though large, at lower part upper part is not distended

Ascending colon - Presents nothing of special note.

Rejected, & pertinem emovit

Mucosa. Examination of stem — normal
Coecum & appendix & ampulla also normal
Rectum appears normal. The distended coils are found to be the sigmoid flexure which has twisted upon itself in such a way that its terminal part is compressed by the weight of the gut and mesentery which crosses over just above the brim of the pelvis. The flexure is of common length and has a very long mesentery. The constricting portion passes across the other at the pelvic brim about the last lumbar & then ascends along the right side of the abd. cavity passing obliquely & reaching the left hypochondriac region high beneath the rib & the apex of the nipple. The descending part passes down to the left & somewhat beneath the brim of the pelvic brim and goes beneath the constricting part in the last lumbar. The distension of these coils is extreme and the weight, with the fluid in very considerable. The great part of the extreme abd. distension was due to them. Abdominal open, the mucosa is very dark colored almost black. There is no constriction (organic) at termination but the gut is compressed and flattened. At the proximal end the sigmoid ends rather abruptly at the beginning of the flexure. The mesentery of this part is deeply congested & much swollen. Nothing of note in Stomach or small bowel. Other abd. organs normal. Nothing special in thoracic viscera.

25/5/80

389

Phthisis

Case.

Moderately emaciated. Signs of decomposition. In thorax; both lungs adherent. Left more than the right. No excess fluid in pericardium. Heart flabby soft commencing decomposition. Chambers normal size. Valves normal P.M staining in intima. Right lung contains a large irregular cavity at apex. tissue surrounding it infiltrated with chalky masses many of which are softened. Middle lobe crepitant. Contains a few tubercles. Upper & back part of lower lobe contains another large cavity. Base of lung congested. Left lung contains a large cavity at apex. Anterior portion of lung firm contains numerous tubercles caseous masses softening & intervening tissue having a grayish translucent appearance. Posterior & upper part of lower lobe also large cavity. tissue about it consolidated dark color & contains much fluid. Spleen large soft not amyloid. Weight 270 Grammes. Kidneys broken & how begun to decompose. A large caseous mass near the pelvis in one organ size of small walnut & in the other (right) is a similar but smaller caseous mass. Mesenteric glands enlarged, hard, yellowish white color. Section from Liver enlarged flabby. Some adhesions on right. 2090 Grammes.

upper surface tissue soft & reddish brown color.
Spleen not amyloid. Stomach mucous membrane stained irregularly in spots a dark color. Uterus. Cervix enlarged mucous membrane stained. Intestines. Deep ulcers found commencing in upper part of ileum with deep serious borders edges undermined. Considerable injection around them extending all through the small intestine & becoming more numerous towards the Ileo-cecal valve.

28/3+

390

Case Mediastinal Cancer involv. the lung

Patient, a man aged 68 had been ill for 3 months, with cough vomiting, & symptoms of disease of left lung. thought at first to be Phthisis. but subsequent the question of malignancy was raised

Body. Aged frame old, somewhat emaciated as an

In abdomen, nothing special on inspection. In thorax, right lung looks full in volume, left is pushed somewhat away from the mediastinum by a growth which occupies the front and upper part of the anterior region of the left chest. No adhesions in left right side, in left very firm adhesions below and as high as the upper margin of the lower lobe behind. About 3 or 4 fluid in this side. No adhesions or exudation in right side

Heart. Pericardium contains about 2 ozs of clear fluid. Chambers contain blood and clots. Valves normal - right annulo-vent. orifice large. Muscles substance soft. Right lung large in volume, emphysematous in anterior borders - no nodules -. Left lung Aorta trachea & oesophagus removed together. A large mass of new growth surrounds the root of the lung and projects forwards and upwards displacing the upper lobe of the to which it is intimately adherent. On dissection the following is the condition :- Oesophagus contains at the level of the tumour a bolus of softened food about 1½ inches in length and the size of the thumb This had evidently lodged there and had produced the choking sensation of which he had complained a little before death. After removal of it. the tube is seen to be a little compressed by the mass -. The Aorta is involved. Adhesions round the upper part of the mass, growing it The Trachea is normal. right bronchus the same. In the left bronchus are several large outgrowths from the mass which have perforated the walls

and appears a greyish white soft masses, almost occluding the tube. When slit open several of the primary branches are filled in the same way with soft neoplasm which has perforated the walls.

The Pneumogastric nerve of the left side passes directly down in front of the arch and penetrates the tumour, into which it can be traced for a short distance as a swollen infiltrated cord after which it becomes intimately involved & cannot be separated. The recurrent laryngeal appears on the other side of the arch also imbedded in the mass and, where it emerges is swollen to 3-4 times its normal size. The Pleura presents numerous nodular masses, greyish white in colour, tolerably firm most abundant at the lower margin of upper lobe behind. The lung and tumour together present the following appearance:— From the front a large mass is seen to occupy the root of the lung - as a reddish white mass which above has pushed the apex aside, it extends for 2 cm. and terminates below at the level of the lower pul. vein. It presents a ridge which overlaps the pulmonary artery. From behind the mass is not nearly so extensive and is covered by the aorta. A section made thro. the mass & the lung in the direction of the root exposes above a large mass of firm neoplasm, greyish white in colour and having a decided 'cancerous' aspect not soft. resistant to the knife. Has ruptured the anterior & upper pt. of the ant. mediast. apex and has pushed away the apex of the lung and compressed the ant. pt of upper lobe. The mass has extended in from the root of the lung and involves the inner half of the upper lobe, the firm masses extending out to within 3.5 Cm of the pleura. In this area remnants of pulmonary tissue are seen in small segmented areas. A bronchus 4 Mm in diameter passes out

interlobular prsnce & the pleura and there are many nodules in connection with it. The upper and back part of the upper lobe is compressed and contains many small nodules. The lower lobe is airless, presents small nodules in the upper and back part

The pulmonary artery is dilated. The right branch very large where it enters the lung the lumen has so pressed upon it that the lumen is greatly diminished. The walls of the upper division were in contact. The pul. vein of the upper lobe is also much compressed.

Nothing special in the other organs

May 24th 80

Case 391 . Leucocythemia . See printed report
Hagen (Dr Lachapelle's patient

23/5/80

392
Case -   Caries of Ankle. Tub. Meningitis.

♀ - aet 4. patient of Dr Parker. Ill for some months with disease of ankle; & latterly evidence of Potts curvature.

In abdomen. coils of intestines dark coloured & in spots show crops of tubercles in patches. In thorax left lung adherent. Heart - of average size - nothing special in valves - Lungs crepitant, but present miliary tubercles scattered through the tissue chiefly in upper lobes - they are somewhat larger than normal. Spleen. large - pulp firm, contains tubercles.

Kidneys. of full size - a few small greyish nodules

Liver presents clear small granules in capsule and in substance over two tubercles are to be seen

Nothing special in stomach - In intestines Peyers patches ulcerated in ileum, bases - nodular - margins injected, most of them in long axis of gut and on peritoneal surface many small tubercle.

Brain. No lymph at base, but parts matted over chiasma and out Sylvian fissures. At the left Ant. perf. space & extending into the Sylvian fissure of this side, back over the crus to the cerebellum, is a coagulum, of moderate thickness, & fresh looking. The vessels were carefully removed slit up. but no aneurysm or laceration detected. On small vessels - miliary tubercle in variable numbers. Ventricle a little large. walls soft.

At 8 & 9 dorsal v. there is a swelling situated to the ~~left~~ right of the bodies & when cut open gave exit to about a tablespoonful of pus. The bodies of these two vert. are involved. the int. vert. disk between them has disappeared - & at a corresponding point on spinous process there is a projection. Ankle joint extensively diseased - cartilages bare

Case. 393 Insufficiency of Mitral Valve. Pneumonia. 25/5/80
– McAllen aet 4 yrs 1 month.

Aged 4.1 month

Slim weak child – about a year ago – had ankles swollen (winter of 78–79). Ill for 2–3 weeks – was in bed – could not put on his boots – Doubtful of rheumatics. Never Sc. fever. Nor measles – nor whooping

For more than a year has had shortness of breath – coughs often – & did not walk much. – Had worms – . 3 months ago. [illegible] to waist – Has been in bed over a month – Short breath, choking at first could not lay down. Could not lie on back ~~[illegible]~~ could lie best on [illegible] – lying down with hands up – . Cough great. – [illegible] for 6 hours of life.

For last year always cold – cold hands & feet. – –

P.S. The father says that the child has had swelling of the legs 3 times within the past year & a half – with painful condition of the joints, quite lame with them. Lasted about 10 days

– Very cold always.

23/5/80

392

Case - Caries of Ankle. Tub. Pneumonitis.

+ - æt 4. patient of Dr Barker. Ill previous months with disease of ankle; & latter[s] - evidence of Potts curvature. In abdomen, coils of intestines dark coloured & in spots show crops of tubercles in patches. In thorax left lung adherent. Heart - of average size - valves - Lungs crepitant, but present miliary tubercles scattered through the lesser chiefly in upper lobes - they are somewhat larger than normal. Spleen. large - pulp firm, contains tubercles. Kidneys. of full size - a few small greyish nodules Liver presents clear small granules in capsule and in substance certain tubercles are to be seen Peritoneum & stomach - In intestines Peyer's patches ulcerated in places - nodular - mayus injected, part of them in hypertrophied and in peritoneal surface many small tubercles. Brain. No lymph at base, but parts matted over the pons and Sylvian fissures. At the left Ant. perf. space & extending into the Sylvian fissure of that side, back over the cms to the cerebellum, is a coagulum, of moderate thickness, & pinkish looking. The vessels were carefully removed & cut up. but no aneurysm or laceration detected. Small vessels - miliary tubercles in variable numbers. Ventricles a little large. walls soft.

28 & 9 dorsal v. there is a swelling situated to the left of the bodies & when cut open gave exit to about a tablespoonful of pus. The bodies of these two vert. are involved. the intervert. disk between them & the corresponding portion of spinous process & a projecting. Ankle joint extensively diseased - cartilages

lost

– McFallen –

25/5/99

Chr. Valvular Disease –
Mitral

394

Cartoon of lung Plate

Aortic Valve disease 6/6/80

Body average size. moderate wasting no special rigidity face brownish yellow in colour. no dropsy.
In Abdomen slight increase in acosity.
In Thorax adhesions on the left side behind, no increase of pericardial fluid. Heart weight 580 grammes large, right chambers contain dark blood and small leathery clots. Left auricle full of dark clots. Left ventricle contains blood and an intimately firm buff coloured clot which is closely interlaced with the anterior wall of the ventricle - on further dissection the heart the right auricle presents nothing special - Right ventricle is large measures 13 inches (thirteen) walls of increased thickness ¼ inch (5) to eight (8) M.M. tricuspid orifice (15) fifteen C.M in circumference valves normal Pulmonary Semi Lunar valves semitransparent (as segments) Left auricle somewhat large Endocardium opaque Mitral orifice measures about twelve (12) C.M in circumference, valves are thin & normal chamber of Left ventricle moderately dilated measuring eleven (11) C.M across aortic ring & opens 17 C.M in circumference - walls hypertrophied measuring from 1½ to 2 C.M. Muscle substance a little pale the apices of papillary muscle fibroid - small fibroid patches on Endocardium of Septum close to aortic ring Aortic valves incompetent a stream of water flows through freely when slit open aortic ring measures 8.5 C.M across the faces of the valves, the segments do not look much affected, the right anterior measures 2.7 C.M across its edge and is 1.8 across its face, it is opaque stiff and somewhat contracted at its anterior attatchment

Canadian Medical Association Journal
3640 University Street, Montreal

Case 394
P. 219 (at top of page)

This is the best one I can find.

(Jew)

the Posterior cor… this segment has a
very small cup… only change it admits
a probe about 1… appears of normal
size and is not… measures 2.8 C.M across
and 1.7 across … and a little curled
the left antero… flat the edge
of this valve … the arterial wall
but stands out … measures 2.6 C.M
across its edge … ordinately thickened
the whole valve … the aspect of the Anterior
Coronary artery … the artery itself
is normal An… C.M in width
presents numer… browish in colour
and the whole … normal

Left Lung upper lobe crepitant only at extreme apex, anterior border and in the triangular prolongation which passes over the heart. the rest of the lung is firm solid hard the upper part of lower lobe is in the same firm hard state the lower 2/3 (two thirds) of it crepitant the Pleura over these indurated regions is not much thickened and there are only a few adhesions at the back part of the apex, on section from apex to base the following condition was presented. the Upper Lobe its entire Posterior & Lateral aspect is converted into a firm mass of fibroid tissue a section presenting a somewhat marble appearance from the intermixture of dark brownish black areas with irregular strands of fibrous tissue many of these brownish areas are evidently districts of lung tissue not yet involved in the fibrosis. they are softer and are often quite surrounded by the

394

Contours of lung Plate

Aortic Valve disease 6/6/80

Body average size. moderate wasting no special rigidity face brownish yellow in colour, no dropsy.
In Abdomen slight increase in serosity.
In Thorax adhesions on the left side behind, no increase of pericardial fluid. Heart weight 580 grammes large, right chambers contain dark blood and small leathery clots, Left auricle full of dark clots, Left ventricle contains blood and an intimately firm buff coloured clot which is closely interlaced with the anterior wall of the ventricle - on further dissection the Heart the right auricle presents nothing special - Right ventricle is large measures 13 inches (thirteen) walls of increased thickness ¼ five (5) to eight (8) M.M. tricuspid orifice (15) fifteen C.M in circumference valves normal Pulmonary Semi Lunar valves semitransparent (as segments) Left auricle somewhat large Endocardium opaque Mitral orifice measures about twelve (12) C.M in circumference, valves are thin & normal chambers of Left ventricle moderately dilated measuring eleven (11) C.M round aortic ring & opposite 17 C.M in circumference - walls hypertrophied measuring from 1½ to 2 C.M. Muscle substance a little pale the apices of papillary muscles fibroid - small fibroid patches on Endocardium of Septum close to aortic ring Aortic valves incompetent a stream of water flows through freely when slit open aortic ring measures 8.5 C.M across the faces of the valves, the segments do not look much affected, the left anterior measures 2.7 C.M across its edge and is 1.8 across its face, it is opaque stiff and somewhat contracted at its anterior attatchment

the Posterior Coronary artery which passes off behind this segment has a very small orifice greatly contracted by atheromatous change it admits only a probe about 1/2 M.M. in diameter. beyond this the artery appears of normal size and is not atheromatous. the Posterior segment measures 2.8 C.M across and 1.7 across the face - it is thickened at the edge and a little curled the left Anterior is chiefly affected as the vessel lies flat. the edge of this valve does not remain in contact with the arterial wall but stands out nearly a centimeter from it, it measures 2.6 C.M across its edge and 1.5 across the face. the edges moderately thickened the whole valve opaque and slightly foreshortened. The ostium of the Anterior Coronary artery is a little contracted by atheroma the artery itself is normal Aorta ascending portion. measures 11.5 C.M in width presents numerous atheromatous patches chiefly yellowish in colour and the whole coat is stiffened and less elastic than normal

Left Lung upper lobe crepitant only at extreme apex, anterior border and in the triangular prolongation which passes over the heart. the rest of the lung is firm solid hard the upper part of lower lobe is in the same firm hard state the lower two thirds 2/3 of it crepitant the Pleura over these indurated regions is not much thickened and there are only a few adhesions at the back part of the apex, on section from apex to base the following condition was presented. the Upper Lobe its entire Posterior & Lateral aspect is converted into a firm mass of fibroid tissue a section presenting a somewhat marble appearance from the intermixture of dark brownish black areas with irregular strands of fibrous tissue many of these brownish areas are evidently districts of lung tissue not yet involved in the fibrosis. they are softer and are often quite surrounded by the

fibroid areas. a similar condition extends throughout the lower and lateral part of the upper lobe. in the upper and lateral part are several firm nodular masses isolated from the general disease these on section present the same fibroid condition rather more than the upper third of the lower lobe presents the same appearance as above described firm dense indurated tissue the lower part of the lower lobe is crepitant and on section coarse looking & of a dark brownish black colour. in all of these fibroid areas no dilated Bronchi are seen, on slitting up the Bronchial tubes they are not dilated - Left Lung 930 grammes.

Right Lung - no adhesions except one small one at apex Upper Lobe - posterior and lateral regions firm solid and non-crepitant the anterior border crepitant and very emphysematous, the pleura covering the fibroid areas is somewhat thickened. on section the fibroid area presents similar characters to that already described the middle lobe is firm & from induration very emphysematous. in the upper & lateral regions of the lower lobe are several firm nodular masses of induration the pleura over them thickened and in several spots a little puckered. there are several spots of small extent in the Lower Lobe which appear on the pleura as small areas of thickening when cut into they are found to be localised spots of cirrhosis surrounded by air containing lung tissue, the crepitant portion of this lung presents the ordinary appearance of brown induration - Right Lung weighs 1000 grammes

Splen - 225 grammes. not very firm natural looking
Kidneys - Capsule detaches readily numerous cysts on the surface the organs firm arteries not unusually prominent - no diminution of cortex. Right 170 grammes left 150 grammes.
Stomach presents nothing abnormal.
Liver small and presents 2 deep grooves passing from the posterior border in the antero posterior direction along the upper surface they are smooth, capsule a little opaque at the bottom of the furrows. organ not at all cirhotic contains a good deal of blood, the left lobe is somewhat firmer organ weighs 1380 grammes.
Intestines - present nothing special.
Thoracic Aorta contains dark Blood the vessel presents many spots of atheromatous thickening the Arch of the aorta is somewhat dilated

395

Phthisis 6/6/80

Mr. Findly - Isabella Findly 43 -
Body much emaciated -
In Abdomen about a pint of clear Serum
In Thorax - universal adhesions on both sides left a case of fluid in
R. Pericardium, Heart small tricuspid orifice 5 inches in circumference
Right ventricle not dilated nothing about the valves on either side -
Left Lung fully crepitant - nodular in upper lobe Pleura not thickened
a cavity the size of a small orange at apex, throughout upper lobe
innumerable small greyish granulations - chiefly arranged in groups
many of them evidently of the nature of peribronchial granulations -
& no large caseous areas, Lower Lobe is pne, nothing special
in Bronchial glands. Bronchial tubes much congested -
Right Lung scarcely crepitant in any part - Pleura extensively
thickened - there is empyema of the lower and back part of the Pleura
caused by a large sloughing perforation into a cavity the orifice
about three by three c.m. edges in a sloughing state particularly
the upper one which has a dark greyish color - on section
the lung is riddled with cavities there is not a single spot
of normal lung tissue to be seen the cavities communicate
with each other and are crossed by numerous trabicular
remnants of Bronchi and vessels - the Bronchial glands are enlarged -

Kidneys Pale - lobular structure still evident -
Spleen - capsule thickened in spots. tissue of a light brownish
color -

Stomach not special - mucosa pale - gall ducts patent
Liver deformed left lobe unusually flattened adhesions between
its upper surface and the diaphragm a comparatively narrow
neck separates the 2 lobes a very prominent posterior process
organ is soft - somewhat pale and looks fatty -
Intestines - a few small ulcers at lower end of Ileum one or
two the size of a pin's end but in large bowel

Umbilical hernia (Congl)

396

Child born in U.S.A. June 3rd 1880
Length 34 Cm. Head, upper limbs and
Chest well formed. There is An Extensive umbilical
hernia. Apparent an extensive spina bifida
in lower dorsal region. Extro version of the
Bladder, External generative organs defective.
The umbilical Cord is attached to left
side of the sac and divides into two branches,
one passing towards the thorax, the other the
longer portion passing beneath the sac and
crossing the upper end of the open bladder
tracking to the right inguinal region.
The umbilical is large & was distended
with fluid. It contains the liver, Stomach,
& intestines & Spleen. The kidneys lie
behind the sac. The coils of small
intestine matted together by adhesions.
Vessels of mesentery & peritoneum in-
jected In thorax. Pericardium
contains an extra amount of fluid. Heart
placed transversely lying between 2nd & 5th
ribs. Apex pointing upwards On dissection
of Heart right auricle appears normal;
foramen ovale almost closed; valves of
Heart

397
7.

Mutual Insurance 8/6/80

898

19/6/80

Pyaemia -

Senile Gangrene

399

Aug 24. 80. Post mortem 5 hours after death. Fluid blood that escaped from heart coagulated in a few minutes

Body that of a medium sized Elderly man, well nourished. Left leg & foot swollen, red & inflamed Skin over dorsum of foot & outer & back part of leg gangrenous. There are also gangrenous Bullae in popliteal space & inner surface of knee

Thorax. No adhesions. In Pericardium. Normal amount of fluid. Patch of attrition on right ventricle. Right auricle distended with a large firm clot, decolorized in its upper portion. Right ventricle – a decolorized portion is adherent to valve & extending into ~~auricle~~ pulmonary orifice. Left auricle – Large dark clot. Left Ventricle – small decolorized one On further dissection of the Heart, valves on right side, tricuspid a little thick & opaque Orifice over six inches in circumference. Pulmonary semilunar fenestrated. On left side mitral valve healthy Papillary muscles fibroid Endocardium of septum opaque. Aortic valves healthy Muscle substance of heart dark brown. Coronary arteries stiff.

Right Lung. Crepitant. Fibroid patch at apex Anterior portion & in fact entire lung slightly oedematous. Left Lung similar Not much blood in either organ except at base. Spleen ~~full~~ average sized, firm. Kidneys a little small & firm. Arteries not specially prominent Surface smooth. Liver of average sized & healthy looking. Stomach Contains quantity of ½ digested food. Mucous membrane healthy Nothing special in Intestines except some congestion of mucosa at lower part of Ileum Aorta presents a few patches of atheroma mostly at terminal portion of arch very few down the abdominal portion. Left femoral is stiff, walls thick, intima a little roughened

Extensive atheromatous & calcareous degeneration of Anterior tibial artery. Senile gangrene

11/6/80 400

Phthisis

Body mod emaciated Abd. pos of viscera normal
Thorax. Left Lung adh at apex R Lung throughout
entire extent. Heart contains large amount of blood
particularly in right chambers In R Appendix numerous
fibrular excrescences interlaced with trabeculæ. The lips of
Appendix filled up what these colourless fibrous masses
Tricuspid orifice large admits hand one feels
similar excrescences in apex of right ventricle. Walls of these chambers
are thickened. Left Auricle not distended Endocardium
opaque. Left Ventricle chambers not dilated walls
not thickened Mitral orifice 5 in in circumference valves
normal
Lungs Left. Crepitent in with exception of apex & upper part
of lower lobe nodular bodies felt felt throughout lobe
At apex cavity size of orange with several communicating
cavities. Walls smooth blood stained in spots. Upper part of lower
lobe presents numerous groups of tubercles and same are seen
scattered throughout tissue of this lobe in upper bronchial part.
The lung Œdematous. The lower part of lower lobe covered with
recent thin pleuritic membrane. Glands of this side
enlarged not caseous.
Right lung very feebly crepitent at lower part. Layers of pleura
universally adherent. The upper & back part of upper lobe occupied
by large cavity with smooth pigmented walls and crowded by only a
few bronchia at base. Anterior part of lung contains smaller

cavities caseous masses and few tubercles
Middle lobe as emlam numerous cavities.
Throughout lower lobe also emlams cavities with
many fine groups of tubercles & caseous masses.
Spleen slight increased in size pulp soft.
Kidneys. nothing abnormal.
Stomach & Duodenum. present nothing of special note.
Liver not enlarged a little soft somewhat mulmegged
probably fatty.
Large bowel. ~~Ulcers in Ileum & Caecum~~.
In Caecum solitary glands enlarged a few small
superficial ulcers in spots.
In Ileum no visible ulcers. but towards upper part of
Ileum is area of one inches in which are numerous
submucous extravasation of blood.

Brain

11/6/80 Insular Sclerosis.

401

Body. Male of thin bald man Autopsy about 4 hrs after death. Nothing on superficial inspection. In abdomen pos of viscera normal thro
Thorax Lungs free from adhesions & collapsed.
Heart pericd contracted left ventricle particularly hard
Thick blood & dark clot in Right auricle. Rt V same
on special dissection of these chambers.
Left ventricle empty.
Further dissection of heart valves on right side normal
on seg of pulmonary semilunar semilunar fenestrated.
Tricuspid surface dilated admitting head one.
Valves of left side normal. Muscular & walls range from
bout ½ 2 – 2½ Cm in thickness from
L. ~~muscular~~ very dense & thick on removal of calvaria
Pacchionian bodies unusually prominent
Removal of brain ~~with~~ an unusual amount of serous effusion
escaped at base. Arachnoid a little opaque Arteries unusu
atheromatous. vertebrals ~~stiffened~~ stiffened basilar presents
numerous spots yellowish colour on wall (Atheroma)
semilun cerebrum of pulchy atheroma in all branches of
Circle of Willis and internal Carotid. especially thickened just
beyond the point of entrance to brain first part of basilar
somewhat dilated and distinctly pulsated
Anterior cerebrals are very much beaded and a similar

Cerebellum extends out branches of middle cerebral
There is no special exudation of thickening about vessels, nerves
the vessels & hemispheres are not distended and arteries can
be readily traced & no small spots of Atheroma on their walls.
On removal of membranes the surface of convolutions look
normal

Pre frontal sec on right side is exposed a small greyish spot
of situated in white matter just above the Right third
frontal convolution.

Second front section presents nothing special on right side
but on left side just below lateral ventricle is small greyish
spot similar in character to one just noted. the white
matter in this section ends with ~~more~~ unusual toughness

Frontal Section On left side there is a spot situated in
white matter, at upper angle of lateral ventricle
which is softened contains thin colored fluid no
definite wall but present numerous small firm
bell like & shreddy tissue about the size of pea — is size of
this spot. Small similar but smaller spot in Corpus Callosum
in this section. The left caudate nucleus & outer segment
of lenticular nucleus present several small irregular spots
filled with thin fluid. and presenting the ~~the~~ same
shreddy appearence The right lenticular nucleus
also presents numerous spots of same character
The spot described on peduncular frontal section at lower
part of the ventricle is found to be larger on the upper
surface of this section

Parietal section. There is a spot on right side just outside caudate nucleus in white matter.
In white matter throughout the occipital lobes there are several of the same small greyish spots
Another spot just outside the ~~right~~ left corpus dentatum in cerebellum.
Medulla normal

Left Lung normal Right L crepitant, lower post border of middle lobe firm intensely oedematous, fluid which oozes slightly turbid lower lobe is very slight crepitant. presents numerous irregular masses firmer than surrounding tissue thus on section stand out above. and presenting the characters of hepatization in early stage.
In lower part is larger area in which the red hepatization is more extensive and better marked.

In stomach lips y rugæ and in duodenum thereon spots y extravasation.
Liver not enlarged not scirrhotic no cicatrices.
Not specially form.
Kidneys capsules pret detachable surfaces smooth
Section no increase y pkind tissue. substance
appears perfectly normal,
Splene much pressed a little enlarged form
bateuke prominent
Aorta. normal. Carotids dito.
Intestines. Nothin special in small intestines.
Numerous small ~~Peye~~ Peyer's glands in Ileum
enlarged.

402

June 18th 1880 Emphysema.

Body that of a short, moderately stout woman: general anasarca. Belly slightly prominent: face dusky; lips livid: oedema of labia.

In abdomen about a quart of serous fluid: position of viscera normal, but left lobe of liver projects 1½ handsbreadths below ~~ensiform~~ Ziphoid Cartilage

In thorax Considerable serous effusion in both pleurae: adhesions on right lung, post. part & at apex, none on left side. Pericardium contains considerable excess of clear serum. The visceral layer covering right auricle covered with numerous spots of fibroid thickening. Auricles distended with large dark coagula Rt. Vent. moderately distended. Left Auric. contains fluid blood & one small clot: Left Vent. almost empty. On further dissection of heart: Rt. Aur. dilated, not much hypertrophied: trabeculae distinct: Tricuspid orifice large, nearly 5" in circumference: valves a little stiff & firm at apices. Rt. Vent moderately dilated, measuring from pulmonary ring to

apex 11 cm. Papillary muscles are in a condition of extreme fatty degeneration, having a mottled appearance from presence of numerous yellowish white spots immediately below endocardium. These exist also in places upon the trabeculae, but are nowhere so abundant as in the papillary muscles. The muscular wall is slightly increased in thickness, measuring 6-10 mm. Subpericardial fat over the ventricles is 6-8 mm. in thickness. Left Aur. small appearing very much so when compared with the right. Mitral orifice measures 3 3/4 in. in circumference: valves normal: papillary muscles look healthy; left chamber not enlarged measures only 7 cm. from apex to aortic ring. Semilunar valves normal: aorta small slightly over 6 cm. in width. Pulmonia healthy

Left Lung Crepitant throughout, except at extreme base when collapsed. Apex of lung is firm & contains but little air. The organ presents typical appearance of emphysema. Process is most marked at the apex & ant. border, under surface of lower lobe.

Right Lung Crepitant in upper lobe, heavy and airless in lower one, over which the pleura is very firmly adherent. This lung

presents same emphysematous appearance as the other: and on surface of upper lobe several small spots of interlobular emphysema. The upper lobe on section is excessively edematous. On section of lower lobe this is found to be airless & in a state of extreme edema. The surface on section has a gelatinous appearance, is bloodless & on squeezing it gives out thick yellowish serum exudes mixed with little or no air.

Kidneys appear tolerably healthy: a little increase in firmness: capsules removed with slight difficulty. Substance normal.

Spleen - size normal: capsule thickened & firmly adherent to diaphragm. Substance a little firm. Malpigian bodies tolerably distinct

Stomach: small vessels of mucosa injected otherwise natural looking. Bile duct pervious

Liver. Adherent to the diaphragm: small. Ant. margin grooved in transverse direction & capsule in this region thickened. No small granulations are seen over surface of ant. border and under part. On section, organ presents a typical nutmeg appearance: the centres of many of the lobules are stained yellow with pigment. There is considerable increase of fibroid tissue in organ: but individual lobules appear not isolated by visible strands

of tissue

Intestines present patches of dusky engorgement: in some places amounting almost to extravasation. Solitary glands of Peyer small but distinct. Nothing special in large bowel. Brain shows nothing special on superficial examination.

There is retroversion of uterus & adhesions between its post. surface & rectum. Cystic disease of the left ovary: & adhesions between both ovaries and pelvic walls.

240

19/6/80

403 Fracture of Legs - Ulcerative Endocarditis

Thibadeau

Apoplexy of Pons - of Cerebellum

21/6/80

404

Body that of an averaged sized, very well nourished woman. Post Mortem 8 hrs after death. Nothing special on External Examination. On skin oozed a moderate amount of Blood. Calvaria dense & hard in places increased ~~to~~ in thickness. The D. Mater looks normal. ~~Lateral~~ Longitudinal sinus contains a small clot. Pacchionian granulations in moderate number. Small ossific plate in falx near anterior end - On removal of Brain a good deal of Blood escapes. On stripping off the D.M. a thin extravasation of Blood is seen beneath the arachnoid, which has the following extent: over the inner part of under surface & Temporo Sph. lobe at the Lft Sylvian fissure extending over the 3rd frontal lower part of Parietal Convol. extending as far as the occipital. There is a slight amount over the ascend. convol. at the outer pt. of left Syl. fissure. ~~The~~ Over the Cortex vessels are moderately full & there is a good deal of serous infiltration beneath the arachnoid over the Sulci. At the Base the arach.d is opaque. There is no extravasation in the perforated spaces. The Arteries are thickened atheromatous in places. The Basilar & Vertebrals are large. The atheroma extends to the very small branches of the Arteries. When P. Mater stripped off the Cortex looks natural

Brain: On slicing following noted -

Prefrontal section – Normal – Substance of brain somewhat moist.

Precentro-Frontal Section – Normal –

Frontal Section – Immediately above Caudate Nucleus there is a spot reddish yellow in color, tissue looking loose. Immediately at outer section of Lenticular Nucleus there is a spot reddish color, softened & 4 × 2 m m in extent. White sub. of Internal Capsule looks normal. The vessels of the ganglia of both sides are wide,

Parietal Section – This cut somewhat obliquely pass through the cent. portion of the Pons, revealing in it a small extravasation. The yellowish red spot on the left side is still better seen in the anterior part of this Secn & is of considerable extent extending across the upper fibres of the internal Capsule & looking like the remains of an old apoplectic clot. A similar one but smaller occupies the outer side of the Lent. Nuc of this side. A small one is seen in a similar situation on the other side – The Thalami are look natural, but there are several small yellowish brown spots looking like remnants of old extravasations occupying the body of the Pons situated more in the upper than lower surface than extravasation. On lifting up the Cord & exposing the 4th Vent. the L. [illegible] appears where burst in at the upper & left part immediately above the Restiform Bodies – (Continued on p. 245)

Occipital Sulcus nothing special

Cerebellum on section an old apoplectic cyst occupies the position just external to the C. Dentata on the left side. Walls yellowish white in color
~~Contents serous~~

Spinal Cord: — A few small cartilaginous laminae.
Arachnoid is not opaque.

Thorax & abdomen. In abd. position of viscera normal. In thorax no adhesions of pleurae. In pulmonary division of the heart; chambers no clots. On further section nothing special on the Rgt. H. Tricuspid admits nearly 5 inc. Left H. Muscles stiff. Mitral valves a little opaque. Pulmonalis. Aortic V. Normal. Muscle looks a little pale.

Lungs. L. lung crepitant throughout. Does not contain an excess of serum, nor is the Base much congested. There are a few spots of Ecchymo. scattered through the lower lobe.
R. Lung also crepitant

Spleen - small

Stomach - M. Mem. looks normal. Duodenum Bile flows. On pressing comes up.

On further dissection the clot is found to occupy the left side of the pons at its posterior part. Anteriorly it comes forward to within ¼ in of the surface in front of the 5th nerves. and it extends in the cross of the left side nearly to the locus niger. From anterior Medulla to cerebellum. Behind the condition is as follows. An extravasation of blood and laceration of substance is seen at the upper and outer part of the floor of the ventricle extending from 2·5 cm from the calamus to within 1 cm of the testes. The substance of the floor as far as the widest part is unaffected above the raphe deviates to the right and at the outer part of the left side blood clot can be seen below the grey floor. The clot has lacerated the left superior peduncle. and the contiguous part of cerebellum. extending above as far as the corp. quad. and (lacerating the outer part of valve of Vieussens) and passing forward is continuous with the clot in left cross. The laceration is in volume equal to a large walnut.

This was evidently an instance of so called central pneumonia.

24/6/80

Pneumonia. Congestion of Brain

Patient of Dr Blackader's, girl at 12. Taken ill on Monday evening 21st. Symptoms - high fever 105 almost continuous, rapid loss of consciousness, tremor & extreme nervous prostration, very little cough & scarcely a symptom pointing to the lungs.

Autopsy. Body well nourished. On remov. calv. dura normal - adherent. Pia deeply injected - large & small vessels. No lymph at base, not special excess of fluid in subarachnoid. On section organ firm, puncta vasculosa very marked; decided excess of blood in substance. Ventricles normal, walls not soft. Nothing special in substance. Heart rt. chambers full of dark blood & clots - chambers - valves & orifices normal. Lungs. Rt.; upper part of lower lobe is solidified & in state of red. hepatization, firm, airless, section dry - granular. & several of the bronchi in it contain fibrin plugs. The area is about as large as the palm of the child's hand. The rest of the lung contains a good deal of blood. not oedematous. Left lung heavy at base - & contains more blood than normal. no consolidation

Spleen enlarged - 1/2 as large again - soft.

Kidneys - normal. vessels full -

Nothing abnormal in other organs.

466

Tuberculosis Lungs & Kidney
Atrophy of the Kidney

June 29 - 80

Body that of a small-framed woman somewhat wasted, and excepting the face, not Emaciated. Still a layer of Panniculus beneath the skin. No extravasations nor spots of discoloration.

In Abdomen, position of viscera normal. Uterus - retroverted. Slight adhesions on posterior surface. Thorax - Few adhesions in right pleura. No fluid in pericardium. In Heart few dark clots in right chamber. Small partially decolorized clot in left auricle. Left ventricle empty. Altogether, very small amount of blood in the heart. Fair amount of blood escapes, on removal of the heart, from the vessels. On further dissection of the heart - Nothing special in right Chamber. Left Heart - Mitral valves a little opaque. One segment of aortic semilunar slightly opaque.

Lungs. Left - Crepitant throughout. No masses of consolidation. No caseous appearance. Scattered over pleura of upper lobe on the anterior surface are numerous small flattened tubercles. On section, small miliary tubercles throughout this lobe. A few smaller ones seen throughout lower lobe. These small tubercles are somewhat larger than in diffuse general tuberculosis.

Lung, Right. Numerous small miliary tubercles in this lung also chiefly in the upper lobes. No Caseous masses. The tuberculous nodules are comparatively large grayish white in color Bronchial Glands are not enlarged. Nothing in the Bronchial Tubes.

Spleen is small. Nothing special to note.

Right Kidney greatly reduced, not much larger than the a testicle. It presents a roundish swelling at either end, rather soft, and somewhat narrowed and contracted at the central part The rounded ends contain a white pulpy-like substance which is mixed with gritty particles. Towards the Pelvis of the kidney the tissues becomes cicatricial and three calculi about the size of large peas are embraced in it. The calculi are smooth pulpy form, very firmly embraced. The pelvis is obliterated and the ureter not pervious

Left Kidney much enlarged retains its shape. On Section the capsule detaches with difficulty & is thickened. The upper portion of the organ is occupied by three large cysts in connection with the dilated calyces in this situation. The walls are
(2 m) thick grayish white in color, Inner surfaces rough irregular & shreddy & they contain a purulent fluid. A smaller one exists at the middle of the anterior

anterior portion. The renal substance at the end of the organ is considerably expanded, somewhat pale, but contains very few nodules. Lower half of the organ is enlarged in volume, contains no cysts, but the substance is extensively diseased. Scattered throughout it are numerous small grayish white nodules, scattered irregularly through the cortex & pyramids. They are firm. The smaller of them nodules are firm greyish white in color often very closely set together, and fusing to form larger masses. In the pyramids they are often arranged in a linear direction extending up the tube. At several of the pyramids, the disease is most advanced just at the mammillar, the tubes of which are distended with greyish white matter. On the surface, numerous small pin head nodules occur.

Ureter is thickened, not apparently ulcerated

Pelvis of the Kidney is thickened, mucosa infiltrated & the calyces & infundibula at the upper sections dilated into saccules as above described

Bladder - not enlarged, contains a few ℥'s of very turbid urine. Their mucosa is found roughened & presents numerous small discrete losses of substances. These are circular from 2 to 4 m m in diameter, grayish in color, Edges slightly prominent

and the intervening mucosa injected. The
ulcer is most extensive at the upper part
of the organ. At spots on the mucosa, there
are small miliary granulations presenting all
the general characters of miliary tubercle
Ileum retracted, Os narrow

Stomach – Mucosa thin at the fundus, slate coloured
at pyloric Zone – presents nothing special
Liver – has a long tongue-like projection passing
from the left lobe almost at right angles
towards the posterior part. It is about the
size of the palm of the hand, thin & separated
from the rest of the left lobe by a narrow
groove
Intestines – No ulceration in large or small bowel

Marrow of left Femur still fatty but presents some
areas of reddish infiltration

407.

Ulcerative endocarditis
& Aneurism

First description of syphilitic aneurism

Robert Jackson. 30

Body of an
man Lar
extend. in
one just
omentum
deal of
about si
between
In Thorax. Rp
Left at upp
mediastinum
a position
& extends
ribs &
adhesions
opening
about
On Visceral
On right
Chambers
small clo
Left auric
Left ven
Chamber

1/7/80

Montreal General Hospital

PATHOLOGISTS NOTICE.

Robert Jackson. 30 died

on Thursday 2.15 am

~~Brief~~ History Long Standing
aortic disease — for
past month of pulmonary
obstruction —

Chief Symtoms: Pain — dyspnoea —
cough. Latterly delirium
Coma with incontinence
of faeces & urine —

Diagnosis:

Mort. Aortitis

A. Johnson

House Surgeon.

and the intervening mucosa injected. The
disease is most extensive at the upper part
of the organ. At spots on the mucosa, there
are small miliary granulations presenting all
the general characters of miliary tubercle
Uterus retroverted, Os narrow

Stomach – Mucosa thin at the fundus, slate colored
at pyloric Zone – presents nothing special
Liver – has a long tongue-like projection passing
from the left lobe almost at right angles
towards the posterior part. It is about the
size of the palm of the hand, thin & separated
from the rest of the left lobe by a narrow
groove
Intestines – No ulceration in large & small bowel

Marrow of left Femur still fatty but presents some
areas of reddish infiltration

407.

Ulcerative endarteritis
& Aneurism

First description
of migratic
aneurism

Robert Jackson. 30

Body of an average sized somewhat emaciated man. Large thin cicatrix left side thorax extend. into axilla. & two small thin one just above right knee. In abdomen omentum adherent & parietal wall. Good deal of pigmentary staining about it & about sigmoid flexures. Adhesions between diaphragm & upper surface of liver. In Thorax. ~~Left~~ Right lung universally adherent. Left at upper part. In upper part of anterior mediastinum is a rounded projection occupying a position beneath first piece of sternum & extends to the right beneath first two ribs & the clavicle. It is soft & has no adhesions. Pericardium enlarged & on opening it contains blood. Contains about 3XIX of fluid blood & clots. On Visceral pericardium are fibroid thickenings on right auricle. On dissection of the chambers right auricle contains a few small clots; right ventricle empty: Left auricle contains about 3j of blood. Left ventricle is large in proportion to other chambers, & contains a small

On further dissection of heart, right auricle moderate size, small ecchymoses beneath endocardium, tricuspid orifice measures 4 3/4 inches in circumfer. valves normal, little opaque. Right chamber small in comparison w/ left. Pulmonary semilunars normal. Pulmonary artery nothing unusual. Left ventricle large, walls unusually thick. Mitral valves opaque & dense; cordae tendinae large & strong. Mitral orifice measures 4 1/2 in. in circumference. Aortic valves are incompetent.

On slitting open the aorta the following condition is presented: — The segments are thickened especially at the edges: the right and left anterior (ant. & left posterior) have fused, forming but a single segment, the median raphe passing for a short distance up the arterial face. The right anterior sinus is small, left anterior (& left posterior) of full size. The portion of the fused segment formed by the right anterior is small; the united segment measures 1/4 in across: the single segment about 1/8 inch more. The free border of the united seg is very thick & presents two or three small, and one larger, endo=cardial outgrowths. The posterior seg. is much thickened at the border, and on the ventricular face presents an extensive flattened mass of vegetation the surface of which is coarsely granular. On the endocardium of the ventricle, just below junction of posterior and right (left) anter valves, is an elevated flattened mass about size of five cent piece. Immediately above posterior segment two large vegetations project from a depression in the wall of the

Cont on 256

Spleen enlarged, weighs 5'60 grammes.
few adhesions in capsule: on section
pulp soft, purplish red color; two
small infarctions, yellowish white in
color tolerably firm & surround c̄ zone
of hyperaemia: two small super-
numerary organs present.

Kidneys. Right, pale, not enlarged
Capsule detaches on one side without
difficulty, on other side ~~leaves~~ ~~tha~~
takes portions of substance with it.
Small yellowish white infarct. Cortex
pale. Wt. 190 gr. Left kidney little larger.
Cortex very anaemic: no infarctions
Wt. 180 grammes.

Stomach Some dark injection of smaller vessels
in places. General mucosa pale.

Liver Little soft. Otherwise normal.

Intestines. Mucous membrane of ileum is inject.
No ulceration.

Brain. Nothing special in calvaria.
Nothing in longitudinal sinus. Attached
to falx at its posterior part is a small
cystic body, pedunculated, containing a
clear fluid & some brain sand. It is
attached at junction of falx c̄ tentorium

On removal of duramater effused blood beneath arachnoid over right hemisphere, chiefly over the sphenoidal convolutions, along the fissure of Rolando. In these situations the layer is of suffic. thickness to obliterate the outlines of convolutions. On left side a slight extravasation over the 1st & 3rd frontals & over the upper pt. of ascending parietal. At base there is no extravasation. The vessels look normal. No matting, or effusion of lymph. Nothing special over the left sylvian fissure. On right side there is extravasation beneath the membrane. On stripping off the pia mater there is no lesion of vessels found to account for the extravasation. Scattered on the convolutions are some small white bodies, which in right hemisphere have the following situation. Small one about five by two millimeters, situated just at the knuckle of the inferior frontal convolution where it passes to join the orbital. On section it has a capsule closely invested on one side by brain substance. Interior contains a semi cretaceous material.

In a small sulci at uppermost part of same convolution (3rd frontal) is a second. On the second occipital there is a larger nodule, quite calcareous, the size of small bean. On left hemisphere no tubercles are noted on cortex. At posterior end of the Third temporo Sphenoidal. is a small spot, a second at the extreme anterior margin of the uncinate convolution, close to the crus. None on superficial part of cerebellum. In ventricles nothing special No softening of walls. On slicing the organ substance soft white matter looks normal. No nodules in interior Ganglias as the base look normal. Nothing in crura, pons or medulla.

Lungs. sodden. particularly in posterior part. At base of left lung there is a patch of fibroid induration at the lower & posterior part. No tubercular nodules in either lung.

Contd from p 252

aorta: these project and are in contact with above named valve. On separating the two masses it is seen that there is a saccular pouch the size of a large marble from the edges of which they spring. This pouch is thin, made up only of the middle & external coats and has lost the characteristic opaque yellow appearance of an arterial wall. The vegetations grow at the edge from the intima immediately surrounding the pouch. The intima in ascending aorta is not atheromatous except at one small spot. An inch above the valves the aorta measures 3¼ in in diameter. At junction of ascending and transverse portions and at the extreme convexity of the tube there is a round opening, the size of a twenty five cent piece, leading into a saccular aneurism the size of a small apple: the edges of this present large vegetations which spring from the intima at the border of the orifice, they project in some places a quarter of an inch. The sac is in part within the pericardium and is remarkable for the extreme thinness of the walls, which in places are quite translucent. At the back part quite close to the pericardium there is a large laceration ½ in in length. The from ths from the edges of the orifice extend into the walls of the sac, and in places have infiltrated the entire thickness of the wall, so that the peculiar yellowish colour of the vegetations shews plainly from the outside. At this point also a slight pericarditis has been excited. On the arch just below the orifice of the sac are two small warty outgrowths, which when carefully examined are seen to spring from the margins of small fissures behind which there are distinct small aneurismal pouches.

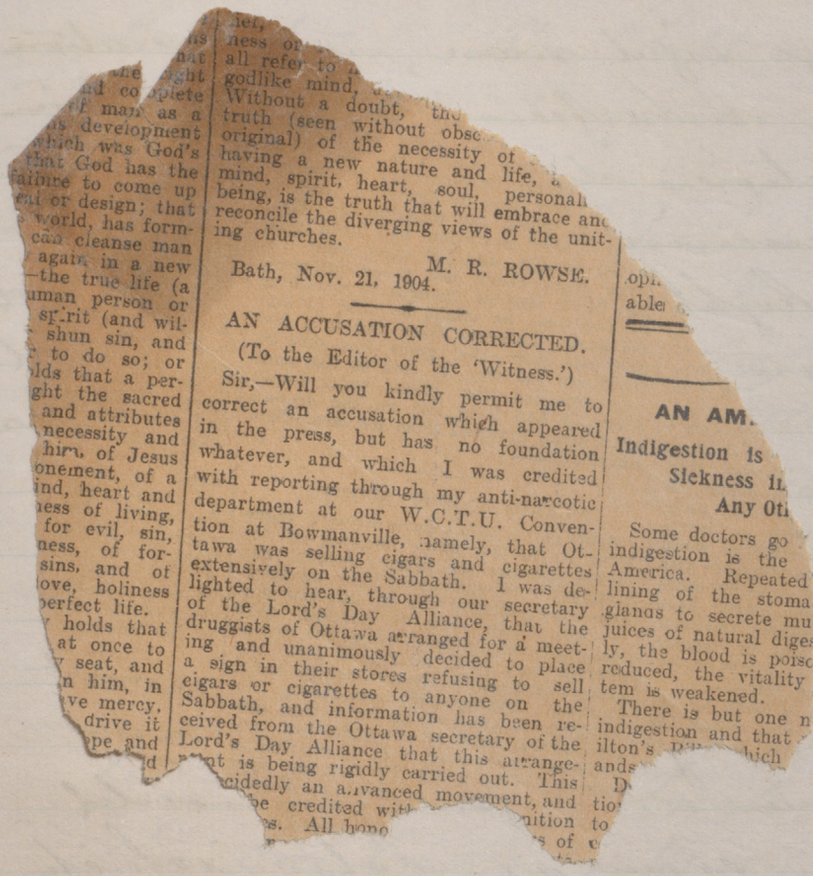

ness of
all refer to
godlike mind,
Without a doubt, the
truth (seen without obsc
original) of the necessity of
having a new nature and life,
mind, spirit, heart, soul, personal
being, is the truth that will embrace and
reconcile the diverging views of the uniting churches.

M. R. ROWSE.

Bath, Nov. 21, 1904.

AN ACCUSATION CORRECTED.

(To the Editor of the 'Witness.')

Sir,—Will you kindly permit me to correct an accusation which appeared in the press, but has no foundation whatever, and which I was credited with reporting through my anti-narcotic department at our W.C.T.U. Convention at Bowmanville, namely, that Ottawa was selling cigars and cigarettes extensively on the Sabbath. I was delighted to hear, through our secretary of the Lord's Day Alliance, that the druggists of Ottawa arranged for a meeting and unanimously decided to place a sign in their stores refusing to sell cigars or cigarettes to anyone on the Sabbath, and information has been received from the Ottawa secretary of the Lord's Day Alliance that this arrangement is being rigidly carried out. This decidedly an advanced movement, and be credited with
s. All hono
uition to
s of

Contd from p 252

the edges of which is clear at the [illegible]
aorta: these project and are in contact with above named valve. On
An irregular form is seen between
separating the two masses it ~~is seen that~~ and when separated there is a saccular pouch the
was found
size of a large marble from the edges of which they spring. This
pouch is thin, made up only of the middle + external coats and
has lost the characteristic o … appearance of an arterial wall.
The vegetations grow a … a immediately surround
=ing the pouch. … a little is not atheromatous
except at one a … spot … alves the aorta
measures … of ascending and
transve … vexity of the tube there
is a … ent piece, leading
int … small apple: the edges
of the … which spring from
the … project in some places
a q … within the pericardium
and is rema … ness of the walls, which in
places are qui … translucent. At the back part quite close to the
pericardium there is a large laceration $\frac{1}{2}$ in in length. The
growths from the edges of the orifice extend into the walls of
the sac, and in places have infiltrated the entire thickness
of the wall, so that the peculiar greenish yellowish colour of the vegetations
shews plainly from the outside, at this point also a slight
pericarditis has been excited. On the arch just below the orifice
of the sac are two small warty outgrowths, which when carefully
examined are seen to spring from the margins of small fissures
behind which there are distinct small aneurismal pouches. the
size of beans, the orifice were completely covered up of the vegetation and

---

n
d.
of
look
en con-
occasioned
e Far East,
proved that
l,' where its
peated them-
with an inten-
civilized world
correspond with
e probably much
ave never been
bearing the name
But in essence
unterpart in ev-
er waged.
f a body of six
had raised the
ns, in spite of

he
when a
nours be-
ny bade good-by
had been leaning
while using the glass, a
ered in no wise from thousands of others that covered the mountain. There was no travelled road to
w to regain the valuable binocular, particular attention had been paid to the locality, and yet when some distance from camp, the guide informed Mr. Miler that he thought by switching off the road, he might be able to find the spot. This was done and in a few minutes later the guide was sure he could see the tree. A ride to this spot was rewarded, the glass being found where it had been left on the ground after being removed from its case.—Salt Lake 'Herald.'

CLEARING FOR ACTION.

Shore-going people have rather a vague idea as to the exact meaning of the phrase 'cleared for action,' which has occupied so conspicuous a place on headlines and contents-bills in the last day or two. Many seem to imagine that decks are only cleared when war is imminent, but, as a matter of fact, the process is part of the routine of naval practice. During the manoeuvres, for instance, to clear decks for action simply means that all impedimenta, unnecessary woodwork, etc., is marked in pipe-clay with a big 'L,' meaning that on active service articles so marked
ould be … the fleet is at G
ultar … impedim
eld

in
ne
I h
I was
light in … sky
great ball of fi
the air a … lant,
ing noise as it
blinded me, and
the fiery gleam on the
have been travelling
In the glare I lost si
tine, and then I hear
and the ball of fire
ing everything black
When I got my s
not see a trace of
could hardly believe
in no direction was
in sight. A rising
waves showed whe
had gone into the
where the brigant
The light and
watch on deck. I
see if he could m
the vessel. Think
might be floating
went down, I sen
All it brought bac
ed deck planking
trace of the briga
ed her name or a

COURTESY I

'Do we lo
as
le

408

Phthisis

3/7/80.

Michael Moran age 46. Died July 2nd 1880.

Body that of average sized man, no emaciation
Nothing special on superficial examination
In abdomen intestines distended & slate
decomposition beginning. In Thorax left
lung projects to the right at upper part beyond
the border of sternum. Below the pericard
is uncovered. Both lungs firmly adherent
Heart large R. chambers distended The distension is partly due to gas (Decomposition) ——
Large firm gelatinous partly decolorized clot
in R. Auricle extending into the veins &
can be drawn out as a definite mould
R Ventricle contains similar clots which
can be withdrawn from Pulmonary artery
L. Auricle contains similar clots
On further dissection of the Heart Nothing special
in R. Auricle Tricuspid 5/8 in in circumference
R. Ventricle dilated. measuring from Pulmonary
ring to apex Tricuspid valves a
little thickened. Pulmonary Semilunar normal
one segment Jenestrated. Walls of R Vent.
increased in thickness

L- ventricle normal size. Mitral valves nothing unusual. Orifice 4½ in in Circum Aortic valves a little thickened at Corpora Arantii & specially along lower border of the dimidiated. On left-anterior & posterior segs- thickening is considerable. 2. segments are fenestrated.

Left Lung. Full volume crepitant except at extreme apex. Numerous pasty adhesions Anterior border very emphysematous & over the whole organ the air cells are very large.

The Cavity- at apex size of small apple has firm walls. distinct Pyogenic membrane in places blood stained. Not much thickened tissue about the cavity. In anterior part of upper lobe is a smaller cavity- containing pus. are no tubercles to be seen 'about the cavity- are a few small firm fibroid nodules & calcareous & cheesy ~~no~~ centres-

R. Lung— at apex extraordinarily dense adhesion. Pleura inflamed united with intercostal tissues. Mid lobe & greater part of lower lobe have no adhesions except- the latter to the diaphragm. And the lower third of lower lobe gives evidence of splenic Pneumonia & slight- exudation of lymph

Lung crepitant except upper lobe & ant. part of which is solid & very extensive Emphysema. particularly Ant. & border & Diaphragmatic portion

On section. There is a layer of thickened tissue 3/4 in in diameter over the apex the posterior 3/4 of upper lobe. The tissue of this lobe is firm airless & contains innumerable small cavities many of these are in connexion with large Bronchi & are to be regarded as Bronchi ectatic

The largest of these cavities is at poster part of apex Walls are firm & no aneurismal dilatations are seen At upper & back of lower lobe is large cavity - size of small apple & thin walls tissue about it condensed at upper part & cavity communicates w these at poster part of apex - the rest of the lung are crepitant contain air very emphysematous & contain much blood & serum are a few nodular masses scattered throughout - the substance The bronchi are large Cartilages are firm hard & elastic edges very prominent Bronchial glands swollen

Kidneys small Capsule detaches w little difficulty decomposition has advanced

surface a little roughened.
Liver average size & little nutmeg —
Stomach nothing special
Intestines —

409

Case
Michael
Body th our-
ished in
In abdo l,
some old the
caput mi-
formis wh
In thorax t
collapse nd
meet in, t
chamber of ized,
left cham male
quantity orme
Pulmona
Aorta se ached
border cal nal
substa shal
Right lun natory

5/7/80

Montreal General Hospital

PATHOLOGISTS NOTICE.

Michael Gibb 60 — died

on Monday at 5.50 p.m.

Brief History: operated on for stone May 30th — wound in perineum never closed — Patient did well until the last week since then he has failed rapidly from chills with intermittent elevation of temp — diarrhoea

Chief Symtoms:

Diagnosis: vomiting

The friends have been told to come for him at 3 p.m. tomorrow but will not wait (they say) & may give trouble. Can you do it earlier

House Surgeon.

Lung crepitant except upper lobe & ant. part of which is solid & very extensive Emphysema. particularly Ant. & border of Diaphragmatic portion

On section. There is a layer of thickened tissue 3/4 in in diameter over the apex the posterior 3/4 of upper lobe. The tissue of this lobe is firm airless & contains innumerable small cavities many of these are in connexion with large Bronchi & are to be regarded as Bronchi ectatic

The largest of these cavities is at poster part of apex Walls are firm & no aneurismal dilatations are seen at upper & back of lower lobe is large cavity - size of small apple & thin walls tissue about it condensed at upper part & cavity communicates w these at poster part of apex - the rest of the lung are crepitant contain air very emphysematous & contain much blood & serum and a few nodular masses scattered throughout - the substance The bronchi are large Cartilages are firm hard & elastic edges very prominent Bronchial glands swollen

Kidneys small Capsule detaches w little difficulty decomposition has advanced

Surface a little roughened.
Lives average size & little nutmeg—
Stomach nothing special
Intestines — —

409 Cystitis. Stone.

Case
Michael Gobb age 60 died 5/7/80
Body that of an old but fairly well nourished man
In abdomen condition of viscera normal, some old adhesions and bands about the caput caeci and tip of appendix vermiformis which is closely adherent
In thorax lungs of large volume do not collapse, borders very emphysaematous and meet in anterior mediastinum. Heart right chamber full of dark clots, partially decolorized, left chamber empty. auricle contains a small quantity of blood. Valves on right side normal Pulmonary semilunar fenestrated. Aortic segments also fenestrated, attached border calcareous, tip stiff. Mitral normal substance presents nothing unusual Right lung full in volume, emphysematous

a good deal of carbonization, chiefly in spots, organ is crepitant throughout, contains a good deal of serum, in lower lobe there are numerous small greyish white areas, soft not much larger than a split pea not situated at the periphery, look like small pyaemic spots, several of them noticed also on the upper lobe.

Left lung crepitant, contains a good deal of serum, and only a few of the spots seen in the right.

Spleen small, natural looking

Kidneys, Right small, capsule detaches easily, surface peculiarly mottled, parts opaque white, & parts deeply injected, a few cysts in the substance, otherwise presents nothing special, pelvis & infundibula dilated, mucous membrane moderately injected. Ureter on this side, large,

Left kidney contains much more blood, and is of a tolerably deep dark red colour, substance looks natural, no dilatation of the pelvis,

Rectum firmly adherent to the sacral wall, on attempting to separate it, pus escapes. The entire tissues of the posterior part of the rectum are in a condition of sloughing inflammation, and there is a good deal of pus. ~~Blood~~ & shreddy broken down tissue

Bladder is small muscular coat not hypertrophied, mucosa of a deep blackish red colour, in places almost black, immediately below the orifice of the urethra

there is a round opening, the walls of which are thickened grayish in colour, edges project into the bladder and are crusted over with phos. phatic deposit, extending from this orifice into the bladder, there is a sloughy channel leading to the external orifice, its walls are in a slough-ing condition and coated over with phosphates, external wound is not closed the same sloughy state extends to it, rectum is uninvolved. There is a great deal of induration & thickening about the tissues on either side & behind the bladder.
Stomach Post Mortem softening, near the fundus is a small patch the size of a 25 ct piece covered with a granular looking material resembling phosphates.
Liver is soft not cirrhotic,
Aorta not much atheroma, contains a large dark clot. Intestines are full of a pulpy dark faces no ulceration in large bowel and ileum

7/7/80

Case 410 Mediastinal Abscess Locally Emphysema

Franz. Bernard - æt 44 admitted June 17th died July 6th
Body emaciated Abdomen on opening nothing
special to note left lobe. Liver is firmly united
to Deaphragm below. Pericardium & in sub-
Mediastinum immediately over Pericardium
there is a superficial abcess which extends
beneath sternum under 5th & 6th 7th costal cartilages
both pleura & Pericardium are greatly thickened in this
situation - this abcess has two fistulous openings
one communicates through the 6th Intercostal
space with a subcutaneous abcess over 6th 7th
ribs two inches below nipple. 2nd communication
is through the Ensiform cartilage which communicates
with a very small abcess beneath skin in this place
Left lung the left Lung is firmly adherent to the
Diaphragm and over the lower lobe - Right lung
presents only one or two isolated adhesions
Heart small chambers and valves present
nothing unusual R Lung crepitant contains
a good deal of frothy serum L. Lung removed
with difficulty. the Deaphragm and costal
pleura being removed with it Upper lobe crepitant
Lower Lobe airless firm in a condition of collapse
on section through d. Bronchi look large and are
evidently dilated tissue reddish in color

7/7/80

Montreal General Hospital

PATHOLOGISTS NOTICE.

Margaret McDavid 44 died

on Tuesday at 10.45 A.M.

Brief History: Long standing pleurisy of right side. Admitted June 1/80 Dead emaciated anaemic with cough & pains about chest. over mid sternum an abscess left pointed which communicates with a second one under & in left hypochondrium. For last week patient had an enormous diarrhoea which carried her off.

Chief Symptoms

Diagnosis:

Chronic Pleurisy

A. D. Shire.

House Surgeon.

Friends coming from Ottawa today

7/7/80

Case 410 Mediastinal Abscess Locally Emphysema

Fran. Bernard – æt 44 admitted June 17th died July 6th
W. Body emaciated & Abdomen on opening nothing special to note left lobe. Liver is firmly united to Diaphragm below. Pericardium & in ant. Mediastinum immediately over Pericardium there is a superficial abcess which extends beneath sternum under 5th & 6th & 7th costal cartilages both pleuræ & Pericardium are greatly thickened in this situation – this abcess has two fistulous openings one communicates through the 6th Intercostal space with a subcutaneous abcess over 6th & 7th ribs two inches below nipple. 2nd communication is through the Ensiform cartilage which communicates with a very small abcess beneath skin in this place Left lung the left Lung is firmly adherent to the Diaphragm and over the lower Lobe – Right lung presents only one or two isolated adhesions Heart small chambers and valves present nothing unusual R Lung crepitant contains a good deal of frothy serum L. Lung removed with difficulty. the Diaphragm and costal pleura being removed with it Upper lobe crepitant Lower Lobe airless firm in a condition of collapse on section through d. Bronchi look large and are evidently dilated tissue reddish in color

and presents considerable increase in fibroid tissue Pleura over lower and back parts of this is thickened both layers firmly adherent to diaphragm the lung is very intimately connected and btw two thickened layer of pleura there is a localized Empyema containing a reddish pus small in extent cavity not more than ~~one~~ inch and a half in length situated towards back part of lung Ant part lower lobe firmly adherent to Diaphragm and adjoining tissues but there is no trace of Empyema in this situation the Mediastinal abscess is localized and not directly connected with the small Empyema above described the parietal layer of Pericardium is a good deal thickened over the abscess in places measuring over a quarter of an inch inner surface smooth no evidences of past pericarditis nothing special in bronchi or bronchial glands

Spleen small firmly adherent to diaphragm
Kidney normal size natural.
Liver normal size soft
Stomach presents nothing abnormal Duodenum same Uterus retroflexed leucorrhoeal discharge no Os Fibroid changes in Ovaries Small Intramural Myoma at upper and front part of Uterus about size of large marble

411

Phthisis

William Riley aet 54. July 15th 1880

Body medium sized old man.
Nothing special on inspection of abdomen.
Re thoron right-lung closely adherent. Left only at apex. (Omentum on right side is adherent to peritoneum just above inferior abdominal ring.)

Heart. Right-chambers contain loose clots fibrin not decolorized kept in incised office.
Valves orifices normal.

Lungs. Left-Crepitant. Contains several nodular masses at apex & anterior border. Upper lobe & margin of lower very emphysematous. On section a small cavity at apex containing liquified pus. The nodules when divided are seen to be caseous masses. Lower lobe is very oedematous & contains only a few nodules.

Right-Lung. A large cavity at back part of the upper lobe occupying at least 3/4 of the lobe. Extending into the anterior part are numerous small coalescing cavities. Lower lobe similarly oedematous & contains a few nodular masses. It is worthy of note the degree to which the disease has proceeded in the right apex & the slight involvement of the left. Bronchial glands nothing unusual.

Spleen Small & normal.

Kidneys average size a little firmer than usual Capsule ~~stt~~ detaches with a little difficulty. Cortex pale not mottled. Certain spots on cortex look translucent as if Amyloid infiltration had taken place, but the Iodine reaction is not at all characteristic.

Stomach contains a quantity of dirty material. On the posterior wall about the middle is a small papillomatous growth. The tissue about this is soft & injected.

Cæcum. Nothing special. Ascending colon one or two enlarged follicles. Rectum is much contracted. Coats thin. Mucosa not injected, covered with a thick tenacious mucous brownish yellow in character. Sigmoid is more injected & in it the same brownish yellow mucous. No ulceration. Peyer's patches not visible.

Liver. A little small. Thyroid at anterior border tissue soft knows fatty.

412 Phthisis

John Murray Æt 28

Body that of a tall muscular young man.
Abdomen. 10 3 of fluid. Entire peritoneum visceral & parietal covered with small tubercles. They are especially numerous on intestines & mesentery many of them have areas of pigmentation about them.
Thorax. Both lungs closely adherent. Pericardium contains a slight excess of fluid
Heart. Right chambers full of plastic clots. Incipient orifice of loop eye. Left ventricle also contains dark clots. Valves healthy. Aortic semilunar fenestrated. Muscular substance a little pale not increased in thickness.
Lungs. Left lung volume intimately united with the costal ~~pleura~~ pleura. The lung is crepitant only at lower part of lower lobe. The upper & back part at apex is also free. The antero lateral portion of upper lobe is occupied by a series of communicating cavities containing pus. Walls soft & ulcerous intervening tissue solid grey color infiltrated in places looking plastic, in others more reddish & in some having the firm dry section of a caseous pneumonia. The upper & back part of lower lobe contains numerous cavities & around many

nodular caseous spots in the intervening tissue
The base is deeply injected & also contains a few
ozs of fluid.

Right-lung also very firmly united. Is not of such
large volume as the other. Upper lobe occupied
by numerous small large communicating cavities
with walls covered with greyish necrosis which
when removed leaves a deeply injected surface
beneath. Middle lobe also contains cavities
throughout the lower lobe are numerous
nodular masses scattered through the
tissue. Bronchial Glands are greatly
enlarged. Mesenteric & omental glands contain
small tubercles.

Spleen: Small & firm.

Kidneys: Average size. Cortices a little pale &
deeper veins only injected. Tissue looks
pretty healthy.

In abdomen Rectum descends on the right
side & is closely adherent to the head of
the Caecum.

Ileum. Some of the solitary glands are
swollen. The upper part are numerous
ulcers. placed transversely about ½ - 1 in
in length. Ones containing tuberculous
matter. Peritoneal surface containing
numerous tubercles. The over

Caecum. Walls thick & dense. The greater part of the mucous membrane is wanting. only a few islands of it remaining in strips. The muscular coat is greatly thickened & much infiltrated in places to a considerable depth with the typical tubercular deposit. 4 inches up the ascending colon is a large ulcer which completely encircles the gut about 1 inch in width. Higher up is another which almost forms a circle & is still wider. A 3rd 4th & 6th is seen. The mucous membrane between these is healthy looking & contains here & there a prominent follicle.

Stomach. Mucosa is injected in spots. Otherwise it looks normal.

Loin of average size. Upper surface covered with thick fatty membrane.

Aorta & Cava normal.

Broken Back

James Hyland aet 32.

Body of an average sized man.

On back is a large bed sore size of palm of hand over the sacrum. Slight projection just over 11th dorsal where the skin has a small brownish scab upon it. On section is a small subcutaneous abscess at this point. Between 10th & 11th spines is considerable increase in width & whole vertebrae seems somewhat loosened on movement. On removal of the spinous processes & laminae the cord appears bent in this situation & also dura mater at this part looks fuller. At the point where the curvature is greatest is some shreddy injected tissue about the cord. On exposure of the cord no meningeal affection. Blood vessels pretty full. Over the sight of the curvature the arachnoid is a little turbid & very adherent to the pia mater. Just here are 3 or 4 small whitish projections beneath the pia mater. On anterior surface nothing special is observable: The consistence of the cord at the sight of curvature is slightly diminished. On section just over one of the whitish spots (above referred to) the substance is pretty soft & projects on the section over the pia mater. It is the posterior part of the cord which is most degenerated. Lower down

over

post- alone the lumbar enlargement & space where is complete disorganization of the cord being converted into a diffluent substance running out on section. Lumbar Enlargement is larger & looks fully- developed.

In left- Hypochondriac Region a superficial abscess over the Cartilages of 7th 8th 9th ribs is seen.

Abdomen. Legs bone distended. very brown colored faces.

Thorax. Lungs not adherent

Heart. Right- chambers contain decolorized clots. Valves & orifices normal.

Right- Lung. Lobe volume. only slightly crepitant. Upper lob greatly infiltrated with tumor. Low lob dark colored almost airless. & in places air cells are occupied with distinct solid granules. These spots are isolated. Grayish red in color. ~~Lung adherent~~

Left- Lung. Crepitant throughout Abdomen contains a good deal of blood at posterior part.

Spleen large. Pulp soft.

Kidneys full size. Capsule detach readily. The pyramids present a peculiar appearance the tap tubes being filled with opaque white material looking like pus. It is from however pressure on pyramids does not oozy out at mouths.

Right Kidney same condition as seen there in pelvis is a distinct purplish membranous exudation covering over the greater part of the mucous membrane which in places is very much injected almost hemorrhagic The affection of the pyramids is of the same relative extent as in left.

Bladder. Contains dirty-turbid urine. Mucosa greatly injected there & there covered with small purplish membrane. No distinct ulceration on the surface. Ureters much injected for about 3 inches from the bladder. No membrane. Upper portion natural looking.

Stomach presents patches of pretty deep injection mucous membrane bile stained.

Is a mixed thrombus an ~~beginning~~ commencement of Vena Cava which extends as a soft red clot into both iliacs. Extends as an adhering clot into external & internal iliacs.

414

Mastoid Disease
Abscess of Brain

July 21st

415

Phthisis

July 21st 1880 — 19 hrs pm.

Body considerably emaciated
Nothing special in Abdomen.

In Thorax — no adhesions on right lung: on left slight recent adhesions behind & at the side. In left pleura about 3vi tinged fluid

In chambers of Heart: clots in right side: left ventricle almost empty Valves on right side normal: tricuspid orifici dilated: over 6 in. in circumference. Left Ventricle: mitral valve normal: aortic semilunar a little opaque: on left ant. segment an isl or eight small head like vegetations. Aorta is irregular, intima roughened and there are numerous spots of Atheroma
Right Lung — Emphysema at base and back part of upper lobe: ant. portions of upper & middle lobes solid. On section, lung is infiltrated with countless small grayish white granular bodies. chiefly arranged

in groups: many of them present a small central spot (peribronchial granules) At extreme apex there is a spot of grayish infiltration. The ant. portion of lung contains numerous small chalky masses: spots of such tuberculous consolidation, and one or two small recent cavities. Lower lobe contains a good deal of blood, and numerous small tubercules

Left Lung. — ~~[illegible]~~ × Solid at upper part, & only slightly crepitant in lower lobe. Pleura covered with thin layer of recent lymph, thickest behind near the roots. On section upper lobe is solid throughout, and is intensely ædematous: quantities of clear fluid bathing the surface. The tissue is firm, airless, grayish brown in color, and through it are scattered numerous small nodules. At back part of apex at upper & ant. part of upper lobe these are few in number: but ~~[illegible]~~ they are abundant and with them there are large caseous areas.

some of which are undergoing softening
The upper part of this lobe contains
very few tubercles: tissue is firm,
intensely edematous: in places the sur-
face is smooth not granular, while in
others particularly in front the section
is distinctly granular, and looks more
like a dry gray hepatization. Lower
lobe contains much blood: and is
studded with small aggregations of
tubercle Beneath the pleura on
inner surface of this lung there numerous
miliary tubercles.
Spleen firmly united to diaphragm.
of average size: pulp soft & of a deep
purple color. Wt. 200 grams.
Kidneys of average size: capsules adherent:
substance normal
Stomach normal
Liver - large: very soft & fatty.
Aorta presents spots of atheroma:
near lumbar arteries is a small spot
of pigmentation on intima: confined
apparently to the superficial layers
Intestines nothing in large bowel.
Solitary glands of Peyer very promi-
-nent in lower part of Ileum

Patches not swollen: no ulceration.

416

Margaret McLean

Age Died July 21st at 11 P. M

P. M fourteen hours after death. Body considerably emaciated. ~~marked~~ large bed sores on sacrum.

Skull thick, tolerably symmetrical in occipital fossae particularly on right side an oval small exostosis size of thumb pointed, [illegible] cause thinning of dura mater over that Dura mater adherent. — Nothing special in sinuses. — At base arachnoid a little turbid, no lymph no special matting of the membranes Pia mater, vessels of it injected over entire brain. Large veins much distended on cortex. Nothing special in Sylvian fissures. Arteries at base contain blood. Altogether there is considerable hyperaemia of the convolut. The pacchionian granulations are well developed. Nothing special noticeable about 5th nerve.

On exposing the lateral ventricle no excess of fluid. walls are firm vessels deeply injected. Fornix and septum firm. Choroid plexuses and

velum contain much blood. Very
head middle commissure in third
ventricle. Superficial appearance of
ganglia at base normal.
On slicing the brain vessels of
white matter full. Grey matter also
hyperaemic. No localised spot of disease
in ganglia. Nothing special in
Cerebellum. Nothing in pons. On careful
slicing of the sections no spot of disease
found.

Heart. Right chamber full of pelatinous
clot. Left chambers contain small clot
valves normal.

Lungs. Left collapsed at base
upper lobe presents numerous
ecchymosis. Right lung crepitant
throughout. No tubercles

Stomach a little injection of mucous
otherwise normal

Liver Normal size. Perfectly natural
in appearance.

Spleen normal not 2 oz.

Kidneys normal size, healthy
looking

417

24/7/0

Endometritis. Diphth. Colitis

418

25/7/80

Cancer of Oesophagus

7

— Powell.

Body extremely emaciated; belly greatly sunken. Numerous ecchymoses on skin of trunk & upper extremities.
On belly liver projects slightly below the margin of ribs
Coils of intestines small but not extremely atrophied
Thorax:- Lungs not adherent, quite crepitant collapsed, heart small
nothing of note in reference to it

Oesophagus & Stomach. on removal of the parts, margin of
it lung [illegible] of oesophagus and a lacer-
took pl[illegible] noval of the lung. The left lob
of the [illegible] lobus quadratus is firmly adher
and l[illegible] cardia. oesoph[illegible]. On slitting up
oesopha[illegible] ploughing mass occupies the
lower [illegible]bo. The surface has a rough
shaggy appearance in the presence of numerous bits
of necrotic tissue. The mass extends just to the cardia
but not beyond it. The walls are not thickened
materially. and it is only at the upper part of the
mass that the true cancerous aspect is presented.
In places on the surface the membrane is quite
thin. Immediately behind the cardiac orifice there
is a large indurated mass. This mass is of the
size of egg firm schirrous in character, it extends
to the mucous surface evidently involving the
muscular coat but not extending to the mucosa

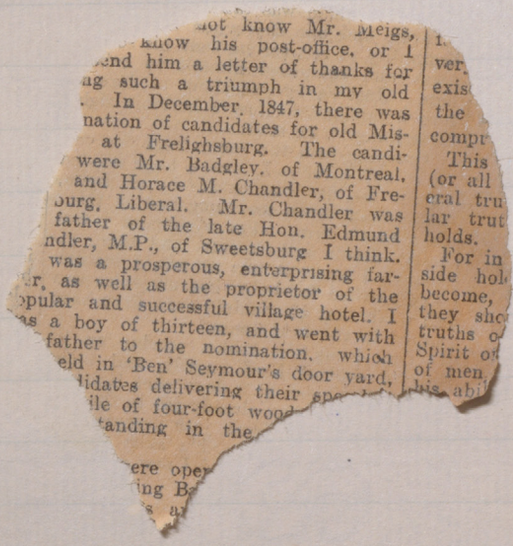

not know Mr. Meigs,
know his post-office. or I
end him a letter of thanks for
ng such a triumph in my old
. In December, 1847, there was
nation of candidates for old Mis-
at Frelighsburg. The candi-
were Mr. Badgley. of Montreal,
and Horace M. Chandler, of Fre-
burg, Liberal. Mr. Chandler was
father of the late Hon. Edmund
ndler, M.P., of Sweetsburg I think.
was a prosperous, enterprising far-
r, as well as the proprietor of the
opular and successful village hotel. I
as a boy of thirteen, and went with
father to the nomination. which
eld in 'Ben' Seymour's door yard,
lidates delivering their sp
ile of four-foot wood
tanding in the
ere oper
ing B
s a
ver
exis
the
compr
This
(or all
eral tru
lar trut
holds.
For in
side hol
become,
they sho
truths o
Spirit o
of men
his abi

418

25/7/80

Cancer of Oesophagus

7

— Powell.

Body extremely emaciated; belly greatly sunken. Numerous ecchymoses on skin of trunk & upper extremities.
On belly liver projects slightly below the margin of ribs Coils of intestines small but not extremely atrophied Thorax:- Lungs not adherent, ~~collapsed~~ quite crepitant, Heart small nothing of note in reference to it

Oesophagus & Stomach. on removal of the parts, margin of R lung adherent to side of oesophagus and a lacer: took place on the removal of the lung. The left lobe of the liver near the lobus quadratus is firmly adherent to the lower part of oesoph ~~duct~~ ~ Cardia. On slitting up oesophagus a large open sloughing mass occupies the lower 3½ inches of the tube. The surface has a rough shaggy appearance from the presence of numerous bits of necrotic tissue. The mass extends just to the cardia but not beyond it. The walls are not thickened materially. and it is only at the upper part of the mass that the true cancerous aspect is presented. In places on the surface the membrane is quite thin. Immediately behind the cardiac orifice there is a large indurated mass. This mass is of the size of egg firm schirrous in character, it extends to the mucous surface evidently involving the muscular coat but not extending to the mucosa

The mucosa over the stomach nothing remarkable
Spleen small trabeculae very marked. Kidneys
average size – nothing special to note. Liver small
yellowish-brown in color no special changes
Consider injection of mucous membrane of ileum no ulceration

One little secondary nodule in mucous membrane of stomach
There are 2 dark patches elevated on fundus of stomach black
color Superficial. On section mucosa here is thicker & different from adjacent

419

Dysenteria.

July 28 80 287

420 Abscess between Stomach & liver Cerebral Softening

Drennan

Body that of a fairly well nourished man
In Abdomen there are between 400 & 500 oz of turbid yellowish
White exudation. & covering over the upper part
of peritoneum & localized in a remarkable manner
There is an extensive fibrinous exudation covering the
organ. This extends from the upper part of Transverse
Colon. Below this the transverse Colon itself & the coils
of the small intestines are not thickly covered with Lymph
The Liver proper's band's breadth below xyphoid cartilage
and its anterior margin is covered with a thick
layer of yellowish lymph. The Stomach is thickly
coated on its exposed part. In Thorax. Adhesions
on right side — No fluid. Small amount of fluid in
pericardium. Right Chambers of heart full
Gelatinous clots — fibrin. Moderate amt of blood on left
side. On further dissection nothing special to note.
Pulmonary semilunar semestrated. On left side nothing
Special note — Valves healthy. Aortic semilunars also
semestrated Lungs — Left. Copious except at
Extreme apex. Here, on section, there are several firm
indurated areas in the centre of which are small
Cavernous spots & surrounding them an abundant
development of firm gray granulations. There is
a good deal of pigment and about them are

288 1 Caseous mass size of marble also seen

are numerous groups of gray granulation these occur in tolerable number throughout the entire upper lobe. In the lower lobe is a good deal of blood & serum & small miliary tubercles seen & there throughout the lesion Right Lung. Precisely the same condition in upper lobe. Small caseous masses and fibroid tissue with groups of tubercles scattered about and in the neighbourhood of them

Kidneys Left. Average size. Cortex pale otherwise present no abnormality. Right is small weighs. 200 grms Capsule detaches only difficulty & there is slight evidences of atrophic kidney Weight about 90 grms. Stomach. Quantity of dark brown, remains of food is found. In Duodenum Bile flows from the orifice of the common duct. Intestines

No special indication in small bowel. Peyers Patches are indistinct. Between stomach and under surface of liver there a a cavity formed the walls of which are firm & covered with a thick greenish grey lymph, evidently of old standing

Brain Bones of skull unusually dense. Nothing special in dura mater. On removal of the organ a considerable

Amount of fluid escapes. At base on superficial inspection the arachnoid is seen to be clear. Arteries contain blood. Left olfactory nerve is taken & looks smaller than the right and the olfactory is also smaller. Right optic nerve looks smaller than the left. On left side the sphenotemporal lobe looks smaller than on the right and on the inner and under surface there appears to be a cyst beneath the pia mater. There is matting about the posterior communicating artery and it contains no blood the Posterior Cerebral of left side appears to be obliterated and cannot be traced farther than the middle of the crus. Fissure on right Sylvian fissure look normal. On left side there is considerable matting of the tissues on the outer side of the Carotid and the left middle Cerebral for at least one inch on its course passes over & through tissue which looks cicatricial. The left olfactory tract is involved in the cicatricial tissue close to the Carotid. Anterior Cerebral looks natural. Dura is firmly adherent along longitudinal sinus Pacchionian granulations numerous on Falx, both sides, as four or five small irregular bony formations. Arachnoid is slightly opaque over the entire Pia mater is not adherent

Prefrontal Section presents nothing abnormal. Vessels are literally full. Peduncle frontal, nothing special

In Frontal, through ascending frontal convolutions, the anterior portions of corpora striata are shown. On the left side, the head of the caudate nucleus presents a slightly abnormal appearance

from the presence of several cysts. The anterior fibres of the internal capsule have almost disappeared in this portion (Clostrin in the left side is scarcely perceptible). Sections are then made at a distance of 1/2 inch apart & there was found to be extensive softening involving chiefly the lenticular nucleus. The internal capsule is only involved at its anterior extremity, in the middle & posterior parts it is not affected. At a level with apex of descending cornua the Thalamus appears a little smaller, the internal Capsule is not softened, but it does not present the striated appearance as seen in the other side. The lenticular nuclei, specially the outer section, is softened.

421 Tuberculosis

Jno Smith

Admitted 6th Augt. Died 20th August

Body that of a well nourished young Man. Rigor Mortis present. On Signs of ... Abdomen the Intes... mesentery are some ... like miliary tube... thy Intestines and ... Lungs sleightly ad... Heart. Right ch... Valves are normal ... special on dissect... Left Lung contain... upper lobe. Crepi... collapsed, on sec... about size of haze... around it is firm ... & grey nodules. Th... masses composed of ... around which ar... much blood & ser... Right Lung.

Stomach ... Lung are a lot of ... & look greasy & thi... Lung is Crepitant ... in upper lobe - o...

Montreal General Hospital

PATHOLOGISTS NOTICE.

John Smith died

on 20th August

Brief History: Admitted two weeks ago after a drinking bout - and in 24 hours became delirious in which condition he remained ~~Chief Symtoms:~~ ever since - Moist Rales latterly heard in base of left lung - Urine Albuminous -

Diagnosis:

Andrew Henderson M.D.

House Surgeon.

from the presence of several cysts. The anterior fibres of the internal capsule have almost disappeared in this portion (Clostrin in the left side is scarcely perceptible). Sections are then made at a distance of ½ inch apart & there was found to be extensive softening involving chiefly the lenticular nucleus. The internal capsule is only involved at its anterior extremity, in the middle & posterior parts it is not affected. At a level with apex of descending cornua the Thalamus appears a little smaller, the internal capsule is not softened, but it does not present the striated appearance as seen on the other side. The lenticular nuclei, specially the outer portion, is softened.

421 Tuberculosis

Jno Smith

Admitted 6th Augst. Died 20th August

Bodie Rather a well nourished young Man. Rigor Mortis present. No signs of decomposition.
Abdomen The Intestine look natural scattered over the mesentry are some small firm nodular bodies looking like miliary tubercle. One or two on peritoneum over the Intestines and on the Parietal layer. In Thorax the Lungs sleightly adherent behind. the
Heart Right chamber full of Blood & dark clots Valves are normal. Left Chamber contain small clots nothing special on dissection
Left Lung contains nodular masses particularly in the upper lobe. Crepitant except at extreme base which is collapsed, on section there is a small cavity at apex about size of hazel nut with purulent contents. tissue around it is firm and contains small cheesy masses & grey nodules. Brought this lobe over 1/2 Dozen scattered nodular masses composed of aggregations of coarse nodules around which are small tubercles. The Lower lobe has much blood & serum & a few aggregations of tubercles Right Lung.

Beneath the pleura over the anterior portion of this lung are a lot of tubercles. in one place five small & look greasy & the Pleura above them is turbid. This lung is Crepitant throughout. One or 2 Nodules in upper lobe - One spot has softened

Miliary tubercles are mostly sub pleural very few are through the substance of the Lungs. The Pulmonary Artery & branches first passing through the lower lobe is filled with a greyish red thrombus not very firmly adherent to the wall, extending into the smaller branches from which it can be withdrawn on section. Bronchial Glands are not enlarged

Spleen is little enlarged. pulp soft & contains a few coarse Caseous masses size of small peas

Kidneys look normal no tubercles

Stomach, nothing special. Liver of full size. Peritoneum is adherent to the surface & are small tubercles upon it

Brain.

No lymph about the base or any exudation. no signs of Tubercle either in Perforated spaces or out the Cellular tissue on Cortex of Brain Pacchionian granulations are well marked Ventricles there is a slight excess of fluid & lymph lodged, walls are firm. On careful section of Brain no foci of disease in the inferior surface of ~~Right~~ Left lobe of the Cerebellum are 2 contiguous greyish white masses firm fibro-caseous and large are present in the centre a spot of softening On slicing of white substance of Brain is firm & natural Puncta Vasculosa are well Marked

Nothing special in the Bladder.

Phthisis

422

Ellen Fitzsimmons aged 53.

Body emaciated
lobe full
& 2 small
apex. Thro
Heart is

Spleen en

Kidneys no

Liver is en
Small Intes
chiefly in

August
and lower
rents the
vaves at

does

Montreal General Hospital

PATHOLOGISTS NOTICE.

Ward 24

Ellen Fitzsimmons at 53 died

on 20th August at 8 a.m.

Brief History: Cold with Cough
ten months ago. Blood
spitting - Night-sweats
loss of flesh & general
weakness -

Chief Symtoms:
Cough - Night-sweats

Diagnosis:
Phthisis

W. Ed. Henderson M.D.
House Surgeon.

A. W. Smith acted in Henderson's place
in 1880

Miliary tubercles are mostly sub pleural very few are through the substance of the Lungs. The Pulmonary Artery & branches just passing through the lower lobe is filled with a greyish red Thrombus not very firmly adherent to the wall, extending into the smaller branches from which it can be withdrawn On section. Bronchial Glands are not enlarged

Spleen is little enlarged. pulp soft & contains a few coarse Caseous masses size of small peas

Kidneys look normal no tubercles

Stomach, nothing special. Liver of full size. Peritoneum is adherent to the surface & are small tubercles upon it

Brain.

No lymph about the base or any exudation. no signs of Tubercle either in Perforated spaces or out the Cellular tissue on Cortex of Brain Pacchionian granulations are well marked Ventricles there is a slight excess of fluid & lyttas large, walls are firm. On careful section of Brain no foci of disease In the mid surface of ~~Right~~ Left lobe of the Cerebellum are 2 contiguous greyish white masses firm fibro-caseous and large one presents in the centre a spot of softening On slicing of white substance of Brain is firm & natural Puncta Vasculosa are well Marked

Nothing special in the Bladder.

Phthisis

422

Ellen Fitzsimmons aged 53.

[redacted] 20th August

Body emaciated. Left Lung has a large cavity and lower lobe full of small tubercles. Right Lung presents one or 2 small cavities at apex & numerous nodular masses at apex. Through the lower lobe a lot of small ones
Heart is small & atrophic Heart 180 grams

Spleen small

Kidneys nothing special

Liver is small & little fibroid on the surface
Small Intestines presents numerous small tubercles ulcers chiefly in the Ileum

27/5/80

428

Name Ireland. Phthisis

Age about 30

Body that of young moderately emaciated man

Abdomen nothing special

Thorax firm adhesions in both pleura. Heart contains [illegible] clots. Valves appear normal. Lungs. Left upper [illegible] portions firm and not crepitant anterior border & base contains air. Back part of apex contains a cavity size of orange c̄ purulent contents — greater part of upper lobe c̄ the except of upper border is stuffed c̄ small closely packed tubercules very many of wh appear in connect: c̄ small bronchi. No very large caseous mass here & there are small cavities. In the upper & lateral part of lower lobe there is an [illegible] [illegible] in wh the lungs tissues are occupied by the tubercular [illegible] granulations. The bronchial glands are enlarged firm & much carbonized

Lung R. fully crepitant only at lower & posterior margin. Apex & [illegible] the entire upper lobe & back part of middle lobe riddled c̄ cavities containg sanguineous pus. Lower lobe occupied c̄ numerous aggregations of tubercles and at the upper part c̄ cavities

Kidneys Somewhat soft: average [illegible] & aspect nothing special. Spleen little enlarged [illegible] brown color: pulp good consistence. Liver [illegible] pale

[illegible]

Antrum ~~the~~ part of left lobe fully infiltrated with tubercle
Stomach nothing special Intestines few white
marked tuberculous ulcer on ileum. Mesenteric
glands enlarged. Ulceration at ileo-caecal valve

Aug 23rd Maggie Boucher
4423(A) Typhoid Fever aged 20. Canadian

Body that of small well nourished girl -
Rigor mortis present. P. M. lividity in dependent
parts. In Abdomen - Stomach distended -
lower coils of small intestine injected in
patches - injection towards ileo-caecal valve
becomes continuous. Thorax - no fluid in
pleural - afew small adhesions -
Lungs Crepitant throughout - Right only
slightly so in posterior pt - particularly upper lobe.
Heart - nothing special about valves or chambers
Chambers contained about 4 oz of blood
and clot - to - 210 grammes

Intestines - Small & part of large brown faeces in
Jejunum & ileum - towards the valve
more yellowish and pea soupy - The
Peyers patches are involved in whole
extent of this portion of gut. The upper
ones swollen unfiltrated - the lower
covered with yellowish sloughs

which here & there have begun to separate
The salivary glands are swollen - in
the lower fourth and half very much so
and in this part they are com-
mencing to slough. At lower pt of ileum
considerable infection of mucosa. ex-
tending about 1 1/2 ft from the valve
In neighborhood of the valve itself the
patches are large - one ulcer in shape
measures over 4 centimetres in
diameter (4 1/2) - the edges of these lower
patches are swollen - surfaces elevated
into ridges with corresponding de-
pressions - they are covered with yell-
owish sloughs - upon surface of these
sloughs can be seen the pitted ap-
pearance characteristic of the gland.
In one, one small patch is the
slough separated - the muscular coat
is exposed and in the centre of this
there is a greyish patch which blends
into the muscular coat to the
serous surface. this layer is infected
and there is a small grey point size
of a pins head - greyish & lustreless.
Altogether there are about 12 large patches
involved and many smaller ones

The solitary glands in the Caecum are slightly swollen - no ulcers

Rt Lung (continued) - On section the upper lobe is low and post pt dark colored - contains much bld and serum and in spots commencing hepatization - ant portion crepitant and not congested - low lobe heavy contains very little air and much blood - Bronchial mucosa intensely congested

Left lung more crepitant than right - contains much blood and serum esp post pt - bronchial tubes much engorged

Spleen 260 grammes - tissue very soft - almost diffluent deep plumb red color Kidney Capsule detach readily - contain pale ant gold - somewhat soft - otherwise natural looking - Stomach - nothing special. ~~Liver~~ Gall bladder contains somewhat milky looking fld & what the bile is mixed. Liver - average size - soft - brownish

Meningeal Haemorrhage

John Murphy aged 34 —

Body that of a large well built man. Left arm & hand much swollen, superficial abraision 2 x 2 inches in front of wrist — ~~On~~ on reflecting scalp a small bruise is seen behind left ear. No other signs of injury externally

~~The~~ Brain — Nothing special in soft parts on removal of Brain

Skull cap is thin — Dura Mater firmly adherent & brain is removed with it and Calvarium

On under surface the following is noted Blood vessels look normal — Arteries contain blood over the orbital convolutions of right frontal lobe there is slight Extravasation and the Convolutions have in spots a reddish brown Color and look softened — On the left frontal lobe orbital surface close to longitudinal fissure is a superficial Extravasation which Extends into the Convolution ~~On~~ In this lobe just behind triradiate sulcus is a spot of haemorrhagic softening the size — On right side in Sylvian fissure there is superficial Extravasation immediately below the operculum. This extravasation on the frontal lobe is situated far back & involves the 3rd part frontal convolu.

part wh. it passes over & dips in the gyrus Laterally it is bounded by the ascend limb of the fissure of Sylv. extern. & the triradiate internally. On the temporo sphenoid lobe there is an extravasation about 4 cent m in length covering the anterior portion of the 1st convol. of the lobe On corresp. pts. extravas. about the middle of 3rd sphenoidal convol. There is a superfic. haemorrhagic spot about the size of 5c piece - On removing the under surface of the left lobe of the cerebell situated at its external part there is a superfic spot of softening reddish yellow in color 25 + 15 mil. m.

On the right side there is a thin clot situated bet the dura mat. of skull on the posterolateral part of the frontal bone On the cortex convol. look natural pacchionian granul. prominent no other spots of extravasation or softening. Continued dissection of the brain by Dr Wilkins

Abdomen posn. of viscera normal. Thorax on left side adhesions very firm. There are 2 milky patches on rt ventricle in R aur fluid bld and gelatinous clot R vent large colorless clot ē fluid bld Left aur fluid bld R vent empty.

gelatinous clot in Aorta on further dissect
heart - R Vent full sign tricuspid orifice adm
heart cone very freely; valves normal. In
left Vent muscle subs of full thickness
meas from 15-20 m.m. Valves healthy
Aorta slightly atheromatous Lungs much
engorged particularly at the bases. They
are crepitant throughout. Spleen large and
weighs 260 Grams Soft. Kidneys are large
soft capsules detach readily cortices some
what swollen turbid looking weigh respectively
250 & 285 Grams.

4.25
w print

Montreal General Hospital.

MEMORANDA FOR THE PATHOLOGIST.

Case Embolism of left Middle Cerebral Artery

Name Antoine Filiatrault Age 55

Date of entry Aug 13th Date of death Aug 30th '79

(12 Midnight

Brief History

Little unknown except that he was a painter and worked up till the day of his seizure about the 1st of August. Sat down complained of dizziness & fell off his chair with rt hemiplegia & aphasia

Chief Symptoms

Complete loss of power of rt side of face & body & rt. sd. partial loss of sensation. Tongue protruded to the left. Abolition of all mental faculties & complete loss of power of speech.

Temperature range

98 - 102 - Paralyzed side ranging from 1/5 - 1° lower than the other

(Signed)

James Bell

Please see me before doing anything when you come down

J.B.

gelatinous cl
heart - R ven
heart cone
left vent
meas from
Aorta sligh
Engorged p
are crepitan
weighs 260
soft capsu
what swoll
250 + 285
P

Montreal General Hospital.

MEMORANDA FOR THE PATHOLOGIST.

Case

Name Sarah Lynch alias Ellen Manning Age 45

Date of entry Jany 8th Date of death Jany 15th 9 a.m

Brief History

Hard drinker. History of "fits" on several occasions

Chief Symptoms

Coma coming on suddenly on 6th Inst. Profound. No paralysis. Albuminous urine.

Temperature range

98 - 100.7.

(Signed) James Bell

gelatinous cl
heart - R ven
heart cone
left vent
meas from
Aorta sligh
engorged p
are crepitan
weighs 260
soft capsu
what swoll
250 + 285
p

5/7/80

Montreal General Hospital

PATHOLOGISTS NOTICE.

Donal McKenzie 34 died

on Sunday at 8 P.M.

Brief History: Gradual emaciation night sweats cough & expect- diarrhoea & polyuria -

Principal Symptoms: (had this man under your care in the Spring. & got a report of the case (diabetes insipidus)

Diagnosis: Phthisis Pulm

A. B. Smith

House Surgeon.

Explanations
Heart - R Ve
heart cone
left Vent
meas from
Aorta slig
Engorged
are explan
weigh 260
soft caps
what
250 + 285

Heart and Arteries & Veins

Case 203. Adher Pericard. Hype. Card +
122. Aneur. of Innominate (1)
125. Wound of Left Subclavian –
134 Aneurism of Aorta (Thor) (2)
135 Aortic Val. disease. (good report) +
141 Aortic Val. Disease. +
145 An of Aorta (3)
151 Aortic Val. disease. bad report +
156 Patency of For. Ovale. +
157 Aneur. of Abd. Aorta (4)
159. Aortic Val. Dis. q.v. An. Left. Med. Cerebr. +
160. Dilat. of Comm. Carotid –
168. Mitr. Card. not good. +
176 Stenosis of Pul. art. +
179 Aortic Val Disease. Favourable. +
180 Aneur of Aorta (5)
181. Embol. of Rt Med. Cerebr. + – ?
195 Thrombus of Pul. Artery
197. Embol. Sup. Mes.
215 An. of Aorta (6)
221 Mitr. Card.
222 Aneur of Aorta (7)
227 Aneur of Pul art. in cavity
229 Aneur of Aorta (8)
232. Oblit of Pul art.

gelatinous cl
heart - R ven
heart cone
left Vent
meas from
Aorta sligh
Engorged p
are crepitan
weights 260
soft capsu
what swoll
250 + 285
p

---

233. Hyper. Cord.
239. Hyper. Cord.
252 Premat. Clos of For ovale.
258 Aneur of aorta (9)
268. Obl of Inf V. cava
271 Fusif. aneur of rt vertebral.

Respiratory System

101 Phthisis (1) not calcareted
102 Pneumonia (1)
105 Phthisis (2) ? doubtful ch.
107 Pneumonia (2)
108 Phthisis (3) Tubercles –
118. Phthisis (4) no ch
130 Phthisis (5) ? doubtful
133 Phthisis (6) Tubercles
144 Œdema of Lungs
148 Pneumonia (3)
154 Empyema old.
155 Pleuro-Pneumonia (4)
160 Pneumonia (5)
165 Empyema old
166 Pneumonia (6)
167 Phthisis (7). [illegible]
171 Pneumonia (7)
173. Empyema older
175 Phthisis (8). Bad report. – pleura thick over cavity
182 Pneumonia (8)
184 Pneumonia (9)
193 Pneumonia (10)
196 Pneumonia (11)
197 Pneumonia (12)
199 Pneumonia 13
200 Pneumonia 14
213 Phthisis
217 Pneumonia 15
219 Phthisis (9) ? doubtful.
223 Phthisis (10) calcareted.
227 Phthisis (11) ?. doubtful.
241 Phthisis (12) Caseous –
242 Pneumonia (16)
247. Phthisis 13 Hard brown tubercles – no caseous ? Tub.

(14) 251 Phthisis
(15) 255 – Phthisis
(16) 256 Phthisis
(13) 259. Pneumonia
263. Œdema of the lung
266 Tuberculous [illegible]
273. Emphyse. Pleury
(17) 276 Phthisis
(18) 278 Phthisis
(19) 280 Phth fib. Bronch
(20) 284. Fib. Phthisis
(18) 285 Pneumonia.
(21) 298. Phthisis Emphy

CCLI (14) calcareted & [illegible]
CCLV (15) ?
CCLVI (16) (?) [illegible]

gelatinous Cl
heart - R Ven
heart Cone
left Vent
meas from
Aorta sligh
Engorged p
are Crepitan
weight 260
soft Capsu
what swoll
250 + 285
b

C Osseous System

129 Fract of Skull - nothing fact. - nil.
120 Fract of Skull - Scott. ~~nil~~ nil
121 Caries of Vert. - no record. nil
172. Car of Oesoph & Vertebræ. - ?
178. Fract of Skull. R. L. McD ?
187. Nec. Fem. Umbl. S.M.A. not frozen
205. Fract of Sternum. Le Phcam -
204. Fract of Ribs
227 Fract of Sternum nil

Work up records. due of Caudal in two cases.

Diseases of the Liver

147 Cirrhosis of liver
201 Echinococcus of liver
203 Cirrhosis
244 Cirrhosis
245 Cirrhosis
246 Cirrhosis with enlargement
258. Pylephlebitis
260. Cirrhosis
272 Cirrhosis
277. Cal in Bile duct. Dis of Gall bladder.
279 Perihepat. Cirrhosis
286 Cirrh of liver.

Diseases of Lymphatic & Ductless glands

(1) Cancer of axillary glands, not metastatic

2. Retroperitoneal cancer.

(3) Status lymphaticus, cause of sudden death

(4) Enlargement of Thyroid gland?

Diseases of Brain & Membranes

142 Ch Tub of Membranes

153 Ch Tub of Membranes. V

181 Embol of Rt. M. Cer. V
194 Hemorrhage int Pons. — 2
207 Apoplexy. 2

242 Meningitis (with lung)

254 Congestion of Brain ?

261 Wound of Skull & Brain V

271. Apoplexy – arm of vertebl. with atheroma

282 Parenchymatous

287. Apoplexy

290 Symptoms

295 Trauma

General Tuberculosis

150. Child – 9 m. ?
150. Tub peritonitis – with Tub of pulm

203 – chronic peritonitis with tub in brain –
206 pneum. – ?

266 no.

270 Pneumonia – 2.

285

Dipth.

132
446
447
527
528
534
574
622
637
638

Abnormalities

587. Imperfect. 8 in. long. L. Lobe. lion
583. Fissures in R. Lobe.
621. Imperfect. L. Lobe.

Liver

342 Portable Haemorrhagic infarction. Case 342

341 Cirrhosis.

363 Cirrhosis

381 Cirrhosis

383 Echinococcus

387 Cirrhosis

454 Hypertrophic Cirrhosis

488. Purulent disease of Gall bladder, dilated bile ducts. Lardaceous degeneration

519. Secondary cancer.

525 Jaundice

550 Cancer Stomach & Gall bladder

555 Echinococcus Cyst

596. Fatty liver

613. Fatty & Cirrhotic liver

618 Secondary Cancer.

640. Stenosis of Bileduct.

621. Cirrhosis

610 Cirrhosis

470 Cancer (Primary)

460 Calculi in dilated bile-ducts

435. Phlegmonous inflammation of Gall-bladder

472 Secondary cancer

556 Cirrhosis

414 Cancer of Stomach and liver

Liver. (Continued)

Canc.
457. Secondary Cancer. Cysts.

Canc. &c. others. Malformations in Chap. proper, rel. . 587. 588.

588. Fatty.

588 Fatty.

Circulatory system.

Heart

439. Rupture (of L. ventricle.)

599 Secondary Cancer of

~~Valvular disease~~

438. Mitral.

445. ~~Mitral~~ Aortic, Mitral, tricuspid.

452 Aortic

458. Aortic. Mitral

465. Tumour. Endocard. (Ant & Mitral) Chorea.

475. Ulc. Endocard. Chorea. Chor. J. Hol 9. Pneumonia

476. Ulc. Endocarditis

438. Aneurism arch of aorta. Exophyema.

478 Aneurism of arch. Perforating trachea.

479. Aortic Valvular disease.

480. Ant + Mitral. Cysts of kidney (87)

482. ~~Pneu~~ Ulc. Endocard. Pneumonia.

484 Ulc. Endocarditis

483. Mitral Stenosis

493. Aortic Stenosis

494 Aortic Aneurism. Perf of Rul artery.

496. Mitral (+ aortic) Expectation. Tumour.

~~Accumulation of Fluid~~.

497. Aortic Sel. Fusion of 2 cusps.

498. Ulcerative endocarditis

499. Ulc. Endocard. Pneumonia hemiplegia

517. Ulcerative Endocarditis

520. Aneurism of Aorta. Pneumonia 7/87.

524 Ulcerative Endocarditis 10/91.

532. Mitral Stenosis

599. Ulc. Endocarditis

Malvern

Circulatory Dept. (Con)

567 Aneurism of Arch. ~~Front~~ Rup. int. Pleura.
571. Verruc. endocard. Calcify degen of wall of L.V.
577. Aort. Scler. Endocard.
590. Pericarditis Pneumonia. Pleurisy
601. Aneurism of Thoracic Aorta.
608. Congen. Pulmonary Stenosis. abscess of Ht.
615. Oblit Sup. vena Cav. Int jugulars.
618. Perforation Int. Carotid
619 Aneurism Middle Cerebral Art
627 Aneurism of Aorta Rup. trachea
628 Double aneurism Thoracic Aorta.
629. Chr. Morb Cord. (McKay)
632. Ant Scler. Endoc. Fusion of Segment. [illegible]
621
647. Aneurism Ant. Cerebral
648 Aneurism Arch Aorta
609 Pericarditis &c.
625. Pylephlebitis.

Poisoning Cases.

Corrosive sublimate. Case 340. See papyro.
& Case 307 Surg. Hosp.

551 Ammonia poisoning

568 arsenical poisoning.

586 Morphia poisoning.

Disease of Respiratory System.

Oedema of Lung. – Ch. Mor. Brightii

Case CXLIV. – in full.

Case CCLXIII. Pallium – Morph. pois. Oedema of one lung.

Phthisis.

C I. Mil. tub. of Pharynx

CXXX. Cavities tubercles. Tubercles in Sylvian artery – central softening

CCXXIII Est. ulcer of intestine. ul. in duodenum

CCXXVII Pul. aneurism

CCXLI. Caseous – Pneu. Phthis. Rich. – Good case

CCXLVII. Old fib. tubercles.

CCLI. – Pul. aneurism

CCLXXX Fib. Phthis. Bronchiectasis ?

CCLXXXIV. Fib. Phthisis

CCXCVIII. Phthis. Empyema A+

Aet 35, single. admitted Feb 8th

Had Rheu 2 yrs ago. for past 18–20 yrs. has been troubled with a cough; & always small ach.. About 8 years ago began to spit up blood with the cough, she has also vomited blood. Short of breath began 2 yrs, & has not since past once. About seven [illegible] had an attack of right hemipl with aphasia. Voice return soon but hemipl remained some months 5 months another attack & until then the hemiplegia has remain

When admitted. Patient dull heavy — but dyspnoea. & cough. ~~Symptoms of advanced heart disea~~
hempl. ~~incomplete~~ [illegible] right side, sensation remains but is imperfect
Heart. apex beat normal — Area of dulness increased.. a blowing systolic murmur is audible at apex & is propagated to left, P. 112.
T. 101°
Urine 50% of alb..
12th Patient becoming cyanotic — death on following day

Comatose and died within two weeks from the commence of the symptoms
Autopsy. body well nourished. On remov. calv: dur

441

Case Chr. Hydrocephalus

- Redman ct. 17, deaf & dumb from infancy. History

Body that of a well grown lad. Nothing special noticeable on superficial examination. Head not very large. 22 inches in circumference. Forehead not prominent. Skull symetrical. On removing the calvaria it is found thinned in places, nowhere less than 1.5 m & that only in the temporal regions; in other localities it ranges from 3-5 m. Dura is adherent & brain had to be removed in the skull-cap. At base of side of brain looks the largest, organ has a loose, flabby aspect. The medulla & pons look flattened and the basilar artery runs in a deep groove in the latter. In front & behind the chiasma there is a translucent swelling - cyst-like, the membrane very thin. The opt. commissure is placed directly upon the centre of this & the tracts curve outwards & upwards upon its sides. The Sylvian fissures are shallow; convolutions of sphenoidal lobes look flattened. When turned out of skull-cap, organ assumes an irregular shape - the hemispheres separating a good deal. The dura is thin, otherwise natural. Convolutions of cortex somewhat flattened, sulci shallow. Corpus callosum thin, when cut into a large amount 5-8 ozs of limpid serum escaped. and the walls of the hemispheres collapsed. The lateral ventricles were then fully exposed and found to be greatly dilated, particularly the right. The ependyma is smooth translucent & numerous veins course beneath it. The ganglia are flattened but look natural. The septum lucidum is membranous, & the 4th ventricle is of large size. its lateral walls have no trace of white matter in them.

Case report written in Sir W. Osler's hand.

esented at the Osler Society meeting on Oct. 19, 1959

Dr. Alton Goldbloom

He was given this sheet by a friend of his,
o tore it from the book in M. G. H.